

## Importance of Consideration of Age and Gender during Prosthodontic Rehabilitation in the Anterior Esthetic Zone

Kalpesh Vaishnav<sup>1</sup> Dipti S Shah<sup>2</sup> Sareen Duseja<sup>3\*</sup> Rohit Baser<sup>4</sup>

<sup>1</sup>Professor, Department of Prosthodontics, Karnavati School of Dentistry, Gandhinagar, Gujarat, India.

<sup>2</sup>Professor and Head, Department of Prosthodontics, Karnavati School of Dentistry, Gandhinagar, Gujarat, India.

<sup>3</sup>Reader, Department of Prosthodontics, Karnavati School of Dentistry, Gandhinagar, Gujarat, India.

<sup>4</sup>PG Student, Department of Prosthodontics, Karnavati School of Dentistry, Gandhinagar, Gujarat, India.

### ABSTRACT

**Aim:** To investigate the effect of age and gender on the degree of maxillary and mandibular anterior teeth display while speaking and smiling in Indian population.

**Materials and Method:** A total of 120 subjects (63 females and 57 males) were included in this study. The subject was asked pronounced "ah"& "six" 3 times each sound, closing the mouth and resting between each sound. After these sounds, a smile was provoked. Each image was inserted into a separate slide of presentation software and measurements were taken.

**Results:** There was a statistically significant difference in display of maxillary and mandibular anterior teeth owing to age and gender.

**Conclusion:** Differences in tooth display in relation to aging and gender should be considered when providing esthetic treatment that involves replacement of anterior teeth.

**Keywords:** Esthetics, Mouth rehabilitation, Speech.

### INTRODUCTION

Though it has been difficult to examine and quantify precisely what represents facial attractiveness, presenting an attractive appearance with natural anterior teeth display during normal conversation and smiling has been a sought-after goal throughout history. A defective display of teeth during speaking and smile might be considered properly as a physical handicap<sup>1</sup>. The display of anterior teeth during speaking and smiling is one of the most important facial expressions and is essential in expressing friendliness, agreement and appreciation<sup>1</sup>. The development of computer graphics has enabled the



quantification of facial features with much greater facility and accuracy than was previously possible.

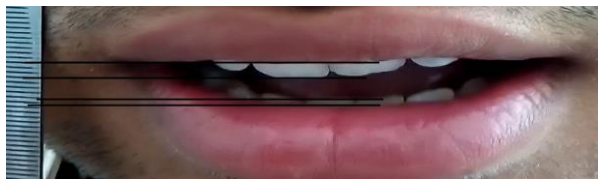The restoration of facial contours beyond compatibility with the physiologic age of the patient produces a strange appearance which calls attention to the anterior teeth. Since the lip becomes thinner with senile atrophy, it is less everted and tends to display a thinner vermilion border. Thus an attempt to create a more youthful appearance will appear inharmonious with the skin and facial structures. Often the demand for esthetics motivates the patient to seek dental treatment. However beauty is not absolute and is extremely subjective. It is dictated often by cultural or ethnic factors and individual preferences<sup>2</sup>. It is apparent

Received: Jan. 18, 2014; Accepted: May. 2, 2015

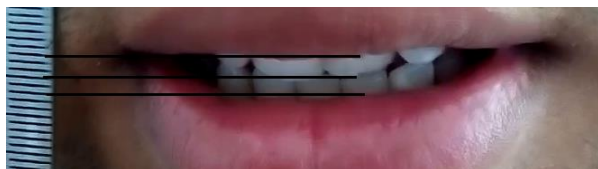\*Correspondence: Dr. Sareen Duseja

Department of Prosthodontics, Karnavati School of Dentistry, Gandhinagar, Gujarat, India.

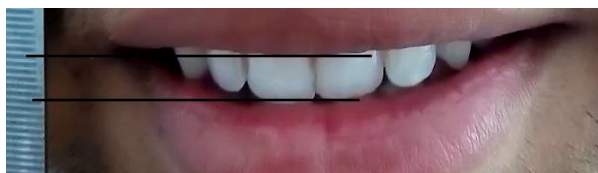E-mail: drsareenduseja@gmail.com



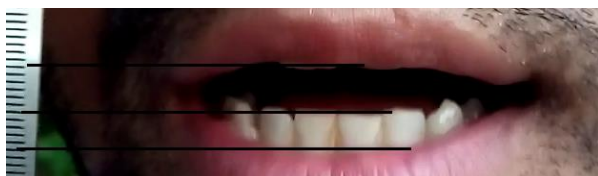
**Fig 1:** Video frame (640x480 pixels), while speaking “Ah” displaying 1 mm of mandibular anterior teeth And 3 mm maxillary anterior teeth (25 year old person).



**Fig 2:** Video frame (640x480 pixels), while speaking “six”, displaying 2 mm of mandibular anterior teeth and 3 mm maxillary anterior teeth (25 year old person).



**Fig 3:** Video frame (640x480 pixels), while “Smiling”, displaying no mandibular anterior teeth and 6 mm maxillary anterior teeth(25 year old person).

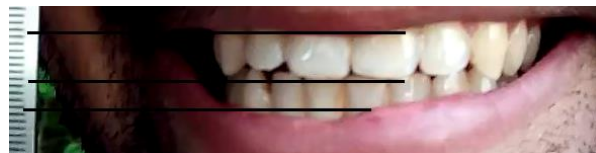

**Fig 4:** Video frame (640x480 pixels), while speaking “Ah”, displaying 5 mm of mandibular anterior teeth and no maxillary anterior teeth (65 year old person).

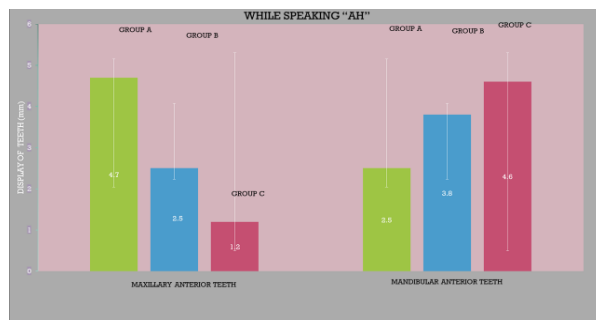


**Fig 5:** Video frame (640x480 pixels), while speaking “Six”, displaying 3 mm of mandibular anterior teeth and 1 mm maxillary anterior teeth (65 year old person).

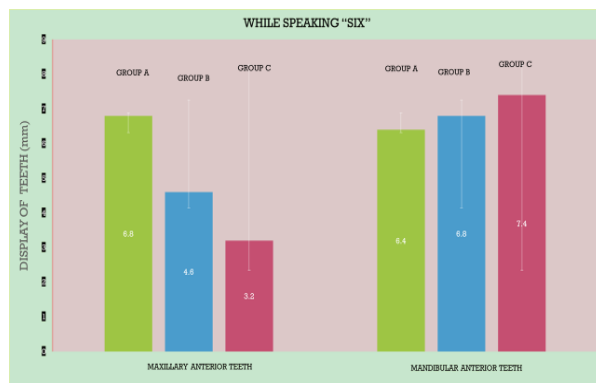
that people cannot enjoy complete social and mental well-being if their mouths are esthetically displeasing<sup>3</sup>. Since long, while performing esthetic rehabilitation of anterior teeth the same criteria is followed without considering the patient’s age and



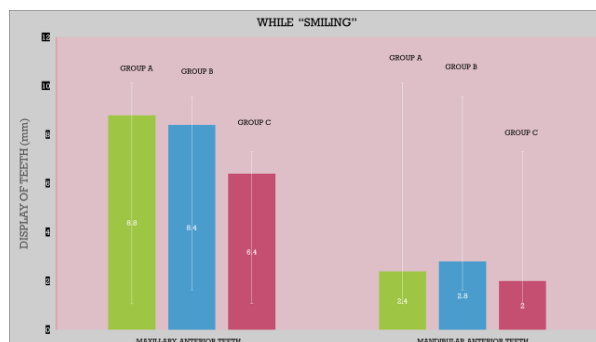
**Fig 6:** Video frame (640x480 pixels), while “Smiling”, displaying 3 mm of mandibular anterior teeth and 6 mm maxillary anterior teeth(65 year old person).



**Graph 1:** Display of maxillary and mandibular anterior teeth while speaking “Ah”.

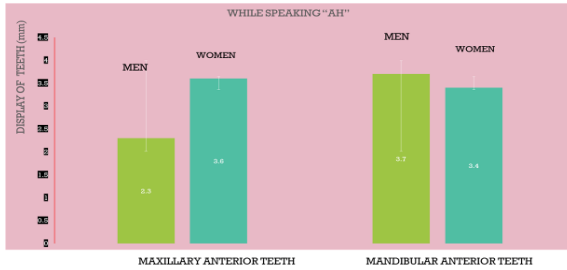


**Graph 2:** Display of maxillary and mandibular anterior teeth while speaking “Six”.

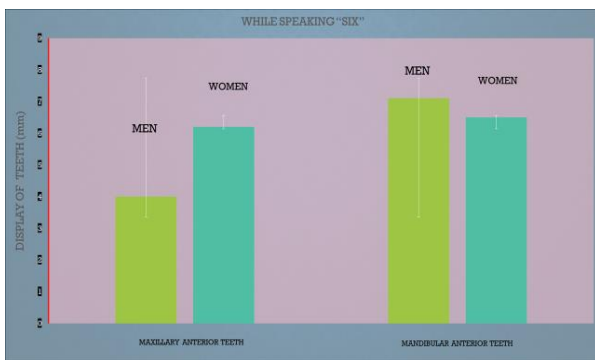

**Graph 3:** Display of maxillary and mandibular anterior teeth while “SMILING”.

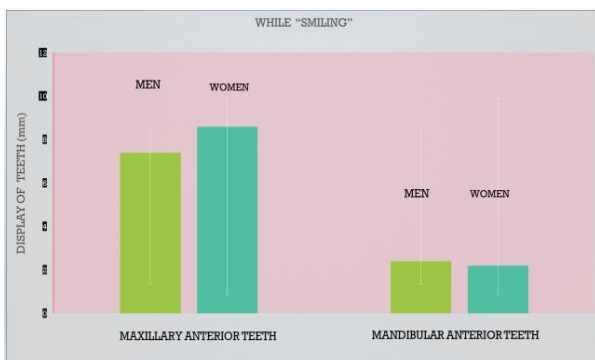
gender. Artistic sense and good judgment are excellent adjuncts to any system of esthetic rehabilitation. This study was designed to



**Graph 4:** Display of maxillary and mandibular anterior teeth while speaking "Ah" for male (n = 57) and female (n = 63).



**Graph 5:** Display of maxillary and mandibular anterior teeth while speaking "six" for male (n = 57) and female (n = 63).



**Graph 6:** Display of maxillary and mandibular anterior teeth while "smiling" for male (n = 57) and female (n = 63).

measure the display of mandibular and maxillary anterior teeth during 2 representative speech expressions and smiling as well as to evaluate correlation with age and gender in Indian population. Thus, the knowledge of age and gender in display of anterior teeth can be applied these fundamentals during esthetic rehabilitation of patients.

**MATERIALS AND METHOD**

A total of 120 subjects (63 females and 57 males) were included and divided into 3 categories.

Group A: 20 to 40 years, Group B: 40 to 60 years, and Group C: 60 years and above. The inclusion

**Table 1:** Visibility of Maxillary Teeth (Age Variations).

Age Group		While speaking "AH".	While speaking "SIX".	While "SMILING".
A (20 to 40 years)	Mean	4.7	6.8	8.8
	Standard Deviation	5.8	4.8	4.8
B (40 to 60 years)	Mean	2.5	4.6	8.4
	Standard Deviation	4.6	5.8	5.4
C(60 years and above)	Mean	1.2	3.2	6.4
	Standard Deviation	2.6	4.8	5.0

**Table 2:** Visibility of Mandibular Teeth (Age Variations).

Age Group		While speaking "AH".	While speaking "SIX".	While "SMILING".
A (20 to 40 years)	Mean	2.5	6.4	2.4
	Standard Deviation	2.8	3.6	2.8
B (40 to 60 years)	Mean	3.8	6.8	2.8
	Standard Deviation	2.8	3.8	3.0
C (60 years and above)	Mean	4.6	7.4	3.2
	Standard Deviation	3.0	4.0	3.6

**Table 3:** Visibility of Maxillary Teeth (Gender Variations).

Gender		While speaking "AH".	While speaking "SIX".	While "SMILING".
Male	Mean	2.3	4.0	4.6
	Standard Deviation	5.0	5.2	5.0
Female	Mean	3.6	6.2	5.0
	Standard Deviation	4.5	5.2	5.2

**Table 4:** Visibility of Mandibular Teeth (Age Variations).

Gender		While speaking "AH".	While speaking "SIX".	While "SMILING".
Male	Mean	3.7	7.2	2.2
	Standard Deviation	3.2	4.0	2.8
Female	Mean	3.4	6.2	2.0
	Standard Deviation	3.0	4.4	2.8

criteria was as follows: subjects of 20 years and above age, presence of all teeth and acceptable esthetic tooth display as determined by the subject

and the examiners. Subjects with dental irregularities (e.g., apparent loss of incisal tooth structure due to attrition, fracture, dental caries, restoration or any orthodontic treatment) were excluded. Video recording of subject's anterior teeth was done while holding a vertical ruler with a digital camera (NIKON DFS100 DSLR)<sup>3</sup>. Each video was recorded under incandescent light condition in order to more closely simulate conditions as seen by the average person under normal circumstances<sup>2</sup>. The subjects were asked to pronounce "ah" & "six" 3 times each sound, closing the mouth and resting between each sound. After these sounds, a smile was provoked. Each image was inserted into a separate slide of presentation software and measurements were done.

Individual pictures were captured for each expression while playing video in slow motion. For "ah" sound pictures captured showed peak display of anterior teeth and lip (Figures 1 and 4). For "six" sound pictures were captured while pronouncing vowel after the "s" sound (Figures 2 and 5). For smile, pictures were captured during peak display of anterior teeth (Figures 3 and 6). These images were then inserted into "Power Point 2013, Microsoft" and measurements of maxillary and mandibular anterior teeth were made with a virtual 10-mm ruler constructed with the presentation software drawing tools. Average measurements were calculated for each subject (Tables 1-4) and graphs were made based on these measurements (Graphs 1 to 6). Student t test was done for each pronunciation to evaluate differences for above groups.  $P < .05$  was considered statistically significant.

## RESULTS

There were statistically significant differences in display of maxillary and mandibular anterior teeth in different groups.

**Age groups:** As age increased, there was increase in display of mandibular anterior teeth in conversation and smiling. Between the age of 20 and 60 years the display of mandibular anterior teeth increased about 2.1 mm. In contrast, average display of maxillary anterior teeth decreased around 2.4 mm.  $P < .05$  was considered statistically significant.

**Gender groups:** Men had significantly greater average mandibular teeth display than women while women had significantly greater maxillary anterior teeth display while speaking and smiling.  $P < .05$  was considered statistically significant.

## DISCUSSION

The factors of sex, personality and age in anterior tooth arrangements have been discussed by Frush and Fisher<sup>4</sup>. In dentate patients the facial aging is believed to be totally due to soft tissue changes. As age increases, lips become less elastic and the tissues surrounding the mouth sag, resulting in less maxillary tooth display and the visibility of mandibular anterior teeth increases. In addition, a slight decrease can probably be attributed to incisal and occlusal wear which increases with age reducing the clinical crown length of teeth. These fundamentals should be considered while doing full mouth rehabilitation<sup>5</sup>. Hooper, as long ago as 1927, called attention to this fallacy when he admonished, "Disregard the age old rule of placing the teeth over the ridge"<sup>6</sup>.

Pound advised placing the teeth "... back in the original position from which they came"<sup>7</sup>. Artificial teeth should look like they belong to the patient's mouth. Donovan et al stated, that "complete dentures offer the clinician's ultimate freedom in providing patient's accepted esthetics." Given the variety of tooth molds, sizes, shades and arrangements available today, the clinician is limited only by his or her imagination and artistic talent. Vig and Bruno's study as well as the present study have suggested that the guidelines for the arrangement of anterior teeth should be based upon the amount of tooth exposure while speaking and smiling<sup>8</sup>. With increase with age, there is highly significant decrease in maxillary anterior teeth display. While recording jaw relation, the placement of the upper anterior teeth according to a preconceived position, rather than to the one position suitable for the patient will make everyone tend to look the same. This is contrary to nature, which gives each person an individualistic appearance<sup>5</sup>.

Heartwell and Rahn have contended that the interincisal distance increases with age and that therefore the mandibular teeth become more visible. Increased visibility can result from loss of

muscle tonus which can allow the lower lip to sag and the upper lip to drop<sup>9</sup>. According Heartwell and Rahn's judgment an attempt to make the teeth of the older patient visible to the same extent they were visible when the patient was young may result in an incorrect orientation of the occlusal plane. Now-a-days, when life expectancy of people is increased with increased health awareness, edentulism is found after 60 years and above. So a need to change the concepts of anterior rehabilitation according to individual requirement rather than following the old concepts is deemed necessary<sup>10</sup>.

### CONCLUSION

It is important that each dentist be aware of the psychologic as well as the physiologic esthetic needs of each patient. It is proposed that the conventional definition of the esthetic zone, i.e., the zone visible in a wide smile, be expanded to include observation of the patient during speech. Whether the esthetic rehabilitation of patient may be related with removable prosthesis or a fixed one, the patient's age and gender should be considered. A decrease in maxillary anterior tooth display and an increase in mandibular tooth display in older patients, especially men, should be taken into account.

### CONFLICT OF INTEREST

No potential conflict of interest relevant to this article was reported.

### REFERENCES

1. Tjan AH, Miller GD, The JG. Some esthetic factors in a smile. J Prosthet Dent. 1984;51(1):24-8.
2. Goldstein RE. Study of need for esthetics in dentistry. J Prosthet Dent. 1969;21(6):589-98.
3. Sackstein M. A digital video photographic technique for esthetic evaluation of anterior mandibular teeth. J Prosthet Dent. 2007; 97(4):246-7.
4. Frush JP, Fisher RD. Introduction to dentogenic restorations. J Prosthet Dent. 1955;5:586-595.
5. Vig RG, The Denture Look. J Prosthet Dent. 1961;11:9-15.
6. Hooper BL. Prosthodontia as a Fine Art. D Digest. 1927;33:691-774.
7. Pound E. Lost-Fine Arts in the Fallacy of the Ridges, J. Prosthet Dent. 1954;4:6-16.
8. Vig RG, Brundo GC, The kinetics of anterior tooth display. J Prosthet Dent. 1978;39(5):502-4.
9. Cade RE. The role of the mandibular anterior teeth in complete denture esthetics. J Prosthet Dent. 1979;42(4):368-70.
10. Schilder P. The Image and Appearance of the Human Body, Psyche Monographs No.4, London, 1935.

### How to cite this article:

Vaishnav K, Shah DS, Duseja S, Baser R. Importance of Consideration of Age and Gender during Prosthodontic Rehabilitation in the Anterior Esthetic Zone. Adv Hum Biol. 2015;5(2):39-43.