



## An Anatomical Study of The Human Cisterna Chyli And Its Clinical Importance

Srinivasarao. Yalukurthi<sup>1</sup>, Thirupathirao. Vishnumukkala<sup>2</sup>, Chandana Chaitnaya Siri<sup>3</sup>, Bharath.CH.N.V<sup>2</sup>, S. Swayam Jothi Dorai Raj<sup>4</sup>, Babuji.puttagunta<sup>5</sup>, M Kannan<sup>2</sup>

<sup>1</sup> Assistant professor, Department of Anatomy, K.I.M.S&R.F, Andhra Pradesh, Inida.

<sup>2</sup> Department of Anatomy, A.S.R.A.M.S, Eluru, Andhra Pradesh, India.

<sup>3</sup> Lecturer, Department of Physiology, K.I.M.S&R.F, Amalapurum, Andhra Pradesh, India.

<sup>4</sup> Professor and Head, Department of Anatomy, Sri Sathya Sai Medical College, Chennai. India.

<sup>5</sup> Professor and Head, Department of Anatomy, Narayana Medical College, Nellore, India.

### Abstract

The cisterna chyli is the abdominal origin of the thoracic duct, and it receives the bilateral lumbar lymphatic trunks. Anatomically and surgically the cisterna chyli is an important structure but very fewer studies reported in literature, so that we undertake this study. In this study we observed the presence, position with respect to the vertebral bodies and the main lymphatic tributaries forming the cisterna chyli in 45 cadavers from 3 different medical colleges in costal Andhra, of these 15 were female and 13 were male cadavers. We found Cisterna chyli was present in 6(40%) out of 15 female bodies, and 14 (46.6%) out of 30 male bodies. To sum up cisterna chyli was present in 20 (44.4%) out of 45 cadavers dissected (44.4%). The position of the cisterna chyli was at L1-T12vertebrae in 10 adult cadavers. The position of the cisterna chyli was at T12-T11 vertebrae in 6 adult cadavers. The position of the cisterna chyli was at L2-L1 vertebrae in 4 adult cadavers, the main lymphatic tributaries forming the cisterna chyli based on M.Loukas Types In 9 cadavers (20%) the thoracic duct arose from the confluence of the lumbar and intestinal trunk (Type I) . In 27 cadavers (60%) it was formed by the confluence of two ascending lumbar lymph trunks and intestinal trunk joined the thoracic duct (Type II). In 9 cadavers (20%) the thoracic duct ascended from a plexus formed by the lumbar and intestinal trunks (Type III). The reports documented in this study were different compare to the literature. The variations in the presence, positions and the main lymphatic tributaries forming the cisterna chyli are important for anatomists, surgeons and radiologists during their diagnosis and surgeries related to the cisterna chyli.

**Key words:** Anatomists, Cisterna chyli, Position, Presence, Thoracic duct,

\*Corresponding Author: Mr. Y. Srinivasa rao, Assistant professor, Department of anatomy, Konaseema Institute of Medical Sciences and Research Foundation, Amalapurum, East Godavari district, Andhra Pradesh, India. Email: [srinivasyalukurthy@gmail.com](mailto:srinivasyalukurthy@gmail.com)

Received: January 29, 2013 Accepted: February 18, 2013. Published: May 20, 2013. This is an open-access article distributed under the terms of the Creative Commons Attribution License, which permits unrestricted use, distribution, and reproduction in any medium, provided the original author and source are credited.

### Introduction

The lymphatic system is an integral part of the cardiovascular system. It consists of two main lymphatic trunks- Thoracic duct and right lymphatic duct, numerous lymphatic vessels and organs of the lymphoid system. Lumbar trunks are formed by the lymphatic vessels of the lower limbs, pelvis and its organs. The lymph of the abdominal organs converges into one or several intestinal lymphatic trunks. Lumbar, intestinal trunks and the lower intercostal lymphatic vessels unite and form cisterna chyli, with which the biggest lymphatic trunk (Thoracic duct) starts. Cisterna chyli is an elongated,

at times dilated lymphatic sac 3-5 cm long. It is located to the right of the aorta, behind the right diaphragmatic crus along the anterior surface of L1-2 or Th 12 vertebrae [1].

The lymphatic system begins development latter than the CVS and does not appear until the fifth week of gestation. Lymphatic spaces commence as clefts in the mesenchyme, and their lining cells take on the characteristics of endothelium. These spaces form capillary plexus from which certain lymph sacs, to be noted latter, are derived. In human embryo the lymph sacs from which the lymph vessels are derived or six in number: two paired (the jugular and posterior lymph sacs) and two unpaired (retroperitoneal and cistern chyli) [2].

The lymphatic system is involved in various pathological conditions, including neoplastic diseases that can result in disturbances of lymphatic flow. Furthermore, laceration of the thoracic duct sometimes occurs after surgery (for example, oesophagectomy, pneumonectomy and spine surgery), and these result in incurable chylothorax. Therefore, it is necessary to recognise its precise localization before surgery [3].

This work was carried out to provide a detailed description of the presence, positions based on vertebral bodies and the main lymphatic tributaries forming the cisterna chyli according to M.Loukus types in the cadavers, [1] the following information is very useful to the surgeons during surgeries related to the cisterna chyli and abdominal surgeries. Also this information useful for radiologists during their diagnosis of the abdominal surgeries.

**Materials and Methods**

A total number of 45 cadavers were studied, of these 15 were female and 13 were male cadavers. The material consisted of adult cadavers between the ages of 42-81 from the dissection halls of Departments of Anatomy of ASRAM, Eluru, A.P. and Department of Anatomy of PIMS, Ganavaram, A.P. and Department of Anatomy of KIMS&RF, Amalapuram, and A.P. The study was carried in the dissection halls of the above colleges.

During routine dissection of the abdomen region part of the work was done in the particular region whenever the dissection was in progress. The observations were neatly taken by 8.1 Mega pixel of Nikon camera. The findings observed regarding

Cisterna chyli was documented in a schematic manner.

**Results**

In the present study presence or absence of cisterna chyli was observed in adult cadavers both male and female.

Cisterna chyli was present in 6(40%) out of 15 female bodies, and 14 (46.6%) out of 30 male bodies. To sum up cisterna chyli was present in 20 (44.4%) out 45 cadavers dissected (44.4%). The position of the cisterna chyli was varying. The position of the cisterna chyli was at L<sub>1</sub>-T<sub>12</sub>vertebrae in 10 adult cadavers (Fig. 1). The position of the cisterna chyli was at T<sub>12</sub>-T<sub>11</sub> vertebrae in 6 adult cadavers (Fig. 2). The position of the cisterna chyli was at L<sub>2</sub>-L<sub>1</sub> vertebrae in 4 adult cadavers (Fig 3). (Table No. I).

S.No.	Position of cisterna chyli	Seen in No. of cadavers
1	At L <sub>1</sub> -T <sub>12</sub> Vertebrae	10 cadavers
2	At T <sub>12</sub> -T <sub>11</sub> Vertebrae	6 cadavers
3	At L <sub>2</sub> -L <sub>1</sub> Vertebrae	4 cadavers

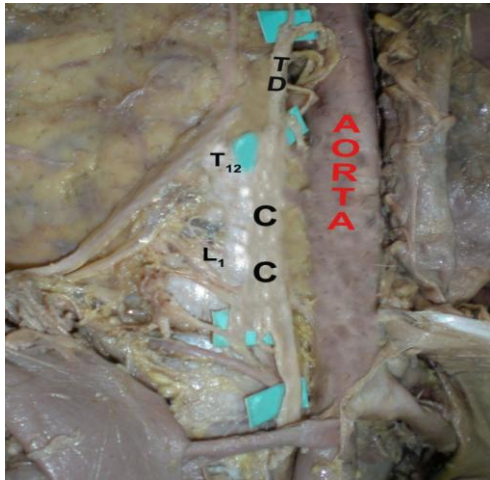
**Table - 1**

The main lymphatic tributaries forming the cisterna chyli (Types of cisterna chyli):

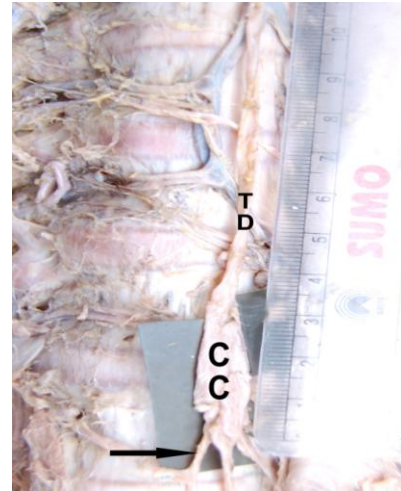
In 9 cadavers (20%) the thoracic duct arose from the confluence of the lumbar and intestinal trunk (Type I) (Fig 4). In 27 cadavers (60%) it was formed by the confluence of two ascending lumbar lymph trunks and intestinal trunk joined the thoracic duct (Type II) (Fig. 5). In 9 cadavers (20%) the thoracic duct ascended from a plexus formed by the lumbar and intestinal trunks (Type III) (Fig. 6). (Table No. II).

S. No.	Beginning of the thoracic duct	Seen in No. of cadavers	Percentage incidence
1	Type. I	9	20%
2	Type. II	27	60%
3	Type. III	9	20%

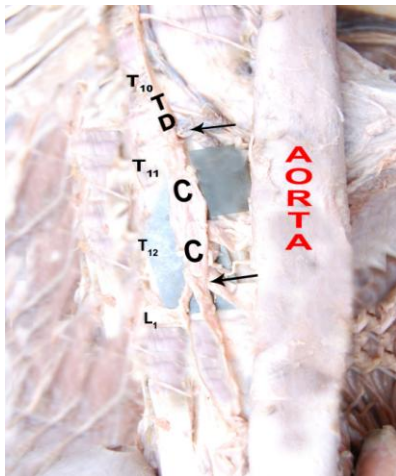
**Table - 2**



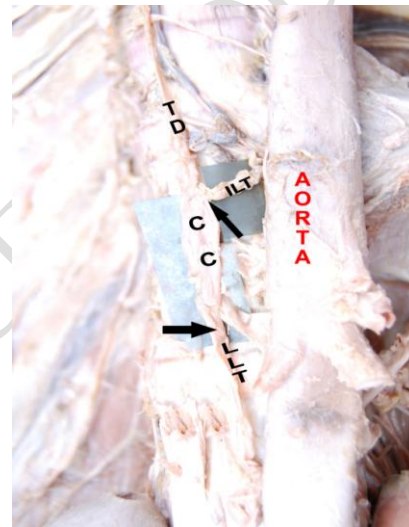
**Fig. 1:** The position of the cisterna chyli at T11-T12 vertebrae. TD- thoracic duct, CC-cisterna chyli, T- thoracic vertebrae, L-lumbar vertebra




**Fig. 4:** Beginning of the thoracic duct-type-I. CC- cisterna chyli, VC- vertebral column, TD- thoracic duct



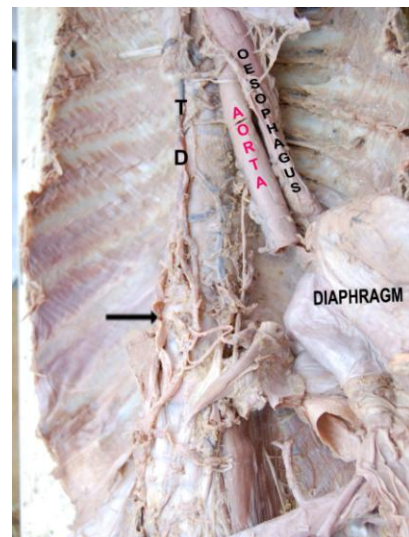
**Fig. 2** The position of cisterna chyli at T12-T11 vertebrae. TD-thoracic duct. CC-cisterna chyli, T- thoracic vertebrae, L-lumbar vertebrae



**Fig.5:** Beginning of the thoracic duct-type-II. TD-thoracic duct, CC-cisterna chyli, ILT-intestinal lymph trunk, LLT-lumbar lymph trunk



**Fig3:** The position of the cisterna chyli at T12-T11 vertebrae. TD-thoracic duct, CC-cisretna chyli, L-lumbar vertebrae, IVC- inter vertebral disc



**Fig.6:** Beginning of the thoracic duct-type-III TD- thoracic duct



**Discussion**

Cisterna chyli was formed by the union of two lumbar lymph trunks, and the intestinal lymph trunk with in the abdomen. Thoracic duct starts from its upper part. But cisterna chyli may be absent in subjects. So the generalized name, “Abdominal confluence of lymph trunks is used.” whenever the abdominal confluence is in the form of elongated saccular structure, the specific name cisterna chyli should be reserved.

In 1945, Davis had observed the cisterna chyli in only 50% percent of his observations [4]. In the presence study it was present in 44.4%.

In 1978, Kubik had made observations about cisterna chyli in 70 dissections [5]. According to him cisterna chyli was absent in 80% and in our present study it was absent in 55.5%.

In adults the cisterna chyli was present in 6 out of 15 female bodies (40%) dissected, and was present in 14 out of 30 male bodies (46.6%) dissected. The available data suggests that there are equal chances of presence or absence of cisterna chyli in both sexes.

In 1996, Gollub. and Castellino studied about the cisterna chyli as a potential mimic of the retrocrural lymphadenopathy in CT scans of 18 patients. Because in the CT scan it appears as a retrocrural tubular structure. [6] The results of their study show that cisterna chyli was variably located as detailed in the Table no.III

S.No.	Position of cisterna chyli	Gollub. M. J. & Castellino R. A. observations	Present observations
1	At L <sub>1</sub> -T <sub>12</sub> vertebrae	In 11 cases	In 10 specimens
2	At T <sub>12</sub> -T <sub>11</sub> vertebrae	In 5 cases	In 6 specimens
3	At T <sub>12</sub> vertebra	In 2 cases	–
4	At L <sub>2</sub> -L <sub>1</sub> vertebrae	–	In 4 specimens

**Table - 3**

Cisterna chyli when present was behind the right crus of the diaphragm. The position was variable. At the level of L<sub>2</sub>-L<sub>1</sub> as per many text books. In the present work it was observed in 4 specimens. At at the level of L<sub>1</sub>-T<sub>12</sub> vertebrae seen in 10 specimens. At level of T<sub>12</sub>-T<sub>11</sub> vertebrae seen in 6 specimens. These positions are closely related to the observations of the Gollub and Castellino (1996).

In 1972, Jacobsson presented a very useful summary of the cisterna chyli and thoracic duct thoracic duct. An anatomical study was made on the thoracic duct in 100 autopsy cases. A thoracic duct was found in every case and always started below the diaphragm, passed through the posterior mediastinum in the thorax and discharged into the confluence if the veins in the left of the neck. In 4% of the cases a branch left the thoracic part of the thoracic duct at aortic arch emptied into the veins in the right side of the neck.

In the present study beginning of the thoracic duct conformed to the three types of Jacobson’s (1972). In 20% Type I the thoracic duct arose from the confluence of the lumbar and intestinal trunks and in Type II 60% it was formed by the two lumbar lymph trunks and intestinal trunk had joined the thoracic duct. In Type III 20% the thoracic duct ascended from the plexuses formed by the lumbar and intestinal trunks. These percentages are similar to the Jacobson’s (1972) observations. [7] But in the present study Type IV was not found. (Table no. IV)

S.No.	Type of observation	Jacobsson (1972) observations	Present observations
1	Type I	20%	20%
2	Type II	55%	60%
3	Type III	24%	20%
4	Type IV	1%	–

**Table - 4**

**Conclusion**

The thoracic duct is commencing as a dilated sac, the cisterna chyli. A definite cisterna chyli is present in 44.4% of the subjects. Irrespective of presence or absence of the cisterna chyli the commencement of the thoracic duct is by the union of right and left lumbar trunks, the intestinal lymph trunks joining anteriorly. The intestinal lymph trunk usually joins the lumbar lymph trunk in 70-80% of subject. The various positions of the cisterna chyli were at L<sub>1</sub>-T<sub>12</sub> vertebrae in 10 specimens, at the level of T<sub>12</sub>- T<sub>11</sub> vertebrae in 6 specimens, and at the level of L<sub>2</sub>-L<sub>1</sub>, as per many text books. The beginning of thoracic duct confirmed to the three Type –I 20%, Type - II 60% and Type – III 20%. In present study Type-IV is absent. This information is needful for the anatomist,

surgeons and radiologists during their studies diagnosis and surgeries related to the cisterna chyli.

## Acknowledgement

The author would like to thank Dr. S. Swayam Jothi Dorai Raj, Dr. P.Bapuji for their valuable suggestions guidance and constant encouragement throughout the course, and screening this work. The author would also like to thank Mr. M. Kannan, for his constant involvement during dissection for his valuable suggestions during this work.

## References

1. Desislava M. Paleva, Petia K. Muchatova, Polina G. Marinova. Anatomical investigation of the cisterna chyli and X-ray and CT-Visualization in the retrocrural space. *J. Biomed Clin Res*. 2009; 2(1) suppl.1: 90-93.
2. Williams PL, editor. *Gray's anatomy*. 38th edn. New York, NY: Churchill Livingstone; 1995.
3. Liu ME, Branstetter BF 4th, Whetstone J, Escott EJ. Normal CT appearance of the distal thoracic duct. *AJR* 2006; 187: 1615–20.
4. Davis, H.K.: Statistical study of thoracic duct in man-*American Journal of Anatomy* 17, 1915, 211-244.
5. Kubik St.: The variations in position and form of the thoracic part of the thoracic duct. Its Skeletal relations *Rofo-fortschr-Geb. Rontgenstr-Nuklearmed-1975-jan.122* (1) Page 1-5.
6. Gollub, M.J. and Castellino, R.A.: Cisterna chyli as a potential mimic of Retrocrural Lymphadenopathy on CT scan-*Radiology* 1996; May 199(2) pages 477-80.
7. Jacobsson S.I.: *Clinical Anatomy and Pathology of the thoracic duct. An investigation of 122 Cases stocpholm*; Almquist and Wiksell, 1972.
8. Hematti H – *Anatomy of the Thoracic duct. Thorac Surg Clin* - 01-MAY-2011; 21(2): 229-38.
9. Kaur D, Jain M, Dhall U, Singh K. An unusual course of the thoracic duct in relation to the vertebral vessels. *Singapore Med J*. 2012 Jan; 53(1):e1-2.
10. Omer Akcali, Amac Kiray, Ipek Ergur, Suleyman Tetik, Emin Alici. Thoracic duct variations may complicate the anterior spine procedures. *European Spine Journal* September 2006, Volume 15, Issue 9, pp 1347-1351.

11. Marios Loukas, Christopher T. Wartmann, Robert G. Louis Jr., R. Shane Tubbs, E. George Salter, Ankmalika A. Gupta, Brian Curry. Cisterna chyli: A detailed anatomic investigation. *Clinical Anatomy* Volume 20, Issue 6, pages 683–688, August 2007.
12. M kiyonaga, H mori, S matsumoto, Y yamada, M sai, and F okada. Thoracic duct and Cisterna chyli: evaluation with multi detector row CT. *The British Journal of Radiology*. January 17, 2012, pages 1-7.