



Delayed spontaneous extradural hematoma following bilateral decompressive craniectomy

Dr Bhavanam Hanuma Srinivas¹, Dr Alugolu Rajesh*², Dr Suchanda Bhattacharjee³

^{1,2,3} Senior Resident, Assistant Professor, Associate Professor, Department of Neurosurgery, Nizam's Institute of Medical Sciences, Punjagutta, Hyderabad, India.

Abstract

Development of symptomatic extradural hematomas, in the absence of bone flap is quite uncommon. We herein report a case of spontaneous extradural haematoma following bilateral decompressive craniectomy for severe head injury with left frontal contusion and right frontal acute SDH. Traumatic brain injury (especially following parenchymal loss) is a dynamic process, with continual changes occurring till the normalisation of the internal milieu of the cranium, which should be planned earliest after normalisation of intracranial pressure.

Key words: Extradural hematoma, decompressive craniectomy, traumatic brain injury

*Corresponding Author: Dr Alugolu Rajesh, M. S., M.Ch, Assistant Professor, Department of Neurosurgery, Nizam's Institute of Medical Sciences, Punjagutta, Hyderabad, India. E.mail: drarajesh1306@gmail.com

Received: July 26, 2013. Accepted: August 31, 2013. Published: September 20, 2013. This is an open-access article distributed under the terms of the Creative Commons Attribution License, which permits unrestricted use, distribution, and reproduction in any medium, provided the original author and source are credited.

Introduction

The dynamic changes occurring in the brain are not just limited to the acute phase but do run into the postoperative period till the internal milieu of the intracranial compartment is normalized. Enlargement of small extradural hematomas, fracture hematomas and de novo development of hematomas on the contralateral side in the immediate post operative period have been well described in the literature with the reported incidence of 5.7%.^[6, 9, 11, 12, 13,14] However, development of symptomatic extradural hematomas, in a delayed fashion without and fresh antecedent injury/insult has not been well reported. We herein present a rare occurrence of a symptomatic

extradural hematoma occurring as a complication to bilateral decompressive craniotomy, after a month following first surgery.

Case presentation

A 55yr old male non-diabetic, non hypertensive suffered from head injury following road traffic accident and was admitted with a GCS-E3M5V3 (11/15). No injuries to other organ systems were noted. CT scan of head showed left frontal contusion and right frontal-temporo-parietal acute SDH with diffuse cerebral edema and obliteration of the basal cisterns (Figure 1 a-d). Bilateral decompressive craniectomy with left frontal contusion evacuation and preservation of bone flap in the abdominal parities was performed as an emergency procedure. The patient improved in sensorium and was discharged on the 10th postoperative with a GCS of 15/15 and advice for bone flap replacement after 3 months. The CT scan brain plain showed the post craniectomy status, with bilateral subgaleal collections, gliotic changes in the left frontal lobe with mild dilatation of the ventricles and bilateral subdural hygromas (Figure 2). After a month of uneventful period, the patient presented to emergency department with GCS of E3M5V2 (11/15) and dilated pupil on left side. CT scan showed acute extradural haematoma of size

9.8X3.5X6.9cm in left frontal region with mass effect in the presence of bony defect (Figure 3). He was subjected to surgical evacuation of hematoma following analysis of bleeding parameters (platelet count 1.6 lakhs/mm³ PT-13.8 sec; control-13.0secs, aPTT- 30.40 sec; control-30.0secs, fibrinogen-288 mg/dl). Intraoperatively, after elevation of the scalp flap, 50cc of blood clot was noted over the intact dura. The source of active bleeding was noted to be extradurally from the medial margin of the

craniotomy defect, towards the sagittal sinus. Following evacuation, durotomy and eversion of dura over the medial margin of craniotomy flap performed for haemostasis. There was no subdural clot. Lax duroplasty was performed using temporalis fascia. The patient improved in sensorium and was evaluated for bleeding tendencies, and no definitive causative factor was found. We reviewed the history for any minimal trauma to the unprotected brain and the same was negative.

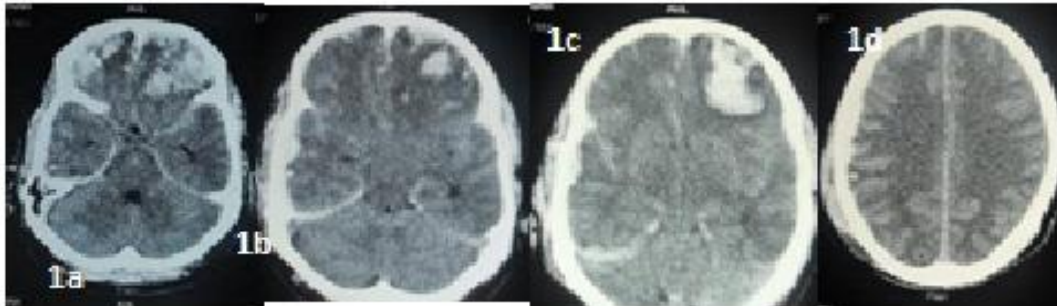


Figure 1 (a, b, c)- Axial CT scan of brain showing left frontal contusion, diffuse cerebral edema with obliterated ventricles and basal cisterns and right fronto-temporo-parietal subdural hematoma.

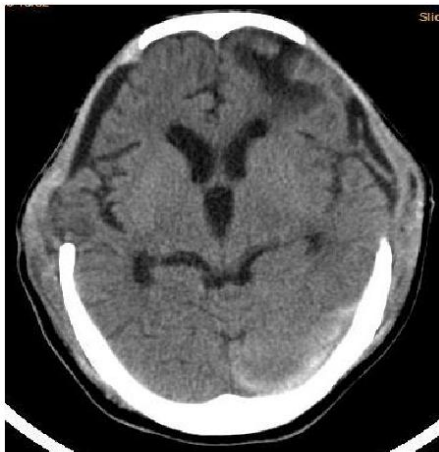

Figure 2- Axial CT scan of brain with bilateral calvarial defects at the time of discharge from the hospital. Noted on the left frontal region is the loss of parenchyma and bilateral subdural hygromas and mild dilatation of ventricular system.

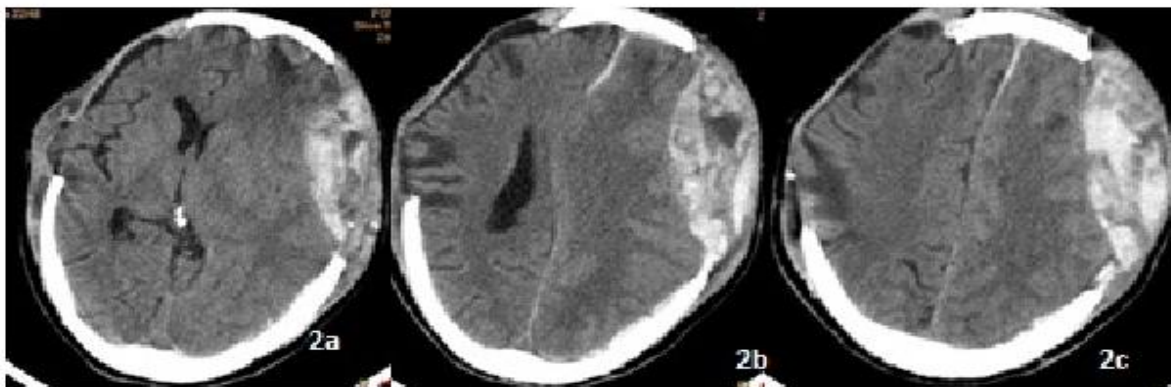


Figure 3 (a, b, c)- Axial CT scan of brain with left frontal extradural hematoma with mass effect, midline shift with bilateral calvarial defects.

Discussion

Intraoperative or immediate postoperative development of EDH contralateral to a decompressive craniotomy, with majority of them being enlargement of pre-existing small hematoma or having a fracture, is a well known entity with an incidence varying from 0-5.7%.^[1, 5, 7, 10, 11] Various pathophysiological mechanisms described for the occurrence of contralateral hematoma are-

1. Sudden relief of tamponade effect.^[3]
2. Failure of cerebral blood flow regulation which is secondary to injury.^[8]
3. Vaso motor mechanisms, including vasoparalysis and vasospasm interfering with the integrity of blood vessel walls resulting in intracranial haematomas.^[2]
4. Coagulopathies.^[4]
5. Dysregulation of the equilibrium due to raised ICP.^[5]

In our case the exact cause of delayed EDH could be attributed to dysequilibrium in pressure across the scalp flap, only on one side (side of contusion and subsequent parenchymal loss) leading to gradual stripping of the dura from the bone and snapping of extradural bridging veins. However, the exact cause of the precipitating event could not be identified. The exact incidence of such occurrence of extradural hematomas following decompressive craniotomies is not well documented in the literature. It is also surprising to find a symptomatic extradural hematoma in the absence of a bone flap. However this can be explained by its large size.

Conclusion

Symptomatic EDH can also occur after decompressive craniotomy, which should be thought of a possibility in the event of new onset swelling in a sunken flap. Traumatic brain injury (especially following parenchymal loss) is a dynamic process, with continual changes occurring till the normalisation of the internal milieu of the cranium, which should be planned earliest after normalisation of intracranial pressure.

References

1. Boviatsis EJ, Korfiatis S, Kouyialis AT, Sakas DE. Epidural haematoma after evacuation of contralateral subdural haematoma. *Ir J Med Sci* 2004;173:217-8.
2. Evans JP, Scheinker IM. Histologic studies of the brain following head trauma; post-traumatic petechial and massive intracerebral hemorrhage. *J Neurosurg* 1946;3:101-13.
3. Hirsh LF. Delayed traumatic intracerebral hematomas after surgical decompression. *Neurosurgery* 1979;5:653-5.
4. Kaufman HH, Moake JL, Olson JD, Miner ME, duCret RP, Pruessner JL, Gildenberg PL. Delayed and recurrent intracranial hematomas related to disseminated intravascular clotting and fibrinolysis in head injury. *Neurosurgery* 1980;7:445-9.
5. Lesoin F, Viaud C, Pruvo J, Redford H, Jomin M. Traumatic and alternating delayed intracranial hematomas. *Neuroradiology* 1984;26:515-6.
6. Lipper MH, Kishore PR, Girevendulis AK, Miller JD, Becker DP. Delayed intracranial hematoma in patients with severe head injury. *Radiology* 1979;133:645-9.
7. Matsuno A, Katayama H, Wada H, Morikawa K, Tanaka K, Tanaka H, Murakami M, Fuke N, Nagashima T. Significance of consecutive bilateral surgeries for patients with acute subdural hematoma who develop contralateral acute epi- or subdural hematoma. *Surg Neurol* 2003 ;60:23-30.
8. Meguro K, Kobayashi E, Maki Y. Acute brain swelling during evacuation of subdural hematoma caused by delayed contralateral extradural hematoma: report of two cases. *Neurosurgery* 1987;20:326-8.
9. Mohindra S, Mukherjee KK, Gupta R, Chhabra R, Gupta SK, Khosla VK. Decompressive surgery for acute subdural haematoma leading to contralateral extradural haematoma: a report of two cases and review of literature. *Br J Neurosurg* 2005;19:490-4.
10. Panourias IG, Skandalakis PN. Contralateral acute epidural haematoma following evacuation of a chronic subdural haematoma with burr-hole craniostomy and continuous closed system drainage: a rare complication. *Clin Neurol Neurosurg* 2006;108:396-9.
11. Saberi H, Meybodi AT, Meybodi KT, Habibi Z, Mirsadeghi SM. Delayed post-operative contralateral epidural hematoma in a patient with right-sided acute subdural hematoma: a case report. *Cases J* 2009;3:6282.
12. Shen J, Pan JW, Fan ZX, Zhou YQ, Chen Z, Zhan RY. Surgery for contralateral acute epidural hematoma following acute subdural hematoma evacuation: five new cases and a short literature review. *Acta Neurochir (Wien)* 2013;155:335-41.
13. Wen L, Li QC, Wang SC, Lin Y, Li G, Gong JB, Wang F, Su L, Zhan RY, Yang XF. Contralateral haematoma secondary to decompressive craniectomy performed for severe head trauma: A descriptive study of 15 cases. *Brain Inj* 2013 Feb 15. [Epub ahead of print]
14. Alappat JP, Baiju, Praveen, Jayakumar K, Sanalkumar P. Delayed extradural hematoma: a case report. *Neurol India* 2002;50:313-5.