

# Accuracy of High-Resolution Ultrasound for Evaluating Soft Tissue Tumours of the Hand and Wrist

Jan van Aaken<sup>1</sup>, Jean-Yves Beaulieu<sup>1</sup>, Philippe Vostrel<sup>1</sup>, Stephan Kämpfen<sup>1</sup>, Stefano Bianchi<sup>2</sup>

<sup>1</sup>Hôpital Universitaire de Genève, Service de Chirurgie Orthopédique et Traumatologie de l'Appareil Moteur, Genève, Switzerland; <sup>2</sup>CIM SA, Centre Imagerie Malagnou, Genève, Switzerland

## Abstract

**Citation:** van Aaken J, Beaulieu JY, Vostrel P, Kämpfen S, Bianchi S. Accuracy of High-Resolution Ultrasound for Evaluating Soft Tissue Tumours of the Hand and Wrist. *Maced J Med Sci.* 2012 Dec 15; 5(4):423-427. <http://dx.doi.org/10.3889/MJMS.1857-5773.2012.0236>.

**Key words:** Ultrasound, soft tissue tumours, accuracy, hand, wrist.

**Correspondence:** Jan van Aaken. Hôpital Universitaire de Genève, Service de Chirurgie Orthopédique et Traumatologie de l'Appareil Moteur, 1211 Genève 14, Switzerland. E-mail: [van\\_aaken@hotmail.com](mailto:van_aaken@hotmail.com)

Received: 29-Mar-2012; Revised: 20-Oct-2012; Accepted: 25-Oct-2012; Online first: 02-Nov-2012

**Copyright:** © 2012 van Aaken J. This is an open-access article distributed under the terms of the Creative Commons Attribution License, which permits unrestricted use, distribution, and reproduction in any medium, provided the original author and source are credited.

**Competing Interests:** The author have declared that no competing interests exist.

**Objectives:** High resolution ultrasound (HRUS) is increasingly popular in the assessment of soft tissue tumours. This retrospective study evaluates the reliability of HRUS in diagnosing soft tissue tumours of the hand and wrist, compared to clinical evaluation, intraoperative findings and histological examination.

**Methods:** Sixty-three patients with soft tissue tumours of the hand and wrist were first evaluated clinically investigated. HRUS was then performed using a 5-17 MHz broadband linear probe, with the radiologist blinded to the clinical interpretation. The patient was scheduled for operation depending upon suspected pathology. Histological examination was routinely obtained during surgery.

**Results:** Thirty-one patients underwent surgery. Of the 16 solid lesions HRUS was right in 15 cases (94%). Only nine of these 16 lesions (56%) were correctly diagnosed on clinical examination ( $p=0.041$ ). All 15 cysts were correctly diagnosed by HRUS, whereas clinical examination alone correctly diagnosed a cyst in 14 patients (not significant).

**Conclusion:** No significant difference was found in the differentiation of cystic and solid lesions comparing HRUS and clinical examination. HRUS is significantly better than clinical diagnosis alone in distinguishing the type of solid lesions. Further benefits of HRUS include the identification of atypically localised cysts and improved preoperative planning.

## Introduction

Since its introduction in the late 1970s, ultrasound has been utilized for many applications pertaining to the musculoskeletal system. Although initially used to demonstrate the rotator cuff [1], current applications include evaluation of other tendons, as well as muscles, ligaments, fractures, and bone healing [2]. In addition, ultrasound allows for visualization of more general soft tissue abnormalities such as fluid collection (abscess, bursitis, joint effusion) and foreign bodies [3-6]. One reason for the increased interest and success of

musculoskeletal ultrasound is improved technology. Fifteen years ago, a 7.5-MHz transducer was considered standard, while today transducers with frequencies up to 17 MHz are common. This improvement has resulted in a substantial increase in resolution with regard to superficial structures, permitting for example individual nerve fascicles, tendon fibres [7] and ligaments [8] to be exquisitely demonstrated. Other improvements in ultrasound include power Doppler imaging (improving detection of blood flow) [9], and superior visualization of deeper structures [10].

Several recent articles and reviews have described the sonographic features of a variety of solid and cystic lesions of the hand and wrist [2, 11-13]. On physical examination cystic and solid lesions have overlapping features and clinical symptoms alone do not allow accurate characterization.

We performed a literature search using PubMed and found only three studies, two retrospective [14, 15] and one prospective [16], that evaluated the performance of high resolution ultrasound (HRUS) in the diagnosis of soft tissue tumours in the hand and wrist.

The purpose of this retrospective study was to estimate accuracy levels of 5-17 MHz HRUS in diagnosing soft tissue tumours of the hand and wrist, and compare this to surgical findings and histological examination.

### Materials and Methods

Between May 2006 and October 2007, 63 patients presented with a soft tissue tumour of the hand or wrist. Following a clinical diagnosis by a hand surgeon the patient was referred for HRUS examination. The same musculoskeletal radiologist experienced in

ultrasound and blinded with regards to the clinical diagnosis performed each HRUS using commercially available equipment (Mod. lu22, Philips Medical Systems, Bothell, WA, USA) and a 5-17 MHz broadband linear transducer. At a second hand surgery consultation the results of the HRUS examination were discussed with the patient and an operation was scheduled according to the likely pathology and wishes of the patient. At surgery a histologic examination was routinely ordered except in cases where a cyst was obvious and had been previously diagnosed clinically and ultrasonographically.

As a first step we described the ability of clinical and HRUS examinations to define the specific pathology of solid lesions as compared to histologic examination. Secondly we recorded the results of the clinical and HRUS examinations in distinguishing between cystic and solid lesions as compared to the intraoperative findings and/or histologic examination. We noted true positive (TP) results, defined as cysts that were correctly diagnosed as cysts; true negative (TN) results, defined as solid lesions that were correctly diagnosed as solid; false positive (FP) results where solid lesions were mistaken for cysts; and false negative (FN) results in cases where cysts were mistaken for solid lesions. The results were statistically analysed using the McNemar test.

Table 1: Patients, lesions, and diagnostic accuracy.

Number of patients	Cysts/solid	Histology	HRUS diagnosis	Correctly distinguish cystic/solid?	Correct diagnosis as compared to histology?	Clinical diagnosis	Correctly distinguish cystic/solid ?	Correct diagnosis as compared to histology?
14	Cysts	No histology due to findings of cyst at surgery	Cyst	YES		Cyst	YES	
1		Cyst	Cyst	YES	YES	GCTTS	No	No
2	Solid lesions	Dupuytren	Solid, non-specific	YES	YES	GCTTS	YES	No
1		GCTTS	GCTTS	YES	YES	Cyst	No	No
3		Lipoma	Lipoma	YES	YES	Lipoma	YES	YES
1		Hyperkeratosis	Fibrous nodule	YES	YES	Fibrous nodule	YES	YES
1		Granuloma	Granuloma	YES	YES	Neuroma	YES	No
1		Granuloma	Granuloma	YES	YES	Foreign body	YES	No
1		Granuloma annulare	Hyperkeratosis	YES	No	Granuloma annulare	YES	YES
1		Schwannoma	Schwannoma	YES	YES	Neurogenic tumor	YES	YES
1		Hyperkeratosis	Hyperkeratosis	YES	YES	Glomic tumor	YES	NO
1		Foreign body	Foreign body	YES	YES	Foreign body	YES	YES
1		Angioma	Vascular tumor	YES	YES	Angioma	YES	YES
1		Angioma	Vascular tumor	YES	YES	Foreign body	YES	NO
1		Angioleiomyoma	Vascular tumor	YES	YES	Vascular tumor	YES	YES

GCTTS = giant cell tumors of tendon sheath.

IRB approval was obtained from our hospital ethics committee.

## Results

From the initial 63 patients, 31 patients (15 females, 16 males) with a median age of 45 years (range, 20-78 years) were operated upon and thus comprised the study population. The patients and their lesions, as well as the clinical and HRUS diagnoses are shown in Table 1. Of the 32 patients that were not operated upon and excluded from the study, 31 had a clinical and HRUS diagnosis of a cyst and decided not to undergo surgery. One patient who had a clinical and HRUS suspicion of a giant cell tumour of tendon sheath (GCTTS) moved away from the area and was lost to further follow-up.

In the evaluation of the solid lesions HRUS was correct in 15 of 16 cases (94%). The one incorrect diagnosis was a granuloma annulare that was misdiagnosed as a hyperkeratosis. Only nine of 16 (56%) solid lesions were diagnosed correctly by clinical examination. One case of hyperkeratosis was diagnosed as a fibrous nodule by both HRUS and clinical examination, and validated as correct in both groups as it was very close to the actual diagnosis. This difference was significant (McNemar test,  $p=0.041$ ).

Table 2 shows the results according to the type of lesion, differentiating between cystic ( $n=15$ ) and solid lesions ( $n=16$ ) clinically and by HRUS examination. All cysts were correctly delineated from solid lesions by HRUS, resulting in 15 TP and 16 TN. Clinical evaluation alone resulted in 14 TP results (properly diagnosed cysts), as well as 15 TN cases (properly diagnosed solid lesions). There was one FN case of an intratendinous cyst of the extensor indicis communis ( $EDC_{II}$ ) that was mistaken for a GCTTS, and one FP result of a GCTTS that was mistaken for a cyst. The HRUS examination had a sensitivity of 100%, specificity of 100%, and a positive predictive value of 100%. Clinical examination had a sensitivity of 93%, specificity of 94%, and a positive predictive value of 93%. According to the McNemar test there was no statistical difference between clinical examination and HRUS ( $p=0.48$ ) in differentiating between cysts and solid lesions.

Obvious cysts found at surgery were not sent for histological examination, except for the cyst that was mistaken for a GCTTS. Of the 15 cysts, there were five palpable palmar radial cysts; three cysts arising from the

**Table 2: Results of HRUS (A), and clinical (B) examination according to the type of tumour.**

**A** Cysts versus solid tumours

		+	-
HRUS examination	+	15	0
	-	0	16

positive predictive value = 100%

**B** Cysts versus solid tumours

		+	-
Clinical examination	+	14	1
	-	1	15

positive predictive value = 93%

A2 pulley; three palpable and one non-palpable dorso-radial cysts; one cyst at the insertion of the flexor pollicis longus; one dorsal cyst of the distal interphalangeal joint; and one intratendinous cyst of the  $EDC_{II}$ .

## Discussion

To the best of our knowledge this is the only study where the radiologist was blinded with regards to the clinical diagnosis. While both HRUS and clinical evaluation alone were highly accurate in differentiating between cystic and solid lesions, HRUS was highly accurate in distinguishing the type of solid lesions.

HRUS was able to give the correct diagnosis in 15 of 16 solid masses (94%) as confirmed by histological examination. By clinical evaluation alone only nine of 16 cases (56%) were correctly diagnosed. This difference was significant (McNemar test,  $p=0.041$ ). Specifically, HRUS was more accurate than clinical examination in diagnosing GCTTS. HRUS ruled out the clinical suspicion in all three cases, and raised the suspicion in one case due to its typical echographic pattern (Fig. 1).

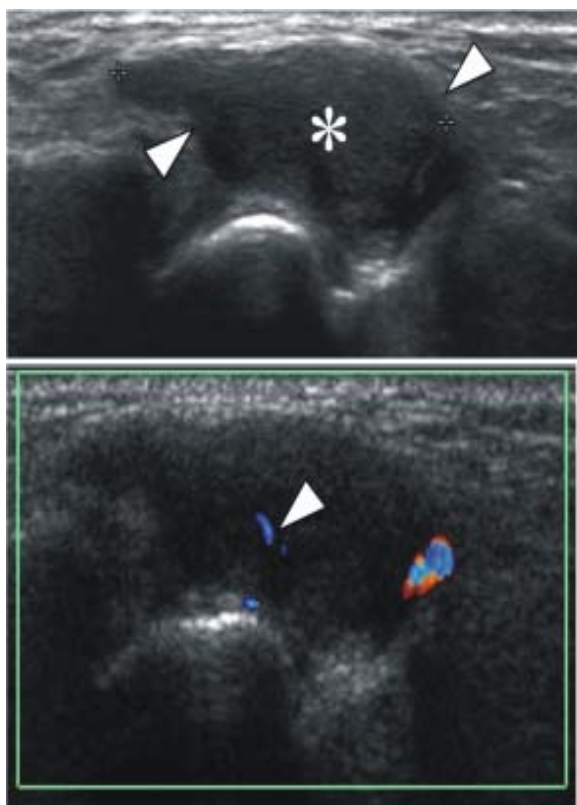


Figure 1: The patient is a 33 year-old woman with a giant cell tumor of the tendon sheath (GCTTS) of the wrist. Sagittal (A) and sagittal color Doppler (B) sonograms obtained over the radial aspect of the wrist show a solid, heterogeneous hypoechoic mass (asterisk) with well-defined borders (arrowheads). In B, note sparse internal flow signals (arrowhead).

HRUS was more accurate in diagnosing granuloma, neuroma and tumours of vascular origin, and as well in eliminating the possibility of foreign bodies. Ultrasonographically, a neurogenic tumour appears as a well-delimited, hypoechoic, solid mass that can show internal vascular changes with colour Doppler. Vascular masses generally appear as less delineated lesions, presenting with a mixed structure composed of solid echogenic and fluid hypo-anechoic components. Changes in the size and shape of these soft masses during local compression with the transducer helps in establishing the correct diagnosis [17]. HRUS incorrectly diagnosed a granuloma annulare as hyperkeratosis; however the differentiation between cystic and solid was correct.

HRUS was able to correctly diagnose all 15 cysts. It was slightly more reliable (PPV= 100%) than the clinic examination alone (PPV= 93%) where a cyst of the

EDC<sub>II</sub> had been misdiagnosed as a GCTTS; however this difference was not significant (McNemar test,  $p=0.48$ ).

In the literature, an earlier retrospective study [14] performed with a 7 MHz transducer found ultrasound very accurate in diagnosing cysts but less accurate for solid lesions. Of 26 clinical suspicions of a cyst there were 25 correct results, but only 9 of 13 correct results for solid lesions. However, not all patients were operated upon, and there was no correlation with the initial clinical impression for the solid masses. Another retrospective study [15] performed with a 9- 13 MHz transducer showed the ultrasonographic diagnosis to be correct in 87% of cystic lesions (67% correct clinical diagnosis) and in 73% of the solid lesions (0% correct clinical diagnosis). The initial clinical impression was correct in 54% of all cases, and in 71% of cases with the incorrect clinical diagnosis HRUS was able to provide the correct diagnosis. A more recent prospective study [16] performed with a 5-13 MHz transducer demonstrated that HRUS was more reliable than clinical examination, with 100% correct results for diagnosing cysts and 82.1% for diagnosing solid lesions vs. 86.1% clinically correct diagnoses for cystic lesions and 33.3% for solid masses, respectively.

Our results and previously published studies [14-16] demonstrate that the clinical diagnosis of a cyst is highly reliable, and that HRUS gives predictably better results diagnosing cysts than differentiating solid masses that are a heterogeneous entity with sometimes sonographically overlapping features. While the objective of our study was not to define the indication for ancillary studies in diagnosing focal lesions in the hand, the question of the utility of HRUS needs to be addressed.

The benefit of HRUS does not lie in its capacity to diagnose a ganglion when it is clinically evident (palpable) and located in a typical place such as on the volar or dorsal wrist or on a pulley. In such cases the rate of correct clinical diagnosis is high as confirmed by our study. However, as soon as the cyst is localized elsewhere the clinical success rate is lower, e.g. in the present study where an intratendinous cyst of the EDC<sub>II</sub> was missed. Previously it has been shown that ultrasound is also accurate for diagnosing occult ganglia [18]. The benefit of HRUS would be to confirm a suspected occult ganglion and assist in the decision-making process. In the case of a combined dorsal and volar ganglion HRUS can also be helpful to determine if it is actually the same cyst expanding from dorsal to palmar, since knowledge of its origin can help to minimize the surgical approach.



It must be remembered that cysts can only be seen by HRUS if they are inflated, for if they are collapsed they may be missed or misdiagnosed as a solid lesion [15]. For a suspected foreign body their actual existence, exact localization, size, and number is valuable information for the surgeon to avoid an unnecessary surgical intervention, extensile incisions and prolonged surgery. Even though HRUS is unable to differentiate between the different tumours of nervous origin, the preoperative diagnosis of such tumours is critical. It helps to establish a treatment plan, alert the surgeon that a nerve reconstruction may be required, and to inform the patient about the expected outcome. With regard to our study it appears that the higher resolution of the equipment and the experience of the radiologist contributed in providing more reliable results. Since HRUS is very much an operator-dependent examination it can only be as good as the operating radiologist. The differential diagnosis of the radiologist is a synthesis of ultrasonic patterns and his or her own clinical experience, and thus one limitation of our work could be that a less experienced radiologist may not reproduce the same results as in our study. Additionally, while not investigated in our study it would seem obvious that the experience of the hand surgeon would as well have an impact on the clinical diagnosis. The fact that only half the study population underwent surgery was due to the HRUS findings that demonstrating a cystic lesion in all but one of these cases, and thus only a relative indication for surgery.

A further limitation of our study is the small number of cases, which may be explained by the delivery of health care in our city where focal lesions of the hand are unlikely to be referred to a university hospital.

**Conclusion:** No significant difference was found in the differentiation of cystic and solid lesions comparing HRUS and clinical examination. HRUS is significantly better than clinical diagnosis alone in distinguishing the type of solid lesions. Further benefits of HRUS include the identification of atypically localised cysts and improved preoperative planning. HRUS examination is useful in the hands of an experienced operator.

## Acknowledgement

We thank Dr. Richard Stern from the University Hospitals of Geneva for assistance in preparation of the manuscript.

## References

1. Mayer V. Ultrasonography of the rotator cuff. *J Ultrasound Med.* 1985;4(11):607-608.
2. Jacobson JA, van Holsbeeck MT. Musculoskeletal ultrasonography. *Orthop Clin North Am.* 1998;29(1):135-67.
3. Lin J, Fessell DP, Jacobson JA, Weadock WJ, Hayes CW. An illustrated tutorial of musculoskeletal sonography: part 3, lower extremity. *AJR Am J Roentgenol.* 2000;175(5):1313-21.
4. Lin J, Fessell DP, Jacobson JA, Weadock WJ, Hayes CW. An illustrated tutorial of musculoskeletal sonography: part 1, introduction and general principles. *AJR Am J Roentgenol.* 2000;175(3):637-45.
5. Lin J, Jacobson JA, Fessell DP, Weadock WJ, Hayes CW. An illustrated tutorial of musculoskeletal sonography: part 2, upper extremity. *AJR Am J Roentgenol.* 2000;175(4):1071-9.
6. Lin J, Jacobson JA, Fessell DP, Weadock WJ, Hayes CW. An illustrated tutorial of musculoskeletal sonography: part 4, musculoskeletal masses, sonographically guided interventions, and miscellaneous topics. *AJR Am J Roentgenol.* 2000;175(6):1711-9.
7. Silvestri E, Martinoli C, Derchi LE, Bertolotto M, Chiaramondia M, Rosenberg I. Echotexture of peripheral nerves: correlation between US and histologic findings and criteria to differentiate tendons. *Radiology.* 1995;197(1):291-6.
8. Sconfienza LM, Silvestri E, Cimmino MA. High-resolution ultrasound evaluation of extrinsic wrist ligaments in patients affected by rheumatoid arthritis. *Eur Radiol.* 2012;22(7):1586-91.
9. Bude RO, Rubin JM. Power Doppler sonography. *Radiology.* 1996;200(1):21-3.
10. Rosenthal SJ, Jones PH, Wetzel LH. Phase inversion tissue harmonic sonographic imaging: a clinical utility study. *AJR Am J Roentgenol.* 2001;176(6):1393-8.
11. Bianchi S, Della Santa D, Glauser T, Beaulieu JY, van Aaken J. Sonography of masses of the wrist and hand. *AJR Am J Roentgenol.* 2008;191(6):1767-75.
12. Garcia J, Bianchi S. Diagnostic imaging of tumors of the hand and wrist. *Eur Radiol.* 2001;11(8):1470-82.
13. Jacob D, Cohen M, Bianchi S. Ultrasound imaging of non-traumatic lesions of wrist and hand tendons. *Eur Radiol.* 2007;17(9):2237-47.
14. Read JW et al. Diagnostic ultrasound of the hand and wrist. *J Hand Surg Am.* 1996;21(6):1004-10.
15. Teefey SA, Middleton WD, Patel V, Hildebolt CF, Boyer MI. The accuracy of high-resolution ultrasound for evaluating focal lesions of the hand and wrist. *J Hand Surg Am.* 2004;29(3):393-9.
16. Allen GM, Drakonaki EE, Tan ML, Dhillon M, Rajaratnam V. High-resolution ultrasound in the diagnosis of upper limb disorders: a tertiary referral centre experience. *Ann Plast Surg.* 2008;61(3):259-64.
17. Bianchi SM. *Ultrasound of the Musculoskeletal System.* ed. Springer: Berlin, Heidelberg, New York, 2004.
18. Cardinal E, Buckwalter KA, Braunstein EM, Mih AD. Occult dorsal carpal ganglion: comparison of US and MR imaging. *Radiology.* 1994;193(1):259-62.