

## Screening of BRCA1 Mutations Using C-terminal Antibody in Sporadic non Familial Colonic Carcinoma

Reham Sh. Esmail, Walid M. Sharaf, Noha A. Helmy, Abdel Razik H. Farrag, Manal A. Badawi, Amina A. Gamal Eldin

*Pathology Department, National Research Centre, Cairo, Egypt*

### Abstract

**Citation:** Esmail RS, Sharaf WM, Helmy NA, Farrag ARH, Badawi MA, Eldin AAG. Screening of BRCA1 Mutations Using C-terminal Antibody in Sporadic non Familial Colonic Carcinoma. *Maced J Med Sci.* 2012 Dec 15; 5(4):377-381. <http://dx.doi.org/10.3889/MJMS.1857-5773.2012.0258>.

**Key words:** Sporadic cancer colon; BRCA1; Immunohistochemistry.

**Correspondence:** Dr. Abdel Razik H. Farrag, Pathology Department, National Centre, Dokki, Cairo, Egypt, P.O. 12622, E-mail: [abdelrazikfarrag@yahoo.co.uk](mailto:abdelrazikfarrag@yahoo.co.uk)

Received: 31-May-2012; Revised: 19-Aug-2012; Accepted: 24-Aug-2012; Online first: 18-Oct-2012

**Copyright:** © 2012 Esmail RS. This is an open-access article distributed under the terms of the Creative Commons Attribution License, which permits unrestricted use, distribution, and reproduction in any medium, provided the original author and source are credited.

**Competing Interests:** The author have declared that no competing interests exist.

**Background:** Cancer colon is one of the most prevalent cancers in Egypt. Sporadic cancer colon is much more common than familial type; the latter accounting for not more than 30% of the reported cases in different registrations. BRCA1 is a tumor suppressor gene which is proved to be mutated in many cancer types. Limited studies tried to screen its mutation in cancer colon.

**Aim:** This work is aimed to screen BRCA1 mutations using C-terminal antibody in sporadic non familial colonic carcinoma.

**Subjects and Methods:** Fifty colectomy specimens were collected. Sections of paraffin blocks were cut ( $\mu\text{m}$  thickness), then stained with Hematoxylin and eosin and evaluated for tumor type and its nuclear grade and its stage. Immunohistochemical studies for BRCA1 were performed.

**Results:** positive nuclear immunostaining of BRCA1 staining was detected in 84% of the cases, with insignificant correlation with both the grade and the stage  $p \sim 0.42$ ,  $p \sim 0.31$  respectively.

**Conclusion:** This type of staining denies a direct role of BRCA1 axon 11 mutations in sporadic colonic cancer - unlike some sporadic ovarian and breast cancers - and may point to that BRCA1 may share in the early tumorigenesis in a way other than the usual mutation of exon 11.

### Introduction

Cancer colon is the third most commonly diagnosed cancer in both men and women. One million new patients are diagnosed and over half of these patients succumb to the disease each year. In Egypt, as in other developing countries, young age of incidence has been noticed in the last years in some registries [1]. According to the available registry most of the cancer

colon cases are sporadic with the familial cases representing not more than 30% of the worldwide cases [2].

BRCA1 (Breast Cancer 1, early onset), is a tumor suppressor gene that regulates the cycle of cell division by keeping cells from growing and dividing too rapidly or in an uncontrolled way. BRCA1 gene is mapped to chromosome 17q12q21. The protein made by the

BRCA1 gene is directly involved in the repair of damaged DNA [3].

Researchers have identified more than 600 mutations in the BRCA1 gene, many of which are associated with an increased risk of cancer. These mutations can be changed in one or a small number of DNA base pairs, or, in some cases, large rearrangements of DNA. A mutated BRCA1 gene usually makes a protein that does not function properly because it is abnormally short. Researchers believe that the defective BRCA1 protein is unable to help fix mutations that occur in other genes. These defects accumulate and may allow cells to grow and divide uncontrollably to form a tumor [4].

The mutant BRCA1 allele is proved to increase risks for breast and ovarian cancers as well as some other tumors including cancer prostate and pancreas [5]. Many authors expected BRCA1 mutations or loss in cancer colon [6-7]. However, to date, the suggestion of germ line mutations in BRCA1 being incorporated in increasing the incidence of colorectal cancer meets controversy, and both positive and negative results have been reported [8].

On using the immunohistochemical technique, different types of staining have been described: nuclear, cytoplasmic, or both [9-10]. However, the nuclear localization is the most consistent with the role of BRCA1 in the maintenance of genome integrity: cell cycle control and DNA repair.

The aim of the study is to examine the localization of BRCA1 with the C-terminal monoclonal antibody using an immunohistochemical technique, in sporadic non familial cancer colon cases, in order to screen any possible relation between BRCA1 mutations and cancer colon.

## Material and Methods

### *Specimens*

Fifty colectomy specimens were collected retrospectively from different private labs over the period of 9 months. The cases were examined and included in the study according to the following criteria:

50 Documented histopathologic diagnosis of colonic adenocarcinoma.

51 Negative family history of cancer colon within the first degree relatives (according to the definition of

familial cancer colon).

Ethically, the names were replaced by numerical codes.

The paraffin blocks were cut at 4  $\mu$ m thickness; Sections were then stained with Hematoxylin and eosin and evaluated for tumor type and its nuclear grade and its stage according to the WHO criteria.

The multivariate ANOVA test is used with the p value of 0.05 or less considered significant.

### *Immunohistochemical study*

Immunohistochemical study for BRCA1 was performed according to Hsu et al method [11]. Sections were placed in an oven at 37°C overnight to melt the paraffin, and then dewaxed in 4 changes of xylene 5 minutes each, then rehydrated in decreasing ethanol concentrations. Sections were then treated in a ready to use antigen retrieval; by insertion in a microwave oven for 3-5 minutes until boiling, then ceasing and adding distilled water, that was repeated for another 3 minutes, then sections were left to cool for 20 minutes at room temperature and then washed twice for 5 minutes each in phosphate- buffered saline (PBS).

Peroxidase blocking was done by adding 2 drops of peroxidase blocking serum for 10 minutes, then rinsing with PBS PH7.6. Sections were then incubated in the serum blocking solution for 10 minutes without rinsing, and subsequently with the primary antibody, (*The SG 11 monoclonal antibody (Zymed Laboratories, South San Francisco, No 33-7500) directed against peptides corresponding to C-terminal amino acids 1839 to 1863 of the human BRCA1 protein*), by adding 2 drops to each section, and incubating in moist chamber for 4 hours. After a prolonged wash with PBS, sections were incubated with 2 drops of the pre-diluted biotinylated secondary antibody goat anti-mouse IgG to each section. This antibody serves as a link between the primary antibody and the label, and then rinsing with PBS was done. Addition of the label was done by adding 2 drops of the peroxidase conjugated streptavidin followed by incubation for 60 minutes, then rinsing with PBS.

A substrate/chromogen (DAB) mixture was prepared and added to the sections followed by rinsing with distilled water. Slides were then counterstained by Mayer's haematoxylin and then mounted in Canada balsam.

### Scoring

Tumors with nuclear staining were considered positive. Immunoreactivity for BRCA1 was quantitatively estimated according to previous reports [12]: 0 (no staining), weakly positive (+) corresponded to 10-30% positive cells, moderately positive (++) corresponded to 30-50% positive cells and strongly positive (+++) corresponded to more than 50% positive cells.

### Results

The study included 50 cases of colonic adenocarcinoma of sporadic non familial cases according to the aforementioned criteria.

#### Classification of the cases

##### A) According to the age:

The age of the studied cases was ranged from 30 years up to 65 years. It was found that about 88% of these cases (44 cases) above the age of 40 year (Table 1).

**Table 1: Classification of the cases according to the age.**

| Age          | 30 - 40 years | 40-50 years | 50-60 years | Above 60 years |
|--------------|---------------|-------------|-------------|----------------|
| No. of cases | 6             | 14          | 17          | 13             |
| %            | 12            | 28          | 34          | 26             |

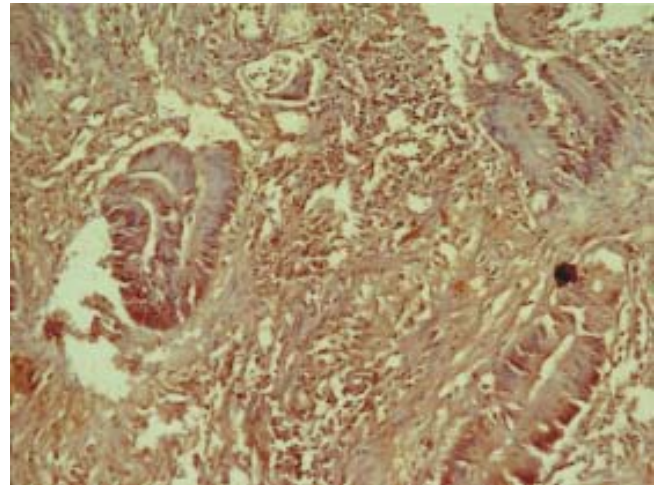
b) According to the gender: In the study, it was found that the most of the included cases were females and represented about 64% of the cases (32 cases) (Table 2).

**Table 2: Classification of the cases according to the gender.**

| Gender       | Male | Female |
|--------------|------|--------|
| No. of cases | 18   | 32     |
| %            | 36   | 64     |

c) According to the tumor stage-depending on the depth of invasion – (T): Most of the included cases (56%) were of the stage T3 (tumor extended to the subserosa), while rest of the cases (44%) were at stage T2 (tumor limited to the mucularis propria). None of the cases were at stage 1 or 4 (Table 3).

d) According to the tumor nuclear grading: It



**Figure 1: Positive nuclear staining in more than 50% of the tumour cells (score +++) (BRCA1 – immunostain X200).**

was found that the most of the cases were of nuclear grading II (62%), and the rest was of grade III (38%). None of the cases were of grade I.

**Table 3: Correlation of the tumor stage (T) with the immunostaining.**

| Immune score | Tumor stage |           |           |
|--------------|-------------|-----------|-----------|
|              | T1 No (%)   | T2 No (%) | T3 No (%) |
| 0            | 0           | 5 (22.7)  | 3 (10.7)  |
| +            | 0           | 6 (27.3)  | 10 (35.7) |
| ++           | 0           | 7 (31.8)  | 8 (28.6)  |
| +++          | 0           | 4 (18.2)  | 7 (25)    |
| Total        | 0           | 22 (44)   | 28 (56)   |

#### Immunohistochemical results

The BRCA1 immunostaining showed positive nuclear staining of the tumor cells in 84% of the included cases (Fig. 1), with insignificant association with tumor grade-p value ~ 0.42, (Table-3) and its stage - p value ~ 0.31 (Table-4).

**Table 4: Correlation between the nuclear grading with the immunostaining.**

| Immune score | Grade     |            |           |
|--------------|-----------|------------|-----------|
|              | G1 No (%) | G2 No (%)  | G3 No (%) |
| 0            | 0         | 4 (12.9)   | 4 (21.05) |
| +            | 0         | 10 (32.25) | 6 (31.6)  |
| ++           | 0         | 10 (32.25) | 5 (26.3)  |
| +++          | 0         | 7 (22.6)   | 4 (21.05) |
| Total        | 0         | 31 (62)    | 19 (38)   |

## Discussion

The present work studied the immunohistochemical expression of BRCA1 mutations using C-terminal antibody in sporadic non familial colonic carcinoma.

The study included 50 cases of colonic adenocarcinoma, collected retrospectively. Although the current study is not a registry one, as certain inclusion criteria controlled the selection of cases, however, certain epidemiologic data could be screened through it. The age of cases ranged from 30 years to 65 years with most of the cases above 40 years. This finding was almost similar to the results of the national cancer institute-Egypt (NCI) in the last statistical study in 2007 [13], and Elgharbeia registry in 2007 [14], which came in contrast to what was obtained by Khafagy et al [1] who noticed that most of the colonic carcinomas in Egypt and other developing countries occurred in young population with the mean age 45 years. In 2002, Abou Zeid et al [15] recorded that no age predilection could be observed and that more than one third of the affected patients were of the young population.

According to current study results; BRCA1 staining was noticed as nuclear stain in 84% of the cases with weak staining (+) in 16 case, moderate staining (++) in 15 case and strong staining (+++) in 11 case. No significant correlation could be observed between BRCA1 protein expression and different nuclear grades (p value ~ 0.42) and tumor stage (p value ~ 0.31).

Being a dominant mutant gene in familial cancer of the ovary and breast; some authors had studied BRCA1 immunostaining in colonic cancers; and so few studies are available. In ovarian cancer, Kashima and his colleagues [16] found nuclear staining using C-terminal antibody (GLK-2) in the majority of tumor samples from familial cancer patients without BRCA1 mutations (90%), and sporadic ovarian cancer patients (85%), as well as normal ovarian tissues (100%). Although Kashima and his colleagues [16] obtained significant correlation between the immunohistochemical staining pattern and the mutational position of the BRCA1 gene; BRCA1 mutation in exon 11 was indicated by cytoplasmic staining, mutation in exons other than exon 11 was indicated by absence of BRCA1 staining, and the absence of BRCA1 mutation was indicated by nuclear staining [16]. Other authors found that the interpretation of the results is not always significantly informative at the immunostaining level as different types of staining have been described: nuclear, cytoplasmic, or both [9-10]. This may be

explained by differences in the specificity of the antibodies [10], different fixation methods [9], or by the existence of splice variant isoforms of the BRCA1 protein [12]. However, the use of monoclonal antibodies and fixation in neutral buffered formalin after antigen exposure in a microwave demonstrates a predominantly nuclear labeling [17].

Accordingly, the non tumorous colonic mucosa is expected to show positive nuclear immunostaining for BRCA1, which denies any mutation of the axon11 in the gene. The presence of some negative cases (nuclear staining less than 10%) and some negative cells even in positive cases may point to other abnormality in BRCA1 gene, preventing it from practicing its normal expected function as a tumor suppressor gene.

In summary, there is much controversy as regards the role and localization of BRCA1 protein expression in sporadic colonic cancer. BRCA1 showed positive nuclear staining in most of the cases which may indicate that BRCA1 may share in the early tumorigenesis of cancer colon in a pathway other than the mutation of exon 11.

Nevertheless, since a definite advantage is afforded by the immunohistochemical technique, the prospect of a project which screens familial colorectal carcinomas offers an attractive model for further investigation.

## References

1. Khafagy W, El-Ghazaly M, E-Shobaky M, Khafagy M. Colorectal Cancer in Egypt - Does it Differ? *Coloproctology*. 2000; 22:109-15.
2. Kerber RA, Neklason DW, Samowitz WS, Burt RW. Frequency of Familial Colon Cancer and Hereditary Nonpolyposis Colorectal Cancer (Lynch Syndrome) in a Large Population Database. *Fam Cancer*. 2005; 4:239-44.
3. Scully R. Role of BRCA gene dysfunction in breast and ovarian cancer predisposition. *Breast Cancer Res*. 2000; 2:324-30.
4. Lakhani SR, Manek S, Llorca FP, Flanagan A, Arnout L, Merrett S, McGuffog L, Steele D, Devilee P, Klijn JGM, Meijers-Heijboer H, Radice P, Pilotti S, Nevanlinna H, Butzow R, Sobol H, Jacquemie J, Lyonnet DS, Neuhausen SL, Weber B, Wagner T, Winqvist R, Bignon YJ, Monti F, Schmitt F, Lenoir G, Seitz S, Hamman U, Pharoah P, Lane G, Ponder B, Bishop DT, Easton DF. Pathology of Ovarian Cancers in BRCA1 and BRCA2 Carriers. *Clin Cancer Res*. 2004; 10:2473-81.
5. Thompson D, Easton DF. Cancer Incidence in BRCA1

Mutation Carriers. *J Natl Cancer Inst.* 2002; 94:1358-65.

6. Brose MS, Rebbeck TR, Calzone KA, Stopfer JE, Nathanson KL, Weber BL. Cancer Risk Estimates for BRCA1 Mutation Carriers Identified in a Risk Evaluation Program. *J Natl Cancer Inst.* 2002; 94:1365-72.

7. Niell B, Rennert G, Bonner JD, Along R, Tomsho LP, Gruber SB. BRCA1 and BRCA2 Founder Mutations and the Risk of Colorectal Cancer. *J Natl Cancer Inst.* 2004; 96:15-21.

8. Suchy J, Cybulski C, Górski B, Huzarski T, Byrski T, Dębniak T, Gronwald J, Jakubowska A, Wokołarczyk D, Kurzawski G, Kładny J, Jawieñ A, Banaszkiwicz Z, Wićniowski R, Wandzel P, Starzewski J, Lorenc Z, Korobowicz E, Krokowicz P, Horbacka K, Lubiñski J, Narod SA. BRCA1 mutations and colorectal cancer in Poland. *Fam Cancer.* 2010; 9:541-44.

9. Coene E, Van Oostveldt P, Willems K, van Emmelo J, De Potter CR. BRCA1 is localized in cytoplasmic tube-like invaginations in the nucleus. *Nat Genet.* 1997; 6:122-24.

10. Pérez-Vallés A, Martorell-Cebollada M, Nogueira-Vázquez E, García-García JA, Fuster-Diana E. The usefulness of antibodies to the BRCA1 protein in detecting the mutated BRCA1 gene: An immunohistochemical study. *J Clin Pathol.* 2001; 54:476-80.

11. Hsu SM, Raine L, Fanger H. The use of avidin-biotin-peroxidase complex (ABC) in immunoperoxidase techniques: A comparison between ABC and unlabelled antibody (PAP) procedures. *J Histochem Cytochem.* 1981; 29:577-80.

12. Wilson CA, Payton MN, Elliott GS, Buas FW, Cajulis EE, Grosshans D, Ramos L, Reese DM, Slamon DJ, Calzone FJ. Differential subcellular localization, expression and biological toxicity of BRCA1 and the splice variant BRCA1-delta 11b. *Oncogene.* 1997; 14:1-16.

13. Mokhtar N, Gouda I, Adel I. Malignant endocrine system tumors. In: *Cancer pathology registry 2003-2004 and time trend analysis 1<sup>st</sup> ed.* NCI, 2007; pP 91-3.

14. Ibrahim AS, Seif-Eldein IA, Ismail K et al. Endocrine system. In: *cancer in Egypt, Gharabiah.* MECC. Ministry of Health & Population Egypt, 2007; pP 45-660.

15. Abou-Zeid AA, Khafagy W, Marzouk DM, Alaa A, Mostafa I, Aboul Ela M. Colorectal Cancer in Egypt. *Dis Colon Rectum.* 2002;1255-60.

16. Kashima K, Oite T, Aoki Y, Takakuwa K, Aida H, Nagata H, Sekine M, Wu HJ, Hirai Y, Wada Y, Yamamoto K, Hasegawa K, Sonoda T, Maruo T, Nagata I, Ohno M, Suzuki M, Kobayashi I, Kuzuya K, Takahashi T, Torii Y, Tanaka K. Screening of BRCA1 Mutation Using Immunohistochemical Staining with C-Terminal and N-Terminal Antibodies in Familial Ovarian Cancers. *Jpn J Cancer Res.* 2000; 91:399-409.

17. Vaz FH, Machado PM, Brandão RD, Laranjeira CT, Eugénio JS, Fernandes AH, André SP. Familial Breast/Ovarian Cancer and BRCA1/2 Genetic Screening: The Role of Immunohistochemistry as an Additional Method in the Selection of Patients. *J Histochem Cytochem.* 2007; 55:1105-13.