

PREVALENCE OF RETROMOLAR FORAMEN IN HUMAN MANDIBLES AND ITS CLINICAL SIGNIFICANCE

Meera Jacob ^{*1}, Ramakrishna Avadhani ², Bindhu.S ³, Rani Nallathamby ⁴, Meril Ann Soman ⁵.

^{*1} Assistant Professor, ² Professor and Head, ³ Associate Professor, ^{4,5} Post Graduates.
Department Of Anatomy, Yenepoya Medical College, Mangalore, Karnataka, India.

ABSTRACT

Retromolar foramen is found in the triangular area behind the lower last molar tooth and it allows the passage of neurovascular bundle that contribute to the nutrition and innervations of the pulp and periodontium of the lower teeth. In the present study one hundred and twenty mandibles were examined for the presence of retromolar foramen. Retromolar foramen was found in two mandibles bilaterally and in thirteen mandibles unilaterally (in 10 on the right side and in 3 on the left side). The distance between posterior third molar to the retromolar foramen was found to be an average of 9.8mm on the right side and 8.05mm on the left side. Distance between anterior border of ramus to retromolar foramen was found to be an average of 5.68mm on the right side and 5.77 on the left side. Retromolar foramen is surgically very significant. Knowledge of this anatomical variation can prevent complications in anaesthesia and surgical procedures in this area.

KEYWORDS: Retromolar foramen, Inferior alveolar neurovascular bundle, last molar tooth.

Address for Correspondence: Dr. Meera Jacob, Assistant Professor, Department of Anatomy, Yenepoya Medical College, Mangalore, India. **E-Mail:** meera_jacob83@yahoo.co.in

Access this Article online

Quick Response code



Web site: International Journal of Anatomy and Research
ISSN 2321-4287
www.ijmhr.org/ijar.htm

Received: 14 Aug 2014

Peer Review: 14 Aug 2014 Published (O): 19 Sep 2014

Accepted: 01 Sep 2014 Published (P): 30 Sep 2014

INTRODUCTION

Morphology of human mandible and its variations are very important for planning of various surgeries like mandibular reconstruction, extraction of third molar also known as wisdom tooth and for installation of dental implants [1]. The mandibular region includes this tooth, its supporting elements and the adjacent soft parts, the lingual nerve and the elements of paralingual space. Posterior to the third molar there is triangular retromolar triangle and retromolar fossa laterally [2]. Retromolar fossa is located between the anterior border of mandibular ramus and the temporal crest. This may have an inconstant foramen called retromolar foramen. This foramen transmits

neurovascular structures that contribute to nutrition and innervations of the pulp and periodontium molar teeth [3]. These structures are vulnerable to damage during endodontic treatment and sagittal split osteotomy surgeries. Failures in the anaesthesia by regional blockade of inferior alveolar nerve are reported due to presence of these foramina [4]. This foramen extends as canal into the body of mandible and is regarded as an anatomical variation. Clinically this area forms a corridor for passage of infections arising in connection with the third molar [5]. Ossenberg demonstrated the importance of retromolar foramen as an anatomical landmark and suggested that the frequency of the foramen varies according to ethnic factors [6].

Sawyer and Kiely have reported 7.7 percent occurrence of retromolar foramina in 234 adult human mandibles. They also reported that the incidence of retromolar foramen does not show differences as regards to side and sex but does have positive correlation with the accessory mandibular foramen [4]. Kondera and Hashimoto reported the foramen and canal in 8 out of 41 Japanese mandibles and noticed the branches of inferior alveolar nerve passing through the canal [7]. Though these variations in the incidence of retromolar foramen is important for the practising surgeons, It has been neglected and not well documented in all textbooks. On this background, the present study is done to evaluate the incidence of retromolar foramen in human mandible and discuss the clinical aspects related to the presence of this foramen.

MATERIALS AND METHODS

Total of 120 human mandibles were examined for the presence of retromolar foramen or canal in the Department of Anatomy, Yenepoya Medical College, Mangalore. In each mandible, the area behind the last molar tooth was carefully inspected for the presence of retromolar foramen. Their location in relation to third molar was taken into account and measured with a digital calliper to the nearest millimetres. Mandibles with marked deformities or any fractures were excluded from the study.

OBSERVATIONS:

Retromolar foramen was found in 15 of 120 mandibles (12.5%) of which 10 on the right side and 3 on left side (10.83%) and 2 bilaterally (1.6%) (Table1). The occurrence of retromolar foramen was more in males when compared to females (Graph 1). The distance between posterior third molar to the retromolar foramen was found to be an average of 9.8mm on the right side and 8.05mm on the left side. Distance between anterior border of ramus to retromolar foramen was found to be an average of 5.68mm on the right side and 5.77 on the left side

Table1: Distribution of retromolar foramen.

Sex	Right	Left	Bilateral	Total	Percentage
Male	7	2	2	11	9.16%
Female	3	1	Nil	4	3.33%

Graph 1: Distribution of retromolar foramen in males and females.

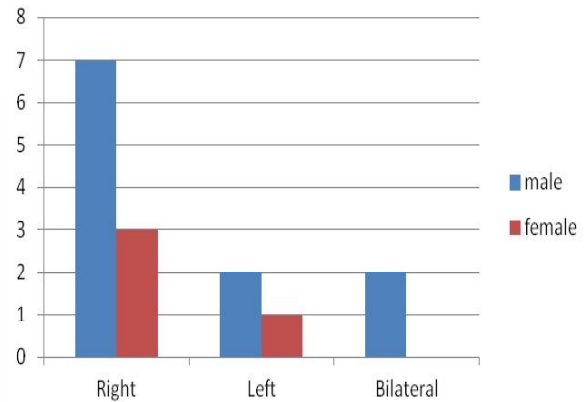


Fig. 1: Showing Retromolar Foramen bilaterally.

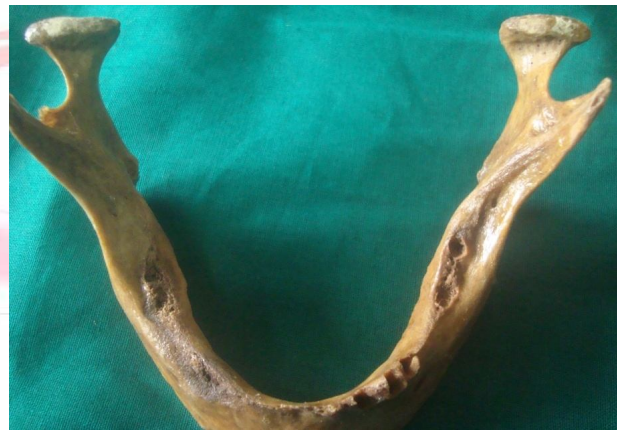

Fig. 2: Showing retromolar foramen on left side.

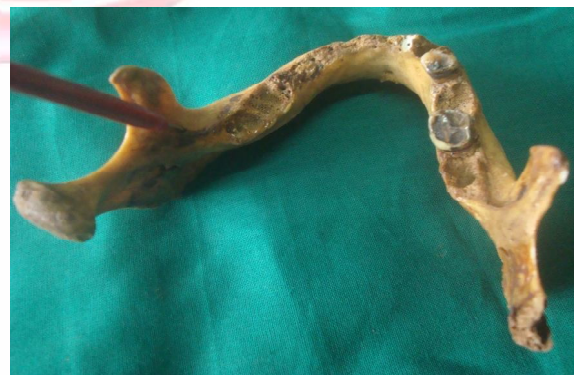
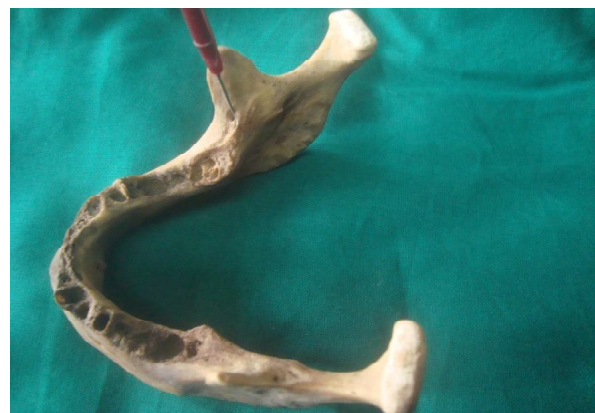
Fig. 3: Showing retromolar foramen on right side.



DISCUSSION

Retromolar foramen is a nonmetric cranial variant. The incidence of retromolar foramen in our study was 12.5%. It is higher than what reported by Sawyer et al (1991), 7.7% in Americans [4], but lower than that reported by Narayana et al (2002) is 21.9% [8] and Senthil and Kesavi (2010) is 17.3% in South Indian population [9]. Ossenberg [6] carried out an analysis of retromolar foramen in large series of mandibles (n=2500) and suggested that the population of Latin America such as Argentina, Colombia and Brazil were more likely to possess this foramen due to heterogeneity of individuals. He also reported that the retromolar foramen is more frequent unilaterally than bilateral in mandibles of these populations. Kodera and Hashimoto dissected retromolar foramen in Japanese cadavers and found that inferior alveolar neurovascular bundle was traversing through the canal. The artery after emerging from the mandibular canal anastomosed with the branches of buccal artery and the facial artery. The nerve was found to supply the lower third molar, mucosa of retromolar trigone and the buccal gingival of premolar and molar region. It was also observed that the retromolar foramen extended into the body of mandible as retromolar canal [7]. Narayana et al described three morphological types of retromolar canals in their study using injection of radiopaque dye Angiograffin into the retromolar foramen. Type 1 was a single canal that descended vertically to the mandibular canal. Type 2 canal first descended and then turned backward to join the mandibular canal. Type 3 canal descended vertically but another canal traversed anteriorly [8]. Schejman et al performed dissection of retromolar canal in cadavers during autopsy, where the contents were subjected to histological examination, it was found that the most constant element is a myelinated nerve. They also found one or more arterioles and one or more venules in descending order of frequency [10].

The presence of retromolar foramen and canal and its contents have great clinical significance and can be injured in various surgical procedures like flap lifting, bone tissue for autologous bone grafts, osteotomy for the surgical extraction of

third molar, placement of osseointegrated implants for orthodontic or in sagittal split osteotomy surgeries [11]. So retromolar foramen is considered as potential route for additional innervation to the lower third molar region causing failure in anaesthetic mandibular blocking¹². With refinements in scoring criteria, Retromolar foramina should be useful along with other cranial variants for ethno historical studies [6].

CONCLUSION

Present study establishes the incidence of retromolar foramen in south Indian mandibles and its clinical significance. During routine anaesthetic, surgical and implantation procedures of the mandible, care should be taken not to damage the neurovascular bundle passing through the retromolar foramen and should be diagnosed with the help of panoramic radiographs.

Conflicts of Interests: None

REFERENCES

- [1]. Claeys V. & Wackens G. Bifid mandibular canal: literature review and case report. *Dentomaxillofac. Radiol.* 2005; 34(1): 55-8.
- [2]. Suazo Gic, Zavando Mda, and Smith RI. Is the conduct of Serres an anatomical variation in adults? *International Journal of Morphology.* 2009; 27(1): 43-47.
- [3]. Sicher H. *Oral Anatomy.* 3rd ed. St. Louis, MO, Mosby, 1960.
- [4]. Sawyer D. R. & Kiely M. L. Retromolar foramen: A mandibular variant important to dentistry. *Ann. Dent.* 1991; 50(1): 16-8.
- [5]. Libersa JC, Francke JP, Boudin G, Goudaert M, Libersa C. Anatomical basis for the surgical approach to the dental roots. *Anat Clin.* 1982; 3: 221-227.
- [6]. Ossenberg, N. S. Retromolar foramen of the human mandible. *Am. J. Phys. Anthropol.* 1987; 73(1): 119-28.
- [7]. Kodera H and Hashimoto I. A case of mandibular retromolar canal; elements of nerve and arteries in this canal. *Kaibogaku-Zasshi.* 1995; 70: 23-30.
- [8]. Narayana Nayak UA, Ahmed WN, Bhat JG, Devaiah BA. The retromolar foramen and canal in south Indian dry mandibles. *European Journal of Anatomy.* 2002; 6: 141-146.
- [9]. Senthil Kumar S, Kesavi D. A Study on the incidence of Retromolar Foramen and Canal in Indian Dried Human Mandibles and its Clinical Significance. *International Journal of Anatomical Sciences.* 2010; 1: 14-16.

- [10]. Schejtman R, Devoto F. C. & Arias N. H. The origin and distribution of the elements of the human mandibular retromolar canal. Arch. Oral Biol. 1967; 12(11): 1261-8.
- [11]. Reyneke J. P, T sakiris P & Becker P. Age as a factor in the complication rate after removal of unerupted/ impacted third molars at the time of mandibular sagittal split osteotomy. J. Oral Maxillofac. Surg. 2002; 60(6): 654-9.
- [12]. Boronat Lopez A & Penarrocha Diago M. Failure of locoregional anesthesia in dental practice. Review of the literature. Med. Oral Patol. Oral Cir. Bucal. 2006; 11(6): E510-3.

How to cite this article:

Meera Jacob, Ramakrishna Avadhani, Bindhu.S, Rani Nallathamby, Meril Ann Soman. PREVALENCE OF RETROMOLAR FORAMEN IN HUMAN MANDIBLES AND ITS CLINICAL SIGNIFICANCE. Int J Anat Res 2014; 2(3): 553-556.

