

Case Report

BIZARRE CASE OF POLYDACTYLY WITH RIGHT MIRROR FOOT

Saif Omar ^{*1}, Mehre Darakhshan Mehdi ², Provas Benerjee ³.

^{*1} Assistant Professor, Department of Anatomy, Katihar Medical College, Katihar, Bihar, India.

² Assistant Professor, Department of Pharmacology, North Bengal Medical College, Darjeeling, West Bengal, India.

³ Sainthia Nursing Home, Sainthia, Birbhum, West Bengal, India.

ABSTRACT

Mirror foot, a form of polydactyly, is a rare congenital anomaly. In this form of congenital anomaly, there are several additional digits with accessory tarsal bones. It may be associated with fibular dimelia, tibial aplasia and tibial dysplasia. Cause of such anomaly is not known. On experimental basis it appears to involve ectopic SHH (Sonic hedgehog) signaling in the limb bud mesenchyme.

KEYWORDS: Polydactyly, Mutation, Autosomal dominant genes, Mirror foot.

Address for Correspondence: Dr. Saif Omar, Assistant Professor, Department of Anatomy, Katihar Medical College, Katihar 854105, Bihar, India. Mobile No. +919431229999.

E-Mail: drsaifomar@gmail.com

Access this Article online

Quick Response code



Web site: International Journal of Anatomy and Research
ISSN 2321-4287
www.ijmhr.org/ijar.htm

Received: 08 October 2013

Peer Review: 08 October 2013 Published (O):31 May 2014

Accepted: 19 May 2014 Published (P):30 June 2014

INTRODUCTION

Presence of supernumerary digits either on hand or foot is known as polydactyly. Polydactyly has been classified as preaxial, central or post axial depending on location of duplication[1]. Incidence of polydactyly has been reported to be 1 in 1000 live births [2]. Incidence of polydactyly is more in blacks (3.6-13.9 cases per 1000 live births) than in whites (0.3-1.3 cases per 1000 live births)[3]. It may be the result of mutation of autosomal dominant genes[4]. It is also a marker for diabetic embryopathy. In the 1990's it was proposed that preaxial hallucal polydactyly, particularly when proximally placed was a distinguishing feature of diabetic embryopathy [5]. Mirror foot is a rare case of polydactyly which bears several additional digits with accessory tarsal bones [6].

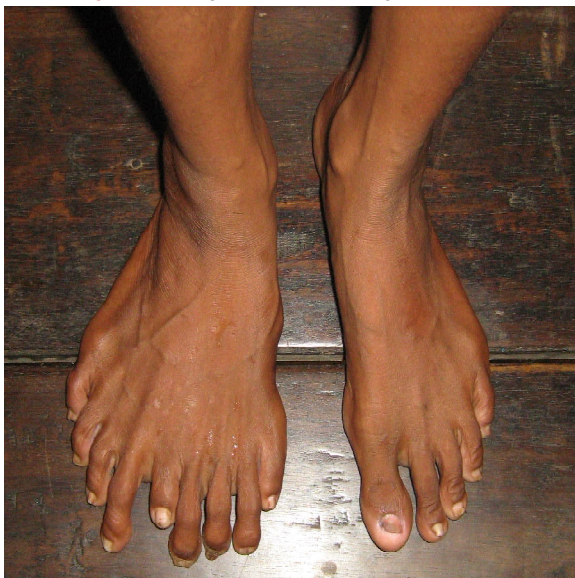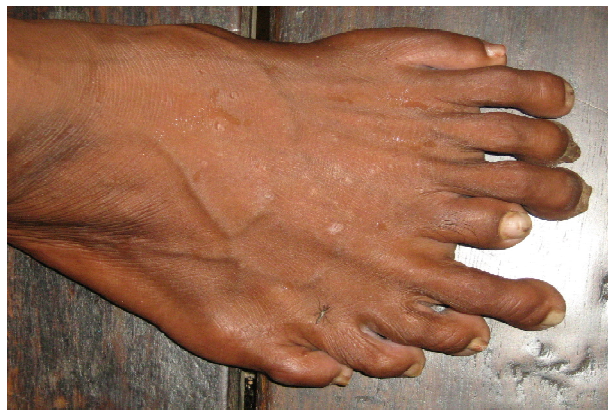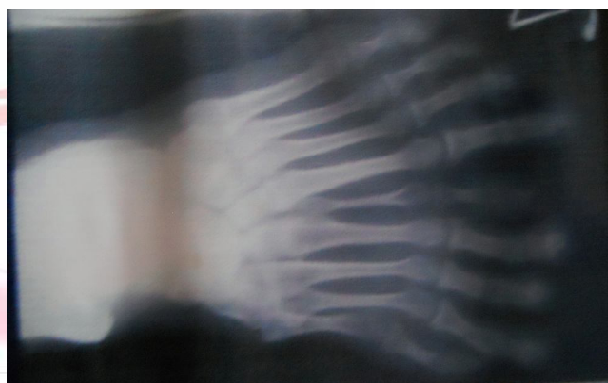
CASE REPORT

A forty year old woman attended Sainthia Nursing Home, in Birbhum district of West Bengal with complaint of pain in her left ankle joint.

On examination a gross congenital deformity was observed in her right foot. There were nine digits instead of five digits and the width of the right foot at the level of the webs of toes was almost twice than that of the left foot. As a case of polydactyly is regarded as hereditary malformation and is usually inherited as an autosomal dominant trait, family history was carefully elicited but was without any positive result.

The left foot revealed no malformations and the pain in the ankle joint may have been due to unnoticed sprain. Radiograph revealed the

following clinical features: 1. Entire right foot is duplicated except the bones of the great toe. 2. Presence of supernumerary digits. 3. Polymetatarsia (nine metatarsals) 4. Polytarsia (five cuneiform bones, one navicular, one cuboid, one talus and one calcaneus). 5. Hyperphalangy (nine proximal phalanges, eight middle phalanges and nine distal phalanges) 6. Cruciate sinus tarsi.

Fig.1: Photograph comparing both feet.**Fig.2:** Photograph of Right Foot.**Fig.3:** Radiograph of Right Foot.

DISCUSSION

Most cases of polydactyly are referred to the orthopedic or plastic surgery departments of medical institutions either for reconstruction or cosmetic surgery. Such cases have been widely reported by surgeons with reference to the results of their respective surgical techniques employed [6,7,8,9]. Cases of mirror foot are extremely rare. According to one estimate less than thirty cases have been reported in literature till now [6]. Limb buds mark their appearance as lateral outgrowths of body wall at about 5mm stage in human embryonic development. Lower limb buds arise a little later than their upper counterpart. Lower limb buds arise from lateral side of trunk just caudal to the level of umbilicus opposite the lumbar and sacral segments of the spinal cord. In the 15mm embryo, the thigh, leg and foot subdivisions become visible. At this stage digits of the foot are not visible but appear as united digital rays. By 20mm stage the digits become separated. Mesenchymal condensations which represent the precursors of the skeletal elements begin to appear in the axial or central core of the limb at 15mm stage and differentiation proceeds in proximodistal direction[10]. As the limb bud is formed the ectoderm along the dorsal tip of the bud is induced by underlying somatopleuric mesoderm to form ridge like thickening at dorsoventral boundary of the limb bud. The thickening is called 'Apical Ectodermal Ridge (AER)'.

AER controls the proximodistal outgrowth of the limb whereas craniocaudal axis is determined by signals from small regions of mesenchyme in the caudal part of the limb bud which is known as 'Zone of Polarising Activity (ZPA)'. Mirror image digit duplications have been experimentally produced by transplantation of ZPA to the cranial portion of limb bud[11]. With advancement of molecular biology techniques a number of gene loci have been identified that are responsible for human polydactyly phenotypes. Genes such as *GLI3* and *SHH* have been found to be related to polydactyly. Mutations in *SHH* genes may be responsible for mirror image digits. Patient did not complain of any difficulty in her life about her right foot but for pain in her left ankle joint. So it appears that there is no clinical manifestation due to this anomaly in the present case. Socioeconomic limitations may have prevented her from taking appropriate measures at an early age.

CONCLUSION

Surgical management of polydactyly of the foot may appear rather simple initially but the multiformity of its configuration needs to be

considered carefully both prior to and during surgical correction. Even in delayed and neglected cases of mirror foot the aim should be to provide reconstruction surgery for cosmetic and functional outcome rather than an amputation.

ACKNOWLEDGEMENT

The corresponding author acknowledges the support and guidance received from Dr. Syed Taha Yasin, Dr. Samar Deb, Dr. Nawal Kishore Pandey, Dr. Vakil Ahmed and Dr. Khurshid Alam.

Conflicts of Interests: None

REFERENCES

- [1]. Temtamy S, McKusick V.A. The genetics of hand malformations with particular emphasis on genetic factors. *Birth defects*, 1969; 14: 364-423.
- [2]. Zun K.H, Kim M.W, Choi H.M. Crossed polydactyly prenatally diagnosed by 2 and 3 dimensional sonography. *J Ultrasound Medicine* 2007; 26: 529-534.
- [3]. Turra S, Gigante C, Bisinella G. Polydactyly of the foot, *J Pediatr Orthop B* 2007; 16: 216-220.
- [4]. Datta A.K. *Essentials of human embryology*, Current books international, 5th Edn, 2005, Page 300.
- [5]. Adam M.P, Hudgins L, Carey J.C, Hall B.D, Coleman K, Gripp K.W, Perez-Aytes A, Graham J.M. *Birth Defects Res A Clin Mol Teratol*, 2009 Jan; 85(1): 13-19.
- [6]. Sudesh P, Kumar V, Jain M, Patel S. Mirror foot and our surgical experience: A case report and literature review. *The Foot* 2010; 20: 44-45.
- [7]. Ishii T, Kawabata H, Kuratsu S, Miki K, Yoshikawa H. Two cases of complete Polytarsia without polydactyly. *Br J Plast Surg* 2005 Mar; 58(2): 267-270.
- [8]. Lim Y, Teoh L.C, Lee E.H. The journal of foot and ankle surgery 2007; 46(2): 86-92.
- [9]. Galois L, Mainard D, Delagoutte J.P. Polydactyly of the foot. Literature review and case presentations. *Acta Orthopaedica Belgica*, 2002; 68(4): 376-380.
- [10]. Kanagasuntheram R, Sivananadasinha P, Krishnamurti A. *A textbook of anatomy*; Orient Longman Ltd., 1996, Page 345.
- [11]. Shoenwolf G.C, Bleyl S.B, Brauer P.R, Francis-West P.H. *Larsen's Human Embryology*, Churchill Livingstone, 4th Edition, 2009, Page 621-632.
- [12]. Dhingra V.S, Kumar A, Mittal A, Gupta S, Singal R, Singh B, Dua C. A rare anomaly of foot presented as polydactyly. *Indian J. Hum Genetics* 2013; 19: 469-471.

How to cite this article:

Saif Omar, Mehre Darakhshan Mehdi, Provas Benerjee. BIZARRE CASE OF POLYDACTYLY WITH RIGHT MIRROR FOOT. *Int J Anat Res* 2014;2(2):333-35.