

## Case Report

# ACCESSORY SPLEEN AND ITS CLINICAL SIGNIFICANCE

Neeta Chhabra<sup>\*1</sup>, Tripti Shrivastava<sup>2</sup>, Lalit Garg<sup>3</sup>, BK Mishra<sup>4</sup>.

<sup>\*1</sup> Assistant Professor, <sup>2</sup> Associate Professor, <sup>3</sup> Tutor, <sup>4</sup> Prof and Head

Department of Anatomy, Army College of Medical Sciences, Delhi Cantt. Delhi-110010, India.

## ABSTRACT

Spleen can have a wide range of anomalies in its shape, location, number and size. They can be congenital and acquired. Accessory spleen is a common congenital anomaly which is usually asymptomatic but might present clinically as an abdominal mass related to complications such as torsion, spontaneous rupture, haemorrhage and cyst formation Knowledge of splenic variations and anomalies is important to avoid diagnostic pitfalls and misinterpretations.

**KEYWORDS:** Accessory spleen, Anomaly, Spleen, Torsion.

**Address for Correspondence:** Dr. Neeta Chhabra, MBBS MD, Assistant Professor Department of Anatomy, Army College of Medical Sciences, Delhi Cantt, Delhi-110010 India.

**E-Mail:** neetachhabra86@gmail.com

## Access this Article online

### Quick Response code



**Web site:** International Journal of Anatomy and Research  
ISSN 2321-4287  
[www.ijmhr.org/ijar.htm](http://www.ijmhr.org/ijar.htm)

Received: 15 Feb 2014

Peer Review: 15 Feb 2014 Published (O):30 April 2014

Accepted: 02 April 2014 Published (P):30 June 2014

## INTRODUCTION

An accessory spleen is a common congenital anomaly which is found in approximately 10% of the normal population at autopsy, 16% of patients undergoing contrast enhanced abdominal CT and with a higher frequency in patients with hematologic disease. It is a small nodule of splenic tissue found apart from the main body of the spleen. It is an anomaly which is due to developmental abnormalities of embryo [1,2,3].

The most common cause of their formation is an incomplete fusion of mesenchymal buds and trauma. An accessory spleen may be pulled by splenic ligaments to ectopic locations. They are always located on the left side of the abdomen due to rotation of the spleen during embryogenesis. The sites where an accessory spleen is commonly found is the hilum of the spleen in 75% of cases and near the tail of pancreas in 20%.The other sites are gastrosplenic or lienorenal ligaments, walls of stomach or

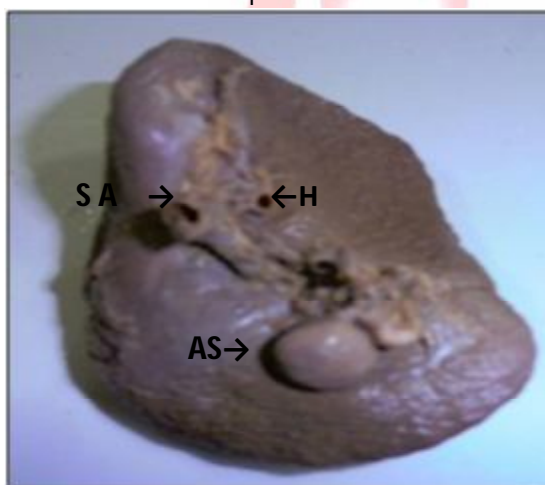
intestines, greater omentum or mesentery or even in the pelvis and scrotum. Morphologically and functionally they are similar to the normal spleen and receive their vascular supply from branches of splenic artery [2,4].

The identification of an accessory spleen is important because it may mimic lymphadenopathy or a tumor in the pancreas, adrenal gland, or kidney. In addition, it can occasionally cause symptoms due to torsion, haemorrhage, spontaneous rupture, or cyst formation [5]. It is important for the surgeons to recognize accessory spleens at the time of splenectomy because if they are left behind they will undergo hyperplasia and cause recurrence of disease [6]. Accessory spleen and splenic lobulation can be misinterpreted as neoplasm by endoscopic ultrasound. Although homogenous they can be hyperechoic or hypoechoic. Their sharp regular outer margin and anatomic location may help to avoid misdiagnosis [7].

## CASE REPORT

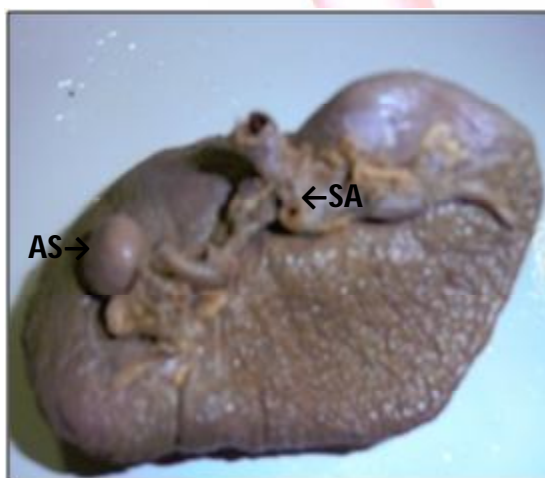
During routine cadaveric dissection classes for undergraduate medical students in the Anatomy Department of ACMS Delhi Cantt we came across a small accessory spleen in an embalmed male cadaver of approximately 60 yrs of age. It was present near the hilum of the spleen and was round in shape. (Fig 1). The measurements were length 10 mm, breadth 07mm and depth 08mm. It was similar in texture and color to the main spleen and was receiving blood supply from small branches of splenic artery. (Fig 2).

**Fig 1:** Showing accessory spleen near the hilum of the spleen.



AS: ACCESSORY SPLEEN SA: SPLENIC ARTERY H: HILUM

**Fig 2:** Showing splenic artery supplying branches to accessory spleen.



AS: ACCESSORY SPLEEN SA: SPLENIC ARTERY

## DISCUSSION

The spleen consists of a large encapsulated mass of vascular and lymphoid tissue situated in the upper left quadrant of the abdominal cavity between the fundus of the stomach and the diaphragm [8]. It contacts the posterior wall of

the stomach and is connected to the greater curvature by the gastrosplenic ligament and to the left kidney by the splenorenal ligament [9]. The spleen appears at approximately the sixth week of embryologic life as a localized thickening of the coelomic epithelium of the dorsal mesogastrium near its cranial end. The proliferating cells invade the underlying angiogenetic mesenchyme, which becomes condensed and vascularized. The process occurs simultaneously in several adjoining areas, which soon fuse to form a lobulated spleen. In the subsequent periods of embryologic life, the earlier lobulated character of the spleen disappears but is indicated by the presence of notches on its upper border in the adult. The spleen can display various developmental anomalies, including complete agenesis, multiple spleens or polysplenia, isolated small additional splenunculi, and persistent lobulation [8].

Ectopic splenic tissue can be found in body in two distinct types: accessory spleen and splenosis. Accessory spleens are congenital and arise from the left side of dorsal mesogastrium during the embryological period of development [10]. They can be solitary or multiple but are seldom more than six [2]. Characteristically, they are smooth with a round or oval shape and are about 1.0-1.5cm in diameter [11]. In 85% of cases there is one accessory spleen, in 14% there are two, in 1% three or more accessory spleens have been found. Splenosis, on the other hand is an acquired condition which occurs when the splenic tissue is auto transplanted through surgical intervention or traumatic rupture of spleen having incidence of 67% in these patients. It presents as numerous nodules (as many as 400) in any intraperitoneal or extraperitoneal location. Splenosis nodules receive their blood supply from newly formed arteries penetrating the capsule [10].

Histologically it is possible to differentiate accessory spleen from splenosis. Accessory spleens have well defined capsule, hilum, trabeculae, white pulp with malpighian follicles having central arteriole and red pulp. Splenosis nodules are also surrounded by capsule but malpighian follicles and central arteriole are not formed [6]. An accessory spleen is approximately 1 cm in diameter but vary from microscopic

deposits which are not visible on CT to 2-3cm in diameter [9]. Most of the accessory spleens are asymptomatic and are discovered incidentally by abdominal ultrasound, CT scan or laparotomy during the investigation of some other problem. Rarely do they become symptomatic due to complications such as torsion with infarction, rupture or infection [6].

Awareness of the presence of an accessory spleen is important in a patient evaluated by CT prior to splenectomy, as failure to remove it may result in persistence of the condition for which splenectomy has been done [12]. An accessory spleen resembles normal spleen in structure and in immunological function so in splenectomy for non haematologic causes as in rupture of a primary spleen it may be a source of preservable splenic tissue.

### CONCLUSION

Knowledge of variational anatomy of spleen is of fundamental importance to surgeons while they perform surgical operations which are related to the spleen, to the radiologists during diagnostic procedures to prevent interpretation errors in diagnostic imaging and very important for anatomists during routine cadaveric dissections.

**Conflicts of Interests: None**

### REFERENCES

- [1]. Pushpalatha M, Sujana M, Sharmada K L. Accessory Spleen –a case report. *Int J Cur ResRev*.2012 Nov;4(1):121-2.
- [2]. B Calin, BN Sebastin, B Vasile, O Andrea. Lost and found: the accessory spleen. *Med Con*.2012 June;2(26):63-6.
- [3]. Batista et al. Accessory spleen detection at laparoscopic splenectomy is adequate for immune thrombocytopenic purpura- a prospective study. *Bras J Video- Surg*. 2008;1(4):156-162.
- [4]. Impellizzeri et al. Accessory spleen torsion: a rare cause of acute abdomen in children: a review.2009 Sep;44(9):e15-18.
- [5]. Gayer G, Zissin R, Apter S, Atar E, Portnoy O, Itzchak Y. CT findings in congenital anomalies of the spleen. *Br J Radiol*.2001 Aug;74(884):767-2.
- [6]. H Amanjit, Bhardwaj S, Handa U. Splenunculi-report of three cases. *J Anat Soc India*. 2002; 51(1):70-71
- [7]. Barawi M, Bekal P, Gress F. Accessory spleen: a potential cause of misdiagnosis at EUS Gastrointest Endosc.2000 Dec;52(6):769-72.

- [8]. Standring SM (ed.) 2005. *Gray's Anatomy*. 39th ed. New York: Churchill Livingstone. p1239,1267.
- [9]. Moore KL. *Clinically Oriented Anatomy*. 3rd ed. Baltimore: Williams & Wilkins 1992; 185-7.
- [10]. Richard D, Rice WT, Fremont, MD. Splenosis: a review. *South Med J*.2007;100(6): 589 -93.
- [11]. Dodds WJ, Taylor AJ, Erickson SJ, Stewart ET, Lawson TL. Radiologic imaging of splenic anomalies. *Am J Roentgenol*.1990;155:805–10.
- [12]. Unver Dogan N, Uysal II, Demirci S, Dogan KH, Kolcu G. Accessory spleens at autopsy. *Clini Anat*.2011 Sep;24(6):757-62.

### How to cite this article:

Neeta Chhabra, Tripti Shrivastava, Lalit Garg, BK Mishra. ACCESSORY SPLEEN AND ITS CLINICAL SIGNIFICANCE : A CASE REPORT. *Int J Anat Res* 2014;2(2):325-27.