

Cone Beam Computed Tomography: A Diagnostic Boon in Dentistry

Ruchika Khanna¹, Ruchit Khanna², P. M. L. Khanna³

¹Department of Oral Medicine and Radiology, Ramnagar, Banur, Patiala, Punjab, India, ²Resident, Department of Pharmacology, Maharishi Markandeshwar University, Mulana, Ambala, ³Prof & HOD, Department of Pharmacology, Gian Sagar Medical College & Hospital, Ramnagar, Banur, Patiala, Punjab, India

ABSTRACT

Cone beam computed tomography is a three-dimensional imaging modality and more accurate when compared to digital radiographs. The recent advancement in this technology has reduced the cost as well as the dose to the patients. The advanced software design and powerful computer system have permitted its use in dentistry. Its varied indications in practically all the branches of dentistry have made this progress all the more versatile. Through this review we have tried to highlight the basis of this technology, its advantages and applications, wherefore proving it to have an edge over the others.

Key words: Computed tomography, cone beam, imaging

INTRODUCTION

Imaging has a precious role to play in the clinical diagnosis and assessment of a dental patient. Almost all the imaging techniques used earlier that is in and around 1960's, 1970's and 1980's suffered from the same limitation of magnification, distortion, superimposition, and misrepresentation of structures as they were all two-dimensional (2D) images. We have witnessed the introduction of three-dimensional (3D) imaging modalities in the form of computed tomography (CT) and magnetic resonance imaging technologies that have had a splendid influence in the field dentistry. The image selection rationale for several areas of head and neck region has been given by (American Academy of Oral and Maxillofacial

Radiology).^[1,2] The fundamental element of radiology is exposure of the patients and most likely the clinical staff to X-rays. Any exposure to X-rays is risky, so the dentists should follow all measures to ensure protection. Dentists usually use radiology to a reasonably greater amount on children and young adults and hence the need for wise use is of prime importance. The advent of cone beam CT (CBCT) has been extensive advancement in dental imaging. Numerous efforts for 3D radiographic imaging (e.g. stereoscopy, tuned aperture CT) have been made, but its use in dentistry has become limited due to dose factors, access, and cost.^[3] CBCT generates 3D images to guide diagnosis, treatment, and follow-up.^[4] It has created a revolution in the field of dentistry by enabling the transition of radiology from 2D to 3D.^[3] Sir Godfrey Hounsfield introduced CT in 1967, and there has been a steady progress to what is currently in use today.

TYPES OF CT SCANNERS

Two types of beam used in CT are the fan beam and cone beam. In fan-beam scanners, the X-ray source

Access this article online	
Publisher 	Website: http://www.renupublishers.com
	DOI: ***

Address for correspondence:

Dr. (Maj) Ruchit Khanna, Resident, Department of Pharmacology, Maharishi Markandeshwar Institute of Medical Sciences and Research, Mullana, Ambala. (Haryana) India. Email- dr_ruchitkhanna@hotmail.com

Submission: 02 Aug 2014; **Revision:** 18 Aug 2014; **Acceptance:** 22 Aug 2014

and solid-state detector are mounted on a rotating gantry. Acquisition of data is by a narrow fan-shaped beam.^[5] In the axial plane, the image obtained is in the form of slices, and the interpretation is done by stacking the slices in 2D representation. The linear array detector elements used in conventional helical fan-beam CT scanners are in reality a multi-detector array. This configuration allows multi-detector CT scanners 64 slices acquisition simultaneously, which greatly reduces the scanning time when compared to single-slice systems and thus allows generation of 3D images at considerably lower doses of radiation than single detector fan-beam CT arrays.^[5]

IMAGE PRODUCTION

Scanning of image is done in three positions: (1) Sitting (2) standing (3) supine. Out of the three the sitting position is the most comfortable position.

Four main steps in the acquisition of a CBCT image are:

1. Acquisition configuration
2. Image detection
3. Image reconstruction
4. Image display.

Acquisition Configuration

- i. X-ray generation: Usage of the pulsed system of generation for reduction in exposure dose compared to continuous radiation.
- ii. Field of view (FOV): Based on the shape and size of the detector, projection geometry and ability to collimate the beam. Cylindrical/spherical shape may be present. FOV for a localized region is around 5 cm or less, for single arch 5-10 cm, for interarch 7-10 cm, maxillofacial - 10-15 cm and craniofacial >15 cm.
- iii. Scan factors: During the scanning procedure, single exposures are usually made at certain degree intervals, providing individual 2D projection images, called as raw images. As low as reasonably achievable principle should be followed.
- iv. Frame rate and speed of rotation: Higher frame rate produces better image quality.^[6]
- v. Completeness of the trajectory arc: A complete scan of 360° is required to acquire the projection data.

Image Detection

Based on detector type CBCT units are divided into two types:

1. An image intensifier tube/charge-coupled device (IIT/CCD) combination
2. A flat-panel imager.

The IIT/CCD configuration comprises an X-ray IIT coupled to a CCD by way of a fiber optic coupling. Flat-panel imaging consists of detection of X-rays using an “indirect” detector based on a large-area solid-state sensor panel coupled to an X-ray scintillator layer.^[3]

Image Reconstruction

Processing of data occurs after acquiring the projection frames. The individual frames vary from 100 to 600 each with more than one million pixels with 12-16 bits assigned to each pixel. One computer acquires the data and then transferred to the other computer (workstation). The image reconstruction requires two stages [Figure 1]:

1. Acquisition stage
2. Reconstruction stage.

Image Display

Assembling of all the voxels is accorded to the clinician in three planes (axial, sagittal and coronal).

ADVANTAGES AND DISADVANTAGES OF CBCT

Advantages	Disadvantages
X-ray beam limitation	Low contrast resolution which is 14 bit whereas for accurate reading 24 bit is desired
Image accuracy	Streaking artifacts due to metal restorations
Rapid scan time	
Dose reduction up to 98%	
Display modes unique to maxillofacial imaging	

APPLICATIONS IN DENTISTRY

In Endodontics

- a. Evaluation of coronal micro-leakage, root canal therapy
- b. Evaluation of obturation

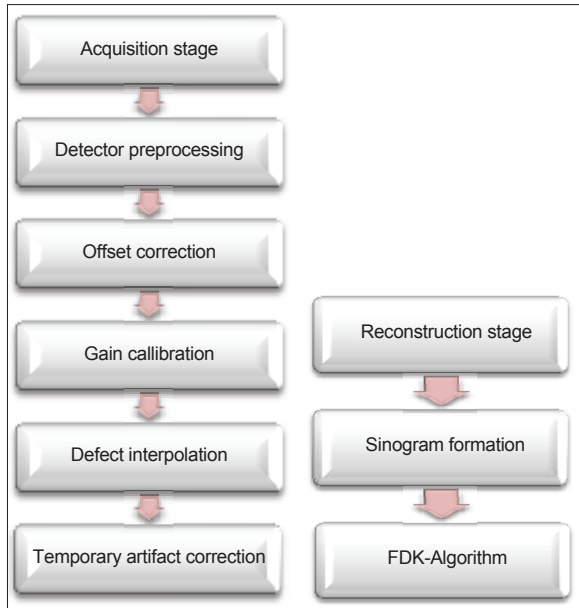


Figure 1: Acquisition and reconstruction stage

- c. Evaluation of bony lesions
- d. Evaluation of root canal morphology.

In Oral and Maxillofacial Surgery

1. Identification of some facial anatomical features
2. Safe and optimal removal or transplantation of impacted wisdom teeth
3. Localization of impacted canines
4. Locate root position and proximity of impacted third molars to the inferior alveolar nerve
5. Locate infra-orbital artery.

In Orthodontics

Single CBCT scan efficiently produces all the images needed for the diagnosis including the lateral cephalograph, the panoramic radiograph, and the antero-posterior cephalogram.

CBCT ensures measurement accuracy, comparisons between 2D and 3D images for diagnosis and treatment planning.

Serial CBCT scans can also measure and quantify volumetric changes of craniofacial structures using superimposition techniques.

ASSESSMENT OF OCCLUSAL PATTERN AND CONDYLAR POSITIONS

Dental Implants

1. Exact implant position planning
2. Aids in sinus lift procedures
3. Anatomical variations of the alveolar nerve
4. Intra-alveolar distraction osteogenesis
5. Reduced vertical bone height.
6. Preparation of templates
7. Reduced horizontal bone width.

CONCLUSION

A review of the literature available till date shows that CBCT has an important role in the diagnosis and treatment planning of a disease. We can say for sure that if used rationally it would outweigh its inherent risks. Hence, we conclude by saying that various clinical trials and evidence-based studies is the need of the hour that will favor its application in dentistry.

REFERENCES

1. Miracle AC, Mukherji SK. Conebeam CT of the head and neck, part 2: Clinical applications. *AJNR Am J Neuroradiol* 2009;30:1285-92.
2. White SC, Heslop EW, Hollender LG, Mosier KM, Ruprecht A, ShROUT MK, *et al.* Parameters of radiologic care: An official report of the American Academy of Oral and Maxillofacial Radiology. *Oral Surg Oral Med Oral Pathol Oral Radiol Endod* 2001;91:498-511.
3. Scarfe WC, Farman AG. What is cone-beam CT and how does it work? *Dent Clin North Am* 2008;52:707-30.
4. Alamri HM, Sadrameli M, Alshalhoob MA, Sadrameli M, Alshehri MA. Applications of CBCT in dental practice: A review of the literature. *Gen Dent* 2012;60:390-400.
5. Scarfe WC, Farman AG, Sukovic P. Clinical applications of cone-beam computed tomography in dental practice. *J Can Dent Assoc* 2006;72:75-80.
6. Grangeat P. Mathematical framework of cone beam 3D reconstruction via the first derivate of the radon transform. In: Herman GT, Luis AK, Natterer F, editors. *Mathematical Methods in Tomography*. Vol. 1497. Berlin, Germany: Springer Verlag; 1991. p. 66-97.

How to cite this article: Khanna R, Khanna R, Khanna PML. Cone Beam Computed Tomography: A Diagnostic Boon in Dentistry. *Int J Dent Med Spec* 2014;1(1):18-20.

Source of Support: None; **Conflict of Interest:** None