

## **Managing the Challenge of Sports Related Dental Injuries in Athletic Children- A Case Report**

**Verma, L. Assistant Professor, Dr. H.S. Judge Dental College, Punjab University, Chandigarh**

email: drleenaverma32@rediffmail.com

### **Abstract**

Sports related injuries are the most common cause of dental trauma in children. The most commonly injured teeth are the maxillary central incisors, followed by the maxillary lateral incisors and the mandibular incisors. Presented here is a case of a 13 year hockey player who met with a sports injury and reported to the dental clinic with the chief complaint of broken upper left central incisor. The treatment was carried out by doing Root canal treatment of the broken tooth followed by the crowning of the fractured tooth with porcelain fused to metal. The goal of present paper was to help develop dental trauma management awareness in sportspersons which can help deal with everyday teeth trauma in most appropriate way.

**Key words: Sports injury, porcelain fused to metal, dental trauma**

### **Introduction**

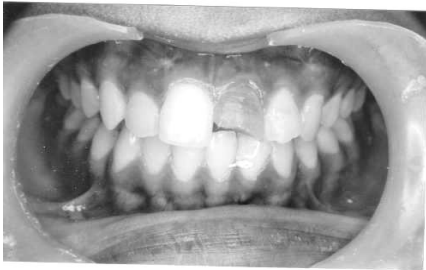
It has been widely reported that participation in sports carries a considerable risk of sustaining dental injury [Davies & Bradley, 1977; Sane & Ylipaavalnimei, 1988; Flanders & Bhat, 1995 and Rodd & Chesham, 1997]. Contact sports are defined as those sports in which players physically interact with each other, trying to prevent the opposing team or person from winning [Rodd & Chesham, 1998]. A considerable number of papers have appeared in the dental literature highlighting the dangers of participation in such sporting activities, in particular 'stick' sports such as lacrosse, and field and ice hockey [Sane & Ylipaavalnimei, 1988 and Rodd & Chesham, 1997]. In addition, competitive matches have been shown to be far more hazardous than training sessions. Highly significant differences have been shown to exist between the number of teeth injured and the causes of injury [Sane & Ylipaavalnimei, 1988]. For example, a blow or kick from another player most

often causes injury to one tooth, while a fall or blow from a hard object often results in injury to two teeth. The prompt and appropriate management of traumatic dental injury is an important determinant of the prognosis of the involved tooth. The lack of knowledge of the appropriate handling sequence often has detrimental effect. Dental injuries can be classified by etiology, anatomy, pathology or therapeutic considerations with extrusion, intrusion and tooth avulsion being the most frequent types of dental trauma that we see in the dental office. The transport and care of the affected tooth, the prompt and adequate treatment in the dental office, as well as the proper follow up are imperative for a successful outcome of these incidents. The goal of present paper is to help develop dental trauma management awareness in sportspersons which can help deal with everyday teeth trauma in most appropriate way.

### *Case Report*

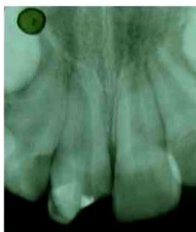A 13 year old young hockey player reported to the dental clinic with a chief

complaint of broken upper front tooth following trauma due to a blow from the other player while playing hockey. No apparent trauma to the soft tissues in the intraoral and extraoral examination was noted. The patient gave a history of trauma to upper front tooth 7 days ago. Neither the child nor the parent sought immediate dental treatment after the trauma. Her medical and dental history was unremarkable. Clinical and radiographic examinations were conducted. Clinical examination revealed a fracture in the middle third of the crown of the maxillary left central incisor, exposing the pulp (Figure 1).



**Figure 1:** Fractured left central incisor (Pre-Operative)

The tooth showed negative response to cold and electric pulp sensibility tests. There was no mobility or displacement. The remaining maxillary and mandibular anterior teeth were intact. Periapical radiograph was taken which confirmed pulpal involvement. The apex was fully formed and there was no associated root fracture or periapical pathology. (Figure 2)



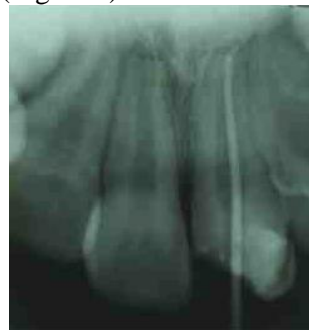**Figure 2:** Preoperative IOPA X-ray

The treatment plan was divided into 3 steps:-

- Step 1- Endodontic phase
- Step 2- Construction of the restoration phase
- Step -3: Crown cutting of the restored tooth

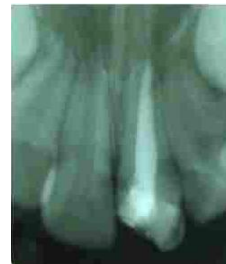*Step 1: The Endodontic Phase*

An infraorbital block was administered for 11, 12. The pulp chamber was opened using no. 330 round carbide steel bur & working length determination IOPA was taken with a no. 10 K-file (Figure 3).



**Figure 3:** IOPA showing working length x-ray

The pulp tissue was extirpated using no. 10 – no. 60 K-files. After irrigation with copious amounts of 2.5% NaOCl & Normal Saline, the root canal was dried using paper points. A thin mix of Zinc oxide eugenol paste was mixed and G.P points were coated with Zinc oxide eugenol paste and filled in the canal (Figure 4).

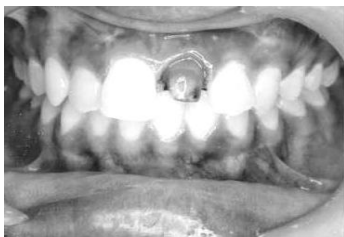

**Figure 4:** IOPA showing obturation of maxillary left central incisor

*Step -2: Construction of restoration Phase*

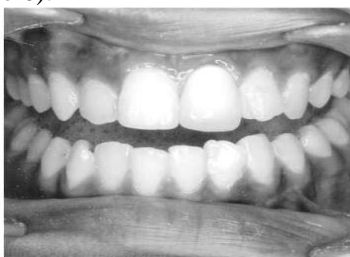After the root canal treatment the coronal enamel was then etched for 20 seconds, rinsed with water & air dried followed by application of bonding agent – which was then light cured. The coronal enamel was then covered with the hybrid composite for core build –up, followed by light curing it for 60 seconds. The final finishing & polishing was done with finishing burs.

*Step -3: Crown cutting of the restored tooth Phase*



**Figure 5: Crown cutting of tooth done (Operative)**

After root canal treatment and composite build up of the fractured tooth, crown cutting of the teeth was done as shown in (Figure 5). After the crown cutting impression was taken and sent to the laboratory for the processing of Porcelain fused to metal crown. The crown was fixed with the help of luting cement i.e GIC TYPE 1 as shown in the (Figure 6).



**Figure 6: Crown on Fractured Incisor Given (Post – Operative)**

Dental injuries are a major problem for the players from the pain, aesthetic and economics stand point of view. The athletes have to go through many procedures to get the whole thing corrected which leads to the wastage of their valuable time and money. Sports related injuries can become expensive depending on the nature and extent of trauma. Dental injuries incurred during sports activities are highly treatable, and can involve good outcomes if participants act quickly to see a dentist after an injury event. However, if not treated quickly these kinds of injuries can lead to discomfort, embarrassment and a lifetime of dental costs. The best medicine is, of course, prevention. If one is involved in a contact sport, wearing of the proper protective equipment, particularly a mouthguard is strongly recommended. If it is economically feasible, have a custom-fit mouthguard made especially for the sportsman. Eat properly and well, refrain from smokeless and all tobacco products and drugs. Taking these steps can help avoid injury and focus attention on enjoying your sports. Sports injuries to the mouth and oral tissues are not necessarily treated any differently than other traumatic injuries to the oral tissues. There are various treatment options in sports related injuries like direct composite veneers, removable partial dentures, dental crowns, replantation of the avulsed tooth. The present case report, discusses the sports related dental injury to the anterior teeth and its treatment.

*Conclusions*

Dental injuries are common incidents and timely and suitable management of these occurrences is crucial for the prospects of the involved tooth. Although

different entities require different treatment approaches, it is paramount to determine the time frame of the incident, the vitality of the affected tooth, as well as set up a proper follow up scenario. Dentist should have readily available a case-scenario protocol which can help deal with teeth trauma in most fitting way.

## References

- Davies, R, Bradley, D. 1997. The prevalence of dental injuries in rugby players and their attitude to mouthguards. *Brit. J. Sports Med.*, **11**: 72–74.
- Dorney, B. 1998. Dental screening for rugby players in New South Wales, Australia. *FDI World*, **7**: 10–13
- Flanders, R., Bhat M. 1995. The incidence of orofacial injuries in sports: a pilot study in Illinois. *J. Am. Dental Asso.*, **126** : 491–496.
- Rodd, H., Chesham, D. 1997. Sports-related oral injury and mouthguard use among Sheffield school children. *Community Dental Health*, **14** : 25–30.
- Sae-Lim, V, Lim, L.P. 2001. Dental trauma management awareness of Singapore pre-school teachers. *Dental Traumatol.*, **17**:71-76.
- Sane, J., Ylipaavalnime, P. 1988. Dental trauma in contact team sports. *Endod. Dental Traumat.*, **4**: 164–169.

