

Rotator Cuff Lesions: A Case Report

Khurana¹, N., Hanspal¹, S.S. and Singh², G.

¹Clinical Therapist, Banarsidas Chandiwala Institute of Physiotherapy, Chandiwala Estate, Maa Anandmai Marg, Kalkaji, New Delhi 110019.

²MPT Final year Student, Banarsidas Chandiwala Institute Of Physiotherapy, Chandiwala Estate, Maa Anandmai Marg, Kalkaji, New Delhi 110019.

Abstract

Objective: To describe the evaluation, management, and rehabilitation of a multifactorial rotator cuff lesion in an elderly female. **Background:** The reported onset of pain was gradual. No history of fall or trauma. Pain was present on anterolateral aspect of left shoulder. Pain was sharp and deep on abduction and flexion of the left shoulder and reported a VAS of 9.5/10. **Treatment:** The patient was managed conservatively with steroid injections and physiotherapy. The patient underwent a 2-month rehabilitation protocol in preparation for return to normal daily activities.

Uniqueness: This case involved an elderly female who sustained a multiple causative factors for rotator cuff lesions. **Conclusions:** By presenting this case report, we hope a better understanding of rotator cuff lesions and how to successfully manage and rehabilitate.

Key Words: Rotator Cuff Lesion, Elderly, Shoulder Impingement, Calcification, Physiotherapy.

Introduction

Shoulder pain is a common musculoskeletal complaint in the general population. The elderly population is often afflicted, and rotator cuff problems are among the most common causes of shoulder pain seen in primary care practices. The prevalence of shoulder pain in the elderly has been estimated to range from 21% to 27%, and the prevalence of rotator cuff tear increases with advanced age. The etiology of rotator cuff disease is likely multifactorial, including both extrinsic and intrinsic factors. Rotator cuff dysfunction encompasses a spectrum of pathological changes, ranging from impingement syndrome to rotator cuff tendonitis to rotator cuff tendon tear. In the elderly population, the clinical manifestations from rotator cuff dysfunction can translate into significant morbidity and disabilities, interfering with ability for self care and functional independence. The goals of managing rotator cuff disease are to regain normal

shoulder function and biomechanics, and to improve functional abilities in elderly patients (*Lin et al, 1972*). *Neer (1972)* first introduced the concept of rotator cuff impingement to the literature, stating that it resulted from mechanical impingement of the rotator cuff tendon beneath the anteroinferior portion of the acromion, especially when the shoulder is placed in the forward-flexed and internally rotated position. He reported that about 90% of rotator cuff tears are a result of subacromial impingement from supraspinatus outlet narrowing.

There is also an association of rotator cuff disease with abnormal acromions (*Cofield, 1985*). Changes in the bone or ligament can cause decreased space for the cuff or abnormal biomechanics. There is also controversy regarding whether subacromial spurs cause rotator cuff disease or whether these are secondary changes caused by a poorly functioning cuff. Several studies have found a strong association between aging, cuff tears, and altered acromial contours. The most

common change in contour is an acromial hook that lies within the coracoacromial ligament. This change most likely is caused by rotator cuff disease. As the rotator cuff degenerates, the cuff no longer can fulfill its role of providing superior stability and acting as a spacer. The shoulder relies on the coracoacromial arch for stability, and an increase load is placed on the coracoacromial ligament.

Partial rotator cuff tears, especially tears in the older population, have a limited ability to heal because of several factors (*Kazemi, 1999*). One is that the torn tendon is under tension during activity as the cuff contracts and at rest because of the weight of the arm and the role of the cuff to compress the humeral head into the glenoid. This tension causes a relative avascularity around the edges of the tear and causes the ends to retract, which does not allow approximation for healing. In addition, the torn ends of the tendons, especially the distal margins, often develop neovascular tissue that causes resorption of the tendon fibers, and without closure of the defect, healing does not occur. Another factor is that the torn cuff is bathed in synovial fluid, which disrupts some of the normal healing factors, such as a fibrin clot. A final, and perhaps most important, factor is that tendon tears in older patients generally occur because of tendon degeneration.

Calcifying tendinitis of the rotator cuff is a common condition in middle aged individuals (*Chiou et al, 2002, Jacobs & Debeer, 2006*). This condition affects 2.7% to 20% of the population, mostly aged between 30 and 50 years. Women are more frequently affected than men. Only a few of them have clinical symptoms. Hydroxyapatite is formed by fibrocartilage cells in the tendon

following an unknown stimulus. Subsequently, depending on the disease phase, pain and limitation of motion can occur. *Uthoff and Loehr (1997)* believe that calcifying tendinitis progresses through correlating pathological and clinical stages. During the formative phase, a portion of the tendon undergoes fibrocartilaginous transformation, and calcification occurs in this transformed tissue. Once formed, the calcific deposit enters a resting period (resting phase). The calcific deposit may or may not be painful. If large enough, it may cause mechanical symptoms. After a variable period, an inflammatory reaction may ensue. Vascular tissue develops at the periphery of the deposit. Macrophages and multinuclear giant cells absorb the deposit during this resorptive phase. Occasionally, it leaks into the subacromial bursa. This stage may be very painful. Once the calcific deposit has been resorbed, fibroblasts reconstitute the collagen pattern of the tendon in the postcalcific phase.

Case Report

A 63-year-old female presented with left shoulder pain since 8 months. The reported onset was gradual. No history of fall or trauma. Pain was present on anterolateral aspect of left shoulder. Pain was sharp and deep on abduction and flexion of the left shoulder. Patient reported a VAS of 9.5/10. SPADI (Shoulder Pain and Disability Index) (Speed CA) score of 110/130. It was aggravated by lying on the shoulder, reaching and lifting with the left arm. Pain was relieved by medications and keeping shoulder adducted. Previous treatment received included medications (Cartigen, T. Dolocide, Idrofos and Calcium

supplements) along with physiotherapy (Hot packs, Ultrasound and ROM exercises including pulleys, wheel and ladder) (Will, 2005) for 4 weeks, but patient complained of increase pain. She further consulted the orthopaedic surgeon; medications were changed to T.Nucoxia, T.Ultracet and Pantop-D. Physiotherapy included hot packs for 15-20 minutes, 2- (Cofeild, 1985) times daily. Along with this she also took one week of Acupuncture (Hing, 2005) in August 2010. Continuing to have pain and left shoulder movement restriction, she consulted her surgeon who injected her with cortisone twice (one in November 2010 & the other in December 2010) in her left shoulder and recommended light exercises. One month prior to presenting to the author's office patient felt 50% better only in terms of pain relief but there was no increase in range of motion at the left shoulder. At this time the patient presented to the author's clinic with dull and achy pain in the left shoulder and with a sharp pain to the posterior and anterolateral left arm. She complained of not being able to move her left arm and having a hard time dressing and washing herself. The pain was aggravated by any movement of the left arm, lying on the left arm and she was awakened at night when she rolled onto the affected arm. The pain was slightly relieved by taking hot fomentation. Patient has a medical history of hypertension and hypothyroidism and diabetes mellitus but was under control with medications. Hematological tests revealed normal uric acid level. Family history was unremarkable.

On examination, upper extremity deep tendon reflexes were normal bilaterally and light touch sensation examination was unremarkable. Cervical

spine bilateral lateral flexion bilateral rotation and flexion were full and pain free. However, the left shoulder pain could not be reproduced by the neck examinations (i.e. range of motion, soft tissue palpation, Spurling's, Jackson's and maximal compression tests). Her active left glenohumeral ROM was; flexion 0 - 80°, abduction 0 - 45°, external rotation 0-10° and internal rotation 0 -20°. The left glenohumeral joint passive ROM was 5 degrees more in each direction. Posterior and posteroinferior glide restricted and painful. The resisted left glenohumeral joint flexion, abduction, internal and external rotations were graded 3/5. Her left deltoid, infraspinatus, supraspinatus and teres muscles were spasmodic and tender upon palpation. There was severe point tenderness over the left deltoid tuberosity and the rotator cuff. Special tests such as painful arc (pain and weakness between 60-120 degrees shoulder abduction), Empty can test (Barr, 2004), Hawkins Kennedy impingement test (Barr, 2004) was positive and Drop arm test was negative.

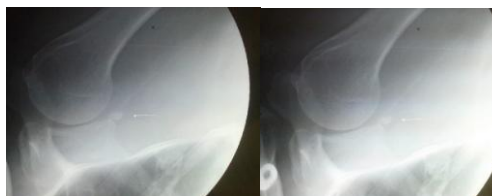

Figure :1(X Ray Left Shoulder)

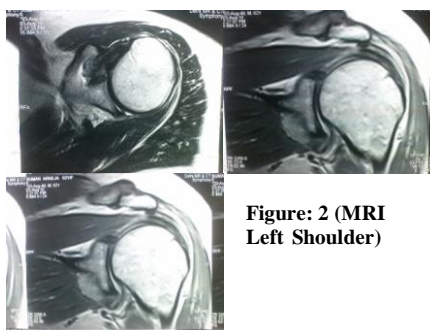


Figure: 2 (MRI Left Shoulder)

Radiographs of the right shoulder revealed reduced glenohumeral joint space, calcific (calcium hydroxyapatite deposition) density near inferior angle of glenoid (figure1). MRI revealed acromioclavicular osteoarthritic changes with laterally downsloping acromion with acromial osteophyte impinging on to supraspinatus tendinosis with subacromial and subdeltoid bursitis. A clinical diagnosis of the left multiple cuff lesions were made (figure 2).

Initial treatment consisted of Ultra – Riez current therapy (*Charlusz et al, 2005; Shaw et al, 2010*), hot packs, anteroposterior and long axis distraction mobilization, sustained capsular stretches, Anteroposterior glenohumeral glides, Grade 3 Kaltenborne mobilization technique for increasing the ROM and Grade 1 & 2 for pain relief, active as well as active assisted exercises, we also used suspension therapy to reduce the pain along with pendular home exercises (*Nitz, 1986*) for the left shoulder were done. The patient came regularly for 6 weeks and a considerable improvement in range was appreciated but pain was still present. At the end of the sixth week, the active left glenohumeral (initial range in brackets) abduction, flexion and external rotation were 105(80), 90(45) and 15(10) degrees respectively and the passive ROM showed even more improvements where the passive abduction, flexion and external rotation were 95, 110 and 20 degrees respectively. After 6 weeks, strengthening exercises using 0.5 kg dumbbells in all planes of glenohumeral ROM were introduced along with multiangle isometrics and scapular strengthening exercise .Even though considerable improvement in range was

appreciated, pain was still present and the patient was referred back to the orthopaedic surgeon and third intra-articular injection (Hing, 2005) in March 2011 was given, after which the physiotherapy treatment was discontinued for 10 days. After 10 days there was considerable pain relief (85%) was achieved and physiotherapy was restarted with hot packs, gentle mobilization, active assisted exercises with bar, pulley, finger ladder and strengthening of shoulder muscles with 1 kg dumbbells. Patient's range of motion, strength and pain were markedly improved after the rehabilitation. There was a marked improvement in pain as well as the glenohumeral range of motion at the left shoulder with flexion ROM was 160 degrees, abduction 140 degrees, external rotation 60 degrees and internal rotation 80 degrees. Patient now reported a VAS of 0/10. SPADI of 23/130, Muscle strength also improved and the muscle were graded at 4/5. The patient could perform all her activities of daily living with ease and minimal pain. In addition, the left glenohumeral joint long axis distraction, anteroposterior and posteroinferior manual high speed low amplitude manipulation, capsular stretches and tender point therapy over the hypertonic and tender muscles (lateral deltoid, supraspinatus and infraspinatus muscles) were started. Tender point therapy was utilized by exerting digital compressive pressure over the tender points palpated in the involved muscles. This pressure was gauged to the patient's tolerance and was sustained until the patient reported the dissipation of the pain. At the end of this course of treatment, the patient's left glenohumeral active abduction was 140 degrees and her

flexion and external rotation were nearing end range. The left glenohumeral passive abduction was full but the resisted strength remained 4/5. The patient was attributed to isotonic strengthening exercises using free weights (1 kg dumbbell). A regimen of weight training exercises (isotonic) for shoulder abduction, forward flexion, extension, internal and external rotations were prescribed.

Discussion

This case involves multifactorial rotator cuff lesions, both extrinsic and intrinsic (*Toby et al, 2007*): Etiologies of shoulder pain can be categorized by location as either intrinsic or extrinsic. Extrinsic factors being anatomical and environmental. One of the most acclaimed anatomical factors is the morphologic characteristics of the acromion. Hooked, curved, and laterally sloping acromions are strongly associated with cuff tears and may contribute by causing tractional damage to the tendon. A progression to a hooked acromion may simply be an adaptation to an already damaged, poorly balanced rotator cuff that is creating increasing stress on the coracoacromial arch. Environmental factors implicated include increasing age, shoulder overuse, smoking, and any medical condition that impairs the inflammatory and healing response such as diabetes mellitus. (*Will, 2005*). Intrinsic factors encompass the range of injury mechanisms that occur within the rotator cuff itself. Chief among these is a degenerative-micro trauma model, which supposes that age-related tendon damage compounded by chronic microtrauma results in partial tendon tears that then develop into full rotator cuff tears. (*Nho et al, 2008*). Rotator cuff pathology is the most common cause of

shoulder pain, the most common presenting features of which are shoulder pain, decreased shoulder ROM, and weakness (9, 10). In this case our patient presented with these features. It is commonly believed that corticosteroid injections are beneficial in nonoperative management of intrinsic shoulder pathology (*Barr, 2004; Nho et al, 2008; Charlus et al, 2010 Shaw et al, 2010*). However, these generally accepted treatment strategies employed for rotator cuff pathology, including a subacromial corticosteroid injection and physical therapy improved patient's symptoms.

This case is unique in that it involved an elderly female with left multiple rotator cuff lesions with calcific deposition near inferior glenoid, acromioclavicular osteoarthritic changes, a laterally downsloping acromion with acromial osteophyte, supraspinatus tendinosis, subacromial and subdeltoid bursitis. Rotator cuff lesions in the younger population are rare and often occur chronically in the older population secondary to impingement syndrome. (*Cofield, 1985*) Over time, bony alterations (acromion thickening and bone spurs) develop within the subacromial space. *Neer (1972)* stated that the typical age of these individuals with stage III impingement was greater than 40 years old. The patient opted for corticosteroid injection. After corticosteroid injections, the patient participated in a 6 week rehabilitation program. The initial goals of the rehabilitation program were to decrease pain through modality use; and to restore range of motion, first passively and progressing to full AROM. No studies have been identified that suggest the best practice for physical rehabilitative measures (*McClure & Flowers, 1992*). Many therapeutic approaches that have

been used to treat a person with rotator cuff lesion include manual therapy, electrical modalities, active exercises, and various basic and advanced joint mobilization techniques (*McClure & Flowers, 1992*). Hot pack, ultra reiz current therapy and light mobilization shoulder exercises were prescribed to this patient due to pain. *Ryans (2005)* did a study on A randomized controlled trial of intra-articular triamcinolone and/or physiotherapy in shoulder capsulitis. The purpose of the study was to assess the effectiveness of intra-articular triamcinolone injection and physiotherapy singly or combined in the treatment of adhesive capsulitis of the shoulder. Once sufficient range of motion was achieved, rotator cuff resistance training was initiated (*Davies & Durall, 2000*). The rotator cuff both centralizes and approximates the humeral head within the glenoid.'8 9 Sharkey and Marder' reported that the rotator cuff musculature opposes superior translation of the humeral head during abduction. If the rotator cuff fails to perform this humeral depression function (as in this patient), the supraspinatus can become impinged, placing the repaired supraspinatus tendon in a compromising position. Initially, the only resistance provided was arm weight against gravity, progressing to dumbbells. In addition to rotator cuff strengthening, the patient performed a full scapular stabilization program. The scapular stabilizers play a vital role in the rehabilitation of rotator cuff repair. Motion of the scapulothoracic articulation is essential for fluent, coordinated movement of the shoulder.'2' The scapular stabilizers provide a firm base of support for glenohumeral movements and simultaneously rotate the scapula as the

humeral head moves within the glenoid fossa (scapulohumeral rhythm). Proper scapulohumeral rhythm maintains the humeral head in optimal alignment within the glenoid, allowing for the proper length-tension relationship among the rotator cuff muscles, glenoid, and humeral head (*Ryans, 2005*). Asynchronous scapulohumeral rhythm by the scapular stabilizers disrupts this glenohumeral-scapulothoracic alignment and coordinated movement by the shoulder.'2' With this humeral head alignment disrupted, the likelihood of the greater tuberosity's impinging the subacromial structures (supraspinatus tendon, subacromial bursa, and bicepital tendon) increases (*Myers, 1999*).

Post pain relief the exercise regime included rotator cuff strengthening and in addition a scapular stabilization program. The scapular stabilizers play a vital role in the rehabilitation of rotator cuff repair. Motion of the scapulothoracic articulation is essential for fluent, coordinated movement of the shoulder (Myers JB). The scapular stabilizers provide a firm base of support for glenohumeral movements and simultaneously rotate the scapula as the humeral head moves within the glenoid fossa (scapulohumeral rhythm). Proper scapulohumeral rhythm maintains the humeral head in optimal alignment within the glenoid, allowing for the proper length-tension relationship among the rotator cuff muscles, glenoid, and humeral head (*Norkin & Levangie, 1988*). Asynchronous scapulohumeral rhythm by the scapular stabilizers disrupts this glenohumeral-scapulothoracic alignment and coordinated movement by the shoulder (*Myers, 1999*). *Speed et al (2002)* studied 74 subjects with rotator cuff tendinitis. Extracorporeal shock wave

therapy and placebo treatment was given. Mean change in SPADI of 16.1 in the treatment group and 24.3 in the placebo group at 3 months. At 6 months the mean changes were 28.4 and 30.4, respectively. No significant differences between groups were found. *Bang & Deyle (2000)* studied 52 impingement syndrome patients and one group were given physiotherapy alone while other group was given physiotherapy along with manual therapy. Follow-up was done at 2 months. Both groups had significant improvements. Pain reduction significantly better in physiotherapy with manual therapy group, with a decrease in pain scores from 575.8 to 174.4, while physiotherapy alone reduced pain from a pre-treatment mean of 557.1 to a post-treatment mean of 360.6 (VAS 0–1,000). (*Hay et al (2003)* studied 207 patients with shoulder pain and they were given physiotherapy with subacromial steroid injection. Follow-up at 6 months was done. Improvements (defined as minimum of 50% drop in disability scores) in 60% of patients in PT group and in 53% in injection group were noted. No statistically significant difference between treatment arms at 6 weeks and 3 months. *Donatelli & Greenfield (1987)* did a case study on Rehabilitation of a Stiff and Painful Shoulder: A Biomechanical Approach. The research demonstrates there are many different treatment regimes for the management of shoulder dysfunction, none of which indicate overwhelming success. Traditionally, the painful, stiff shoulder, commonly diagnosed as frozen shoulder, is assessed without consideration of the entire shoulder complex. The biomechanics of the shoulder complex must be re-evaluated before each treatment session to

determine the appropriate course of treatment.

Prognosis

Variables that correlated with a satisfactory outcome included improvement in pain relief, the ability to carry a 10 to 15 pound suitcase at one side and the ability to eat using a utensil (*Kazemi, 1999*). Changes, ranging from tendinosis to subacromial impingement to partial- and full-thickness tears most rotator cuff injuries can be adequately diagnosed on the basis of a careful history review and physical examination, and respond well to conservative measures.

Conclusion

The shoulder is the site of many painful conditions. Because much of the symptomatology and many findings of these various conditions overlap, accurate diagnosis is dependent on a meticulous medical history and an equally thorough physical examination. Fortunately, most shoulder disorders respond to non-operative management or may resolve spontaneously. Consequently, physical therapists probably will continue to have an integral role in treating patients with shoulder pain.

References

- Bang, M.D., Deyle, G.D. 2000. Comparison of supervised exercises with and without manual physical therapy for patients with shoulder impingement syndrome. *J. Sports Phys. Ther.*, **30**: 126-37.
- Barr, K.P. 2004. Rotator cuff disease. *Phys. Med. Rehab. Clin. North America.*, **15**: 475-491.
- Charłusz M, Gasztych J, Irzmański R, Kujawa J. 2010. Comparative analysis of analgesic efficacy of selected physiotherapy methods in low back pain patients. *Orthop. Traumat. Rehab.*, **12(2)**: 225-36..
- Chiou, H.J., Chou, Y.H., Wu, J.J., Hsu, C.C., Huang, D.Y., Chang, C.Y. 2002.

- Evaluation of calcific tendonitis of the rotator cuff: Role of color doppler ultrasonography. *J. Ultrasound Med.* **21**: 289-295.
- Cofield, R.H. 1985. Rotator Cuff Disease of the shoulder. *J. Bone Joint Surg.*, **67**: 974-979.
- Davies, G.J., Durall, C. 2000. Typical rotator cuff impingement syndrome: It's not always typical. *Pt Mag Phys Ther.* **8(5)**: 58, 60, 62-4, 66-72.
- Donatelli, R.A. & Greenfield, B. 1987. Case study on Rehabilitation of a Stiff and Painful Shoulder: A Biomechanical Approach, *J. Ortho. Sports Phys. Ther.*; **9(3)**:118-126.
- Hay, E.M., Thomas, E., Paterson, S.M., et al. 2003. A pragmatic RCT of local corticosteroid injection and physiotherapy for the treatment of new episodes of unilateral shoulder pain in primary care. *Ann. Rheum. Dis.* **62**: 394-9.
- Hing, K-Tsui Sum. 2005. Shoulder impingement syndrome; Review. *Hong Kong Bull. Rheum. Dis.*, **5(1)**: 14-18.
- Jacobs, R., Debeer, P. 2006. Calcifying tendonitis of the rotator cuff: Functional outcome after arthroscopic treatment. *Acta Orthop. Belgica.*, **72(3)**: 276-281.
- Kazemi, M. 1999. Degenerative rotator cuff tears in an elderly athlete: A case report. *J. Canad. Chiro. Assoc.*, **43(2)**: 104-110.
- Lin, J.C., Weintraub, N., Aragaki, D.R. 2008. Nonsurgical Treatment for rotator cuff injury in the elderly. *J. Am. Med. Dir. Assoc.* **9(9)**: 626-632.
- McClure, P., Flowers, K. 1992. Treatment of limited shoulder motion: A case study based on biomechanical considerations. *Phys. Ther.*, **72**: 97-104.
- Myers, J.B. 1999. Conservative management of impingement syndrome in the athletic population. *J. Sports Rehab.*, **8**: 230-254.
- Neer CS 2nd. 1972. Anterior acromioplasty for chronic impingement syndrome in the shoulder: A preliminary report. *J. Bone Joint Surg.*, 54:41-50.
- Nho, S. J., Yadav, H., Shindle, M. K., & MacGillivray, J. D. 2008. Rotator Cuff Degeneration: Etiology and Pathogenesis. *Am. J. Sports Med.*, **36(5)**: 987-93.
- Nitz, A.J. 1986. Physical Therapy Management of the shoulder. *Phys. Therap.*, **66(12)**:1912-19.
- Norkin, C.C., Levangie, P.K. 1988. Joint Structure and Function: A comprehensive analysis. FA Davis, Philadelphia, Pennsylvania.
- Ryans, A. Montgomery, R. Galway, W. G. Kernohan and R. McKane 2005. Randomized controlled trial of intra-articular triamcinolone and/or physiotherapy in shoulder capsulitis. *Rheumatology*, **44(4)**: 529-534.
- Shaw L, Descarreaux M, Bryans R et al. 2010. A systematic review of chiropractic management of adults with whiplash associated disorders: Recommendations for advancing evidence-based practice and research. *Work.* **35**: 369-394.
- Speed CA, Richards C, Nichols D, Burnet S, Wies JT, Humphreys H, et al. 2002. Extracorporeal shockwave therapy for tendonitis of the rotator cuff: A double blind RCT. *J. Bone and Joint Surg. Br.* **84**: 509-12.
- Toby, B., Roger, E., Peter, R. .2007. Management of rotator cuff disease: Specific treatment for specific disorders. *Best Practice Res. Clin. Rheum.*, **21(2)**: 274-294.
- Uthoff, H.K., Loehr, J.W. 1997. Calcific tendinopathy of the rotator cuff. Pathogenesis, diagnosis and management. *J. Am. Acad. Ortho. Surg.*, **5**:183-191.
- Will, L.A. 2005. A conservative approach to shoulder impingement syndrome and rotator cuff disease: A case report. *Clin. Chiro.*, **8**: 173-178.

