

# The Pros and Cons

## A smile make-over – without any tooth preparation

**Dr. Eduardo Mahn**

Santiago, Chile  
edomahn@gmail.com

**Volker Brosch, MDT**

Brosch Dental, Germany  
info@brosch-dental.de

How can a major improvement of the shade and shape of teeth be achieved? Is there only one appropriate treatment procedure, or are there alternatives?

For quite some time, we have been hearing about minimally invasive techniques for the esthetic rehabilitation of the oral cavity. Whether a patient wishes to have stains removed, teeth bleached or the tooth shape and general appearance improved, the range of treatment options is almost unlimited. Procedures include tooth bleaching, enamel micro-abrasion, direct composite restorations and the whole spectrum of laminate veneer restorations, ranging from full veneers involving more aggressive preparation and the different types of thin or micro-veneers to non-prep veneers and edge-ups. In cases where a major improvement of the shade and shape is desirable, indirect veneers are clearly the clinician's first choice.

Because of their superior esthetic and mechanical properties, indirect veneers are ideal when extensive esthetic adjustments are required. Before the material is chosen, the clinician needs to understand the two main challenges of esthetic oral rehabilitation: selecting the proper shade and opacity of the material and determining the amount of tooth structure that needs to be removed in order to achieve the desired result. For example, in cases where teeth are moderately to severely misaligned and orthodontic treatment is not possible, aggressive preparation will be needed. The same applies to teeth with heavy staining caused by fluorosis or tetracycline.

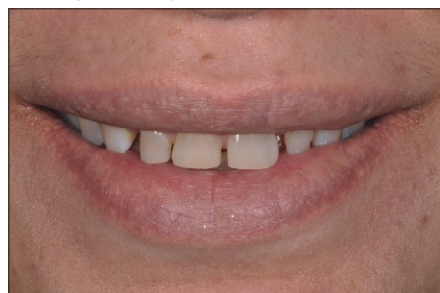

Fig.1 Preoperative Situation: Multiple distemas are present. The patient's wish was to have them closed.

### Indication: Non-Prep Veneers

Multiple diastemas may be present when teeth are too small for the maxilla and mandible or after the patient has undergone orthodontic treatment to achieve an adequate Class I canine relation. This is an ideal situation for the minimally invasive treatment with thin, non-prep veneers, especially if no major discolorations are present and if the teeth are square and flat. Contrary to common belief, non-prep veneers can represent a clinical challenge in many respects.

### Digital mock-up

A diagnostic wax-up is of paramount importance in order to evaluate the feasibility of the treatment. Once the wax-up has been created, it needs to be transferred to the mouth to demonstrate the possible esthetic outcome to the patient. A mock-up based on an impression of the wax-up is normally the method of choice. If the traditional protocol is followed, the clinician will have the chance to make small adjustments to the mock-up and discuss them with the patient after the teeth have been prepared and the temporary restorations placed. These adjustments are then communicated to the dental technician before the final restoration is fabricated.

In the case of non-prep veneers, a direct mock-up can be challenging to fabricate and the final outcome difficult to visualize due to the minimal thickness of the final restorations and the differences between the resin (used for the mock-up) and the ceramic (used for the final veneers). Presentation and imaging programs (which are easily available and affordable for everyone) are a novel option for simulating the final outcome. They allow digital mock-ups to be created on the computer screen. This method is extremely easy, accurate and reliable and saves cost and time. While a classical mock-up requires a chair time of 15-20 minutes, the digital mock-up can be done in less than one minute by the dental assistant or the clinician, if appropriate clinical and technical pictures are available.

By superimposing a picture of the wax-up onto the preoperative picture, a digital image of the final result is obtained. The only requirement is to match dimensions, inclination and perspective.

### Material selection

Closing multiple diastemas with non-prep veneers can be quite a challenging task. In most cases, the veneers will be extremely thin on the labial aspect and at the same time very thick mesially and distally. While high translucency is required to "capture" some colour from the underlying tooth structure and thus ensure a natural appearance, the material also requires reasonable opacity in order to mask the darkness of the oral cavity shining through in the area of the diastemas.

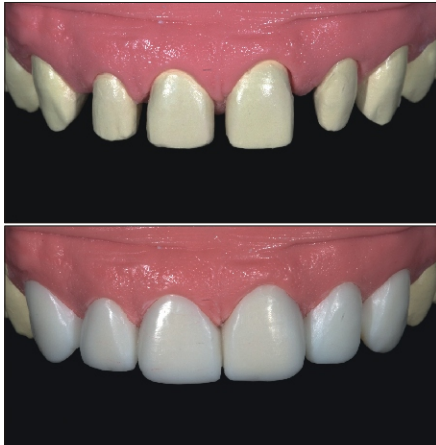Feldspathic power/liquid ceramics are well-known for their fantastic esthetic properties, but also for their weaknesses. They will fulfil the requirements of a standard case, but if wide diastemas (1.5 mm and wider) are involved, the occurring occlusal forces can be problematical. In the past few years, the esthetic properties of IPS e.max® lithium disilicate glass-ceramic (LS2) have been significantly improved due to the introduction of different gradations of translucency. Today, LS2 ceramics can be processed using either CAD/CAM or press techniques. The materials are available in up to five different levels of translucency and show flexural strengths ranging from 360 to 400 MPa. For the case at hand, the highly translucent lithium disilicate glass-ceramic IPS e.max Press HT was chosen.

### Clinical case report

A 37-year-old female patient presented to our office. She was dissatisfied with her appearance. She did not like the multiple diastemas showing when she smiled (Fig. 1) and was hoping to find someone who could offer her durable and predictable treatment not involving any tooth preparation and at a reasonable price. She had undergone orthodontic treatment before. In another

The advertisement features a central image of a modern dental chair, the Olsen Logic Infinity Cross Flex Plus, with a yellow seat and backrest. To the left of the chair is the Olsen logo with the tagline "The Innovation has this brand". To the right is the Dentomed Healthcare logo, which includes the website "www.dentomedhc.com" and the phone number "+91-9654350641, 9560223355".

clinic, teeth 11 to 21 had been restored distally with composite fillings.



Figs. 2a & b The wax-up on the model with the gingival mask in place gives an idea of how the situation can be improved.

In our practice, the old composite fillings were removed. In non-prep veneer cases, it is essential for the dental technician to have exact knowledge of the sulcus depth. Therefore, two retractions cords were placed: triple 0 (Ultrapak, Ultradent), which remained in place during impression taking, and 0, which retracted her gingiva and was removed before the impression was finalized. A wax-up was fabricated (Figs 2a and b), digitized and superimposed onto the clinical picture to create a digital mock-up, which was then discussed with the patient (Fig. 3).

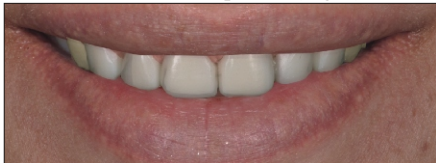

Fig.3 A digital picture of the wax-up was superimposed onto the picture of the preoperative situation. In this way, a digital mock-up was created.

In the laboratory, thin veneers were pressed on the basis of the wax-ups using IPS e.max Press. They were stained and glazed (Fig. 4). Their thickness was about that of a human nail. In the mandible, we faced a different challenge.

Diastemas between the laterals and canines were present on both sides.

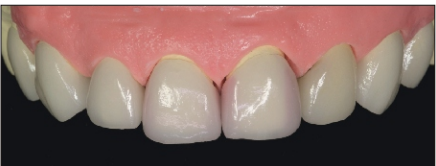

Fig.4 Full-contour veneers were pressed using highly translucent IPS e.max Press lithium disilicate material (layer thickness 200 to 300 µm).

The patient did not expect a dramatic change in the shade of her teeth. Her main concern was acceptable costs and the avoidance of any kind of tooth preparation. Therefore, we decided to restore her teeth with partial veneers (edge-ups). Traditional non-prep veneers would have increased the thickness of the lateral incisors and canines so

that they would not have been compatible with the central incisors. This would have created the need for 2 or 3 additional veneers (Fig. 5).

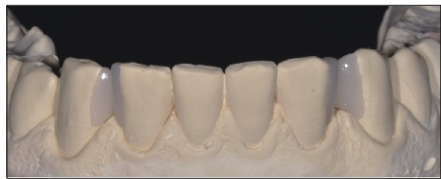


Fig.5 In the mandible, the diastemas were closed with lithium disilicate edge-ups.

In the case at hand, the luting composite provided assistance. The value concept of Variolink® Veneer enables the clinician to make slight adjustments to the shade of the restoration. The “High Value” shades allow the shade to be lightened gradually, while with the “Low Value” shades, the overlying all-ceramic material can be made darker in stages. For permanent cementation, a solvent-free bonding agent (Heliobond for enamel bonding) and a light-curing luting composite (Variolink Veneer Value +1) were used (Figs 6 to 9).

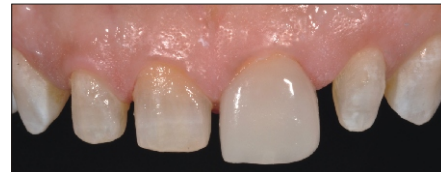

Fig.6 Dry try-in of the veneers to determine the shade of the luting composite.

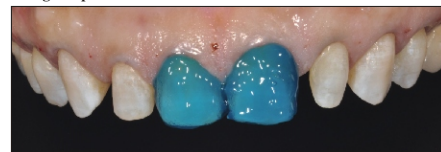

Fig.7 Adhesive luting of the veneers using solvent-free Heliobond enamel adhesive ...

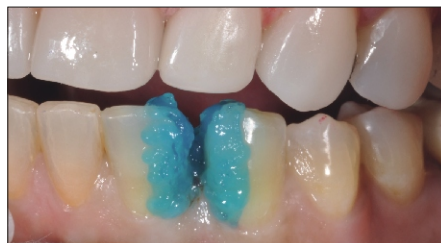

Fig.8 ...in combination with Variolink Veneer, a purely light-curing luting composite

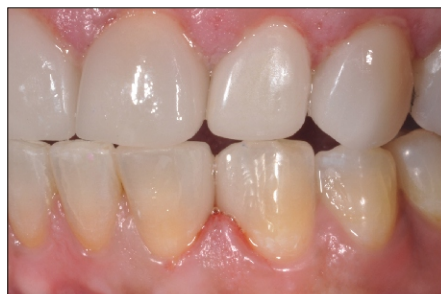
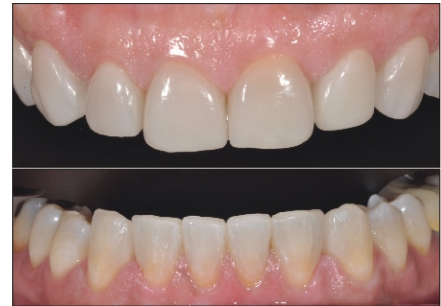
Fig.9 The function of the veneers was checked immediately after seating. The gingiva was still slightly traumatized at this point.



Figs 10 & 11 View one week after the placement of the veneers. The mandibular teeth were subjected to a one-time bleaching process.

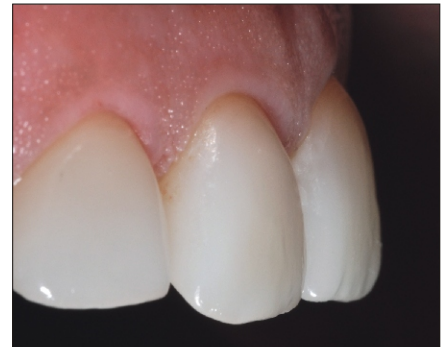

Fig.12 After four weeks, the gingiva had healed completely.

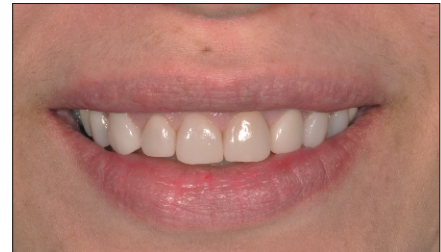

Fig.13 Final result after two months

### Conclusion

The photographs taken one week after incorporation of the veneers showed their seamless integration into the oral environment (Figs 10 and 11). Two of the aspects that are always mentioned as disadvantages of non-prep veneers are their bulky appearance and the resulting cervical transition between the veneer and the tooth structure, which can lead to periodontal problems in the long term. As shown in Figure 12, both issues can be controlled if the thickness of the ceramic layer is minimal and proper finishing and polishing is done. Figure 13 shows the final result after two months.

Media 14 | RNI : HARBIL/2008/26335  
 Established : 2008 | ISSN 0975 - 6329

**HealTalk**  
 A Journal of Clinical Dentistry  
[www.healtalkht.com](http://www.healtalkht.com)