

# Art of Debonding in Orthodontics

## Dr. Akhil Agarwal

Ex-Post Graduate  
Dept. of Orthodontics  
FODS, King George's Medical College,  
Lucknow.

## Dr. Nidhi Dwivedi

P.G. Student  
Dept. of Oral Pathology  
Saraswati Dental College  
Lucknow.

## Dr. Juhi Yadav

Consultant, Orthodontics  
Melbourne, Australia

## Dr. Rana Pratap

Reader  
Dept. of Orthodontics  
U.P. Dental College,  
B.B.D.Univ., Lucknow.

### Abstract

The potential challenge at the end of orthodontic treatment is to restore the tooth structure as was prior to the beginning of the treatment. The aim of the article is to give a proper insight into the methodology of debonding not only from the orthodontist's point of view but also keeping in mind the general practitioners who follow the procedure. At times, cases which are very well treated end up with enamel fractures or tears during debonding. Among the several methods recommended, the simplest and most effective and popular method has been discussed in this article as a clinical tip.

**Keywords :** Debonding, Orthodontic Brackets

### Introduction

The dramatic changes in Orthodontic practice began after the introduction of acid-etch bonding technique in 1955.<sup>1</sup> In 1965, Newman described the technique for use of epoxy resin for bonding attachments directly to enamel surfaces.<sup>2</sup> Currently available resins for Orthodontic use are based on Bowen's BIS-GMA resin, modified to suitable viscosities for optimal penetration into etched enamel surfaces.<sup>3</sup> Direct bonding has transferred the tedium of appliance construction into a efficient and pleasant operation for both patient and clinician. However the direct bonding procedure requires debonding at the termination of the treatment. The objectives of the debonding are to remove the orthodontic attachment and all adhesive resin from the tooth and to restore the enamel surface as closely as possible to its pretreatment condition. To achieve these objectives, correct bonding and debonding techniques are of fundamental importance. Debonding of Orthodontic brackets has been one among the many causes of enamel damage related to iatrogenicity. Hence, a correct technique related to this procedure is important from the dentist's point of view to restore the enamel surfaces as closely as possible.

The enamel thickness on labial surface of the teeth is in the range of 1500 - 2000  $\mu\text{m}$ . Bonding of brackets (metallic and ceramic) with light cure and chemically cured resins penetrate the enamel rods to range of 25 - 40  $\mu\text{m}$ . The mechanical interlocking of resin to enamel surface is stronger than the metal to resin interface. The technique of debonding of ceramic brackets is slightly different from that of the metallic brackets due to the mechanical and chemical bonding to the surfaces of tooth and the bracket.

### Clinical Procedure

The clinical debonding procedure may be discussed under:

1. Bracket Removal
  - Steel brackets
  - Ceramic brackets
2. Removal of the residual adhesive

#### 1. Bracket Removal

**Steel Brackets:** The conventional method of bracket removal involves using the twin beaked plier where in the beaks of the plier are engaged in mesial and distal edges of the bonding base and squeezed to remove the material from the resin-enamel junction.

A more gentle technique is to squeeze the brackets gently mesio-distally and lift the bracket off with the peeling - off force which is in the outward direction<sup>7</sup> (Fig. 1).

This results in a comparatively less damage to the enamel than the conventional technique, as the debonding takes place at the bracket adhesive interface as seen on the first premolar (Fig.2).

**Ceramic Brackets:** Unlike the metallic brackets, the ceramic brackets do not flex when debonding force is applied due to their brittle nature. Hence, cutting off the brackets with gradual pressure from the tips of the Twin beaked pliers is NOT recommended as it may result in enamel cracks. Hence the clinician must target the bracket adhesive interface while applying the force<sup>6</sup>. Thermal debonding and use of lasers have the potential to be less traumatic in terms of enamel damage but are not practically viable based on the investment on the inventory / equipment<sup>7,8</sup>.

#### 2. Removal of Residual Adhesive

Because of the color similarity of the adhesive and enamel surface, the clinician must take utmost care while removing the remaining residue. This may be accomplished by:

- Scraping the adhesive with a bond removing plier or with a scaler. This method is useful for debonding on canines and premolars which have a curved buccal surface.
- Using a suitable bur with a contra angle handpiece<sup>9</sup> is the preferred method for incisors, which have the flat labial surface. A plain - cut or a spiral - fluted tapered Tungsten Carbide bur (#1171 or #1172) in a contra angle handpiece is used with speed in the range of 25000 - 30000 rpm<sup>9</sup> (Fig. 3).

Speeds of over 30000 rpm are not recommended due to the risk of damage to enamel surface. Speeds of less than 10000

rpm are ineffective and the increased jiggling vibration of the bur may be uncomfortable to the patient. Even an ultra fine high speed diamond bur produces surface scratches. Sand paper discs are also not recommended.

Amount of enamel damage during debonding depends not only on the type of adhesive resin used, but also the instruments and method employed during prophylaxis. An initial prophylaxis with a bristle brush for 10 - 15 seconds per tooth abrades 10  $\mu\text{m}$  of enamel whereas the rubber cup abrades 5  $\mu\text{m}$  of enamel surface and hence is preferred<sup>10,11</sup>. The microfilled resins generally require rotary instrumentation. The enamel loss then may be 10-25  $\mu\text{m}$ . The tungsten carbide bur removes 10  $\mu\text{m}$  of the enamel surface as compared to 20  $\mu\text{m}$  with a high speed bur<sup>12</sup>.

The removal of outermost layer of enamel is not as harmful in accordance with recent views on tooth surface dynamics because the thickness of enamel is in the range of 1000-2000  $\mu\text{m}$ . It has been demonstrated that caries do not develop at such sites even if the enamel layer is removed. Remineralisation of enamel after polishing and completion of all dental procedures is around 1-2  $\mu\text{m}$  a year. Hence, remineralisation would compensate for the compromised wear during polishing.

### Summary

Points to remember while debonding:

- Place the beaks of the plier on mesial and distal sides of the bracket resin interface and not occluso-gingivally / incisogingivally.
- Apply a peeling off / outward force to minimize the chances of enamel damage.
- The ceramic brackets should be debonded at the bracket adhesive interface while the metallic brackets can be debonded at the enamel adhesive interface.
- Residual adhesive should be removed with a plain cut or a spiral tungsten carbide taper bur (#1171 or #1172) in a contra angle handpiece with speed of 25000 - 30000 rpm.
- Use of rubber cups is preferred over bristle brushes.

### Conclusion

With the advent of newer bonding materials and changing trends in dentistry in general, it becomes imperative to employ the most effective and easy method of debonding. After all, as the saying goes "It's not over till it's over". Restoring a healthy and normal tooth structure after the end of orthodontic treatment is as important as achieving the goal of orthodontic treatment.

References

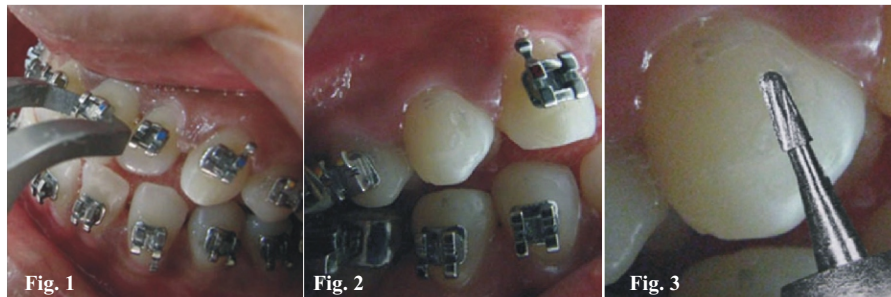
- Buonocore MA. Simple method of increasing the adhesion of acrylic filling materials to enamel surfaces: J. Dent Res 1955; 3H: 849-53.
- Newman GV. Epoxy adhesive for orthodontic attachments progress report. Am J Orthod Dentofacial Orthop 1965; 51:901-12.
- Oliver RG. A new Instrument for debonding clean up. J. Clin. Ortho. 1991;25:407-10.
- Zarrinnia K, Eid NM, Kehoe MJ. The effect of different debonding techniques on the enamel surface an invitro qualitative study. Am J Orthod Dentofacial Orthop 1995;108:284-95.
- Krell KV, Courey JM, Bishara SE . Orthodontic bracket removal using conventional and ultrasonic debonding techniques, enamel loss and time requirements. Am J Orthod Dentofacial Orthop 1993; 103:258-66.
- Bishara SE, Olsen M, VonWald L. Comparisons of shear bond strength of precoated and uncoated brackets. American Journal of Orthodontics and Dentofacial Orthopedics 1997;112:617-21.
- Tocchio RM, William PT. laser bonding of Ceramic Brackets. Am J Orthod Dentofacial Orthop 1993; 103:155-8.
- Staratmann U, Schaarschmidt K, Wegener H. The extent of enamel surface fractures a quantitative

- comparison of thermally debonded ceramics & mechanically debonded metal brackets by energy dispersive micro and image analysis. Eur J Orthod 1996;18:655-62.
- Zachrisson BU. A post treatment evaluation of direct bonding in Orthodontics. Am J Orthod Dentofacial Orthop 1979;75:121-7.
- Thompson RE, Way DC. Enamel loss due to prophylaxis and multiple bonding and debonding of orthodontic attachments. Am J Orthod Dentofacial Orthop 1981;79:282-95.
- Gwinnett AJ, Gorelick L: Microscopic evaluation of

- enamel after debonding clinical application. Am J Orthod Dentofacial Orthop 1997;71:651-65.
- Pus MD, Way DC. Enamel loss due to orthodontic bonding with filled and unfilled resins using various clean up techniques. Am J Orthod Dentofacial Orthop 1980; 77:269-83.

Legends

Fig.1. Holding the bracket mesio-distally  
 Fig.2. Adhesive as seen on the first premolar  
 Fig.3. Spiral-fluted tapered Tungsten Carbide bur (#1171 or #1172)



Product Gallery

PreciCut Soft Tissue Trimmer

Cutting Edge Made Of Special Circoniumoxide Stabilised With Yttrium

DFS PreciCut : Precision Soft Tissue Trimmer

DFS PreciCut Precision Soft-Tissue Trimmers are inserted into the handpiece of a turbine like a dental bur. Please operate at high speed: 300.000 rpm. The cutting efficiency is like a scalpel cut but more precise. **Water cooling is not required.**

DFS PreciCut Precision Tissue Trimmers should be applied at a 90° angle to the gingival sur face with only light pressure. The tip of the instrument is heating up through tissue friction quikkly, the result is an immediate tissue coagulation and minimal bleeding, **provided you work without cooling water!**

DFS PreciCut Precision Tissue Trimmer can be used for plaque removal as well. Move the instrument under slight pressure across the dental surface.

Sterilize the Tissue Trimmer like any other surgical instrument after each patient contact. The instrument is highly break resistant and withstands pressure. The tip and the surface will not dull thereby guaranteeing a multi-year service life.

We recommend a minimum stock of two tissue trimmers for your practice, since one has to be resterilized after every patient contact before it can be used again.



Keramikstruktur  
 Ceramic structure



Download Current Issue

Log on <http://www.healtalkht.com>

Writers can send their article in an easiest way. You can access your journal when you want to relax after your hectic schedule of OPD. You can get the latest about dentistry.

Healtalk is glad to inform you that it has got two Indexing i.e. Copernicus, Poland, European state & Ulrich's International Periodical Directory. They both are international indexing. Earlier Healtalk has already got International Standard Serial Number (ISSN) also.

Healtalk invite your comments & suggestions. Please share this journal with your colleagues and encourage them to logon for an easy subscription.

**CRISTOFOLI**

**Vitale 12**

- High precision control
- 12 eye monitor
- Problem solve in 12 hours capacity
- 2 trays for placing instrument for Sterilization
- High precision control, saving cycle time operation
- 12 safety system
- Clean air, water and ultraviolet
- ISO 13485, ISO 14644, BPR - Best practice in GMP - Good Manufacturing Practice

**Vitale 21**

- High precision control
- 12 eye monitor
- Problem solve in 21 hours capacity
- 2 trays for placing instrument for Sterilization
- High precision control, saving cycle time operation
- 12 safety system
- Clean air, water and ultraviolet
- ISO 13485, ISO 14644, BPR - Best practice in GMP - Good Manufacturing Practice

**DURADENT**

**Dental Suction Unit with Cabinet**

- Full Cabinet with Easy loading
- Motor power in 1/2 HP
- Vacuum Pressure 0.08mm Hg
- Air Flow 1000 l/min
- Motor speed 2800 rpm
- Price from \$6.000

**dentomed**  
 healthcare  
[www.dentomedhc.com](http://www.dentomedhc.com)  
 +91-9654350641, 9560223355