

Infected Odontogenic Keratocyst

Dr Rohit Paul
Professor
Department of Endodontics

Dr Mayura Paul
Senior Lecture
Department of Pral Pathology

Dr Rahul Paul
Professor & H.O.D.
Department of Orthodontics

Dr Geeta Paul
Professor
Department of Prosthodontics

Inderprastha Dental College and Hospital, Sahibabad

Introduction

The term 'odontogenic keratocyst' was introduced by Philipsen in 1956. It has a bimodal age of occurrence, first peak in second decade and the second peak in fifth decade.¹

Odontogenic keratocyst (OKC) is a developmental odontogenic cyst, characterized by unique and distinct histopathologic characteristics and an aggressive biologic behavior.²⁻⁶ The aggressive clinical behavior and frequent recurrence following curettage has been the focus of several studies, which indicated that the OKC epithelial lining may have some intrinsic growth potential.⁷⁻¹²

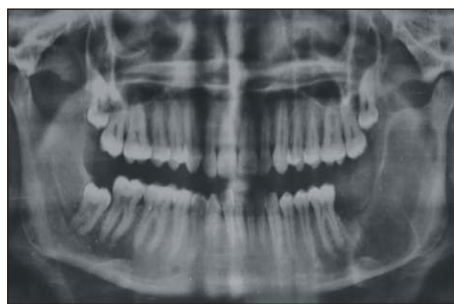The epithelial lining is a regular continuous layer of stratified epithelium, usually 6-8 cells thick with prominent basal cells which are columnar and have palisaded nuclei. Suprabasal cells frequently show intracellular edema and often an abrupt transition between them and the surface layer of parakeratin.¹⁴ The keratinized epithelial lining can change into non-keratinized epithelium because of inflammation.^{5,13} It is possible that inflammation may alter not only the morphology but also the proliferative potential of the epithelial lining. The capsule is of thin fibrous tissue which is usually free from inflammatory cell infiltrate except for occasional focal accumulations.

Case Report

A 18years old female patient reported with complaint of pain and pus discharge from lower intraoral back region since one and a half months. Extraoral features showed presence of minimal swelling on the left side of the face in mandibular body

and ramus region. Intraorally, a swelling measuring 1x1cm was seen in the retromolar and extending to 37 & 38 region. The swelling was showing smooth surface, normal colour & hard in consistency. Patient gave a history of extraction of 37 and 38 and had undergone marsupialization in the same region. OPG revealed multilocular radiolucency extending from distal of 36 upto the angle of the mandible with involvement of the whole ramus along with the coronoid process of mandible (figure 1).

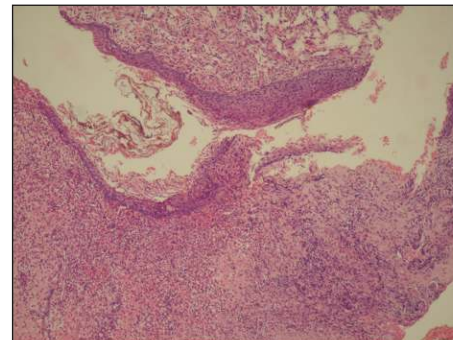
Fig. 1: OPG showing radiolucency on the left side of



the mandible extending from 36 upto the angle with involvement of the whole ramus.

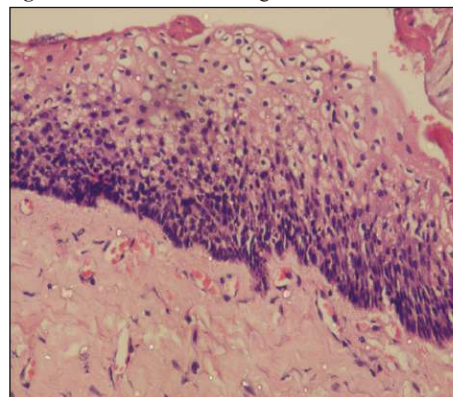
Patient underwent incisional biopsy and the tissue was submitted for histopathological analysis. Sections studied shows a cystic lumen containing flecks of keratin lined by 4-6 cell layers of parakeratinized stratified squamous epithelium which was infiltrated predominantly by acute inflammatory cells (Fig. 2). The epithelium was hyperplastic at many places with characteristic absence of rete ridges. Some areas showed proliferation of epithelial lining with absence of surface keratin layer (Fig. 3). Connective tissue wall was composed of collagen fibres with dense infiltration of both acute and chronic inflammatory cells.

Fig. 2 : Cystic lining 4-6 layers thick along with lumen



containing flecks of keratin

Fig. 3 : Proliferation of lining seen with absence of



surface keratin layer.

Discussion

Although OKC is classified as a developmental cyst, inflammation in the connective tissue wall of OKC has been found in almost 75% of the cases reported in the literature.^{5,13} In the present case, certain degree of inflammation was seen which correlates with the histopathological appearance of infected OKC.

Transformation of the keratinized epithelial lining to non-keratinized epithelium is common in OKC, and inflammation has been suggested to be responsible.^{5,13} The morphologic alterations



GENDEX
Imaging Excellence Since 1893

Versatility And Expandability In One Panoramic.



Orthoralix® 9200 / 9200 DDE

- Case Beam 3-D Imaging Systems
- Panoramic X-ray Systems
- Intraoral X-ray Systems
- Digital Ultrasound Sensors
- Digital X-ray Phosphor Plates
- Intraoral Cameras
- Imaging Software



GENDEX
Imaging Excellence Since 1893



dentomed
healthcare

www.dentomedhc.com

+91-9654350641,9560223355

in the epithelial lining of OKC in the presence of inflammation may also be associated with changes in the proliferative potential, thus affecting its biologic behavior.

Source of inflammation in the present case can be ascribed to the infection with respect to 37 and 38 for which they had been extracted. The presence of inflammation may partly be attributed to possible communications with the oral mucosa via perforations of the cortical bone, which have been documented in up to 39% of OKC.¹⁵ Inflammation may also be introduced via the periodontal ligament in cases located close to adjacent teeth.¹⁵

Inflammation has a puzzling effect on the epithelial lining of different origins. In several pathologic conditions, inflammation results in epithelial hyperplasia and metaplasia, e.g., radicular cysts, gastric epithelial-cell proliferation related to mucosal inflammation, prostatic hyperplasia, metaplasia in the nasal epithelium, and metaplastic polyp of the colon.¹⁵ Several recent studies have found a direct influence of the inflammation on epithelial cells, either through direct adhesion of the inflammatory cells, or through an indirect response to a series of chemokines produced by inflammatory cells.¹⁵ In the presence of inflammatory reaction in an odontogenic keratocyst, the degree of keratinization over these areas would be altered and this was likely to

increase the permeability of the lining and result in a soluble protein level in the fluid higher than in the uninfamed keratinizing cysts. As a result of inflammation various cytokines such as IL2, IL3 will be overexpressed which will further lead to the expression of IL2 β , β convertase, prostaglandins E₂ and coactivate compliment. This in turn, would lead to vascular permeability and leukotactic response. In odontogenic keratocyst the inflammation may result in the changes in the epithelium from keratinized to non keratinized epithelium.¹⁶

Conclusion

As reported in the previous literature and as seen in the present case, the presence of inflammation can obscure the characteristic histological appearance of the odontogenic keratocyst lining by causing a transition from keratinized to non keratinized epithelium. Such cases can prove to be a diagnostic dilemma, hence they should be evaluated very cautiously by correlating the clinical, radiographic and histological features.

References

1. Browne RM. The odontogenic keratocyst. *Brit Dent J.* 1970;3:225-238.
2. Kramer IRH, Pindborg JJ, Shear M. Histologic typing of odontogenic tumours. Berlin:Springer Verlag; 1992.
3. Shear M. Cysts of the oral region. 3rd ed. Oxford: Wright, Butterworth-Heinemann; 1992.
4. Shear M. Developmental odontogenic cysts. An update. *J Oral Pathol Med* 1994;23:1- 11.
5. El-Hajj G, Anneroth G. Odontogenic keratocysts

retrospective clinical and histologic study. *Int J Oral Maxillofac Surg* 1996;25:1249.

6. Stoelinga PJ. Long-term follow-up on keratocysts treated according to a defined protocol. *Int J Oral Maxillofac Surg* 2001;30:1425.
7. Li T-J, Browne RM, Mathews JB. Epithelial cell proliferation in odontogenic keratocysts: a comparative immunocytochemical study of Ki-67 in simple, recurrent and basal cell naevus syndrome (BCNS)-associated lesions. *J Oral Pathol Med* 1995;24:221.
8. Li T-J, Browne RM, Mathews JB. Quantification of PCNA positive cells within odontogenic jaw cyst epithelium. *J Oral Pathol Med* 1994;23:1849.
9. Ogden GR, Chisholm DM, Kiddie RA, Lane DP. p53 protein in odontogenic cysts: increased expression in some odontogenic keratocysts. *J Clin Pathol* 1992;45:100710. Shear M. The aggressive nature of the odontogenic keratocyst: is it a benign cystic neoplasm? Part I. Clinical and early experimental evidence of aggressive behavior. *Oral Oncol* 2002;38:21926.
11. Shear M. The aggressive nature of the odontogenic keratocyst: is it a benign cystic neoplasm? Part II. Proliferation and genetic studies. *Oral Oncol* 2002;38:32331.
12. Shear M. The aggressive nature of the odontogenic keratocyst: is it a benign cystic neoplasm? Part III. Immunocytochemistry of cytokeratin and other epithelial cell markers. *Oral Oncol* 2002;38:40715.
13. Rodu B, Tate AL, Martinez Jr MG. The implication of inflammation in odontogenic keratocysts. *J Oral Pathol* 1987;16:51821.
14. Browne RM. The odontogenic keratocyst. histological features and their correlation with clinical behaviour. *Brit Dent J.* 1971;131:249-59.
15. Kaplan, Hirshberg. The correlation between epithelial cell proliferation and inflammation in odontogenic keratocyst. *Oral Oncol* 2004;40:985-91.
16. Shear M. Cysts of the oral region. 3rd ed. Oxford: Wright, Butterworth-Heinemann; 1992.



Imaging Excellence Since 1893

The Next Generation Intraoral X-ray System
Has Arrived!



expert[®] DC

- Cone Beam 3-D Imaging Systems
- Panoramic X-ray Systems
- Intraoral X-ray Systems
- Digital Intraoral Sensors
- Digital X-ray Phosphor Plates
- Intraoral Cameras
- Imaging Software



Imaging Excellence Since 1893



www.dentomedhc.com

+91-9654350641, 9560223355