

Third Dentition-A Clinical Implant Case Report

Dr. Mukesh Kumar

Sr. Lecturer
Dept. of Endodontics
B R Ambedkar Dental College, Patna.

Dr. Vikash Vaibhav

Sr. Lecturer
Dept. of Prosthodontics
B R Ambedkar Dental College, Patna.

Dr. Kotni Prem Sagar

Sr. Lecturer
Dept. of Endodontics
Gandhi Dental College, Bhubneshwar.

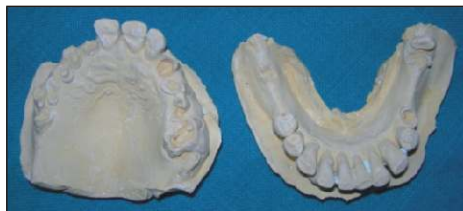Introduction

Great discoveries change the course of history. Norms and standards that have taken years and even decades to develop are questioned when new and promising innovations appear. What seemed absolute, the doctrine and principles that guided our decisions and gave us security, becomes just another set of well-developed ideas. Accepted practices are reexamined, and many lose the stature that they held for generations. Such a dramatic, all-encompassing change has occurred in prosthodontics. Oral rehabilitation using titanium implants has become a very predictable treatment alternative during last few decades. The complications are constantly decreasing and the success rate is increasing, with the advent of the osseointegrated dental implant.

A Case Report

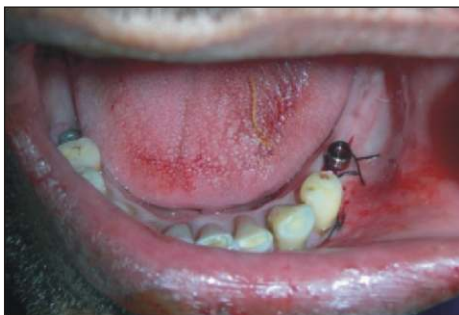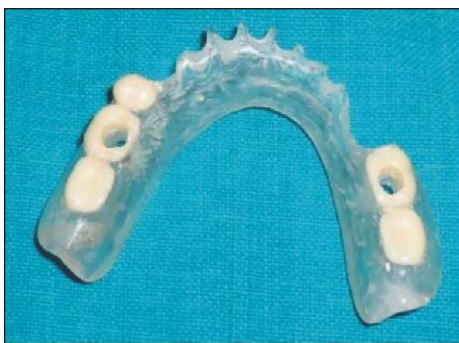Patient came with the complain of difficulty in chewing food, on examination it was found that, only upper central incisors were in healthy condition and all rest posterior teeth were mutilated and fractured, but in lower quadrant teeth were present except lower molars.

All the mutilated and fractured teeth



were extracted, suture was given. After healing before starting of treatment all the diagnosis pertaining to success of implant was done. As patient was having good oral hygiene and was having no habits of paan masala and cigarette, implant supported

fixed prosthesis was planned for patient. Implants of required dimension was selected, and treatment was planned a surgical guide stent for placement of

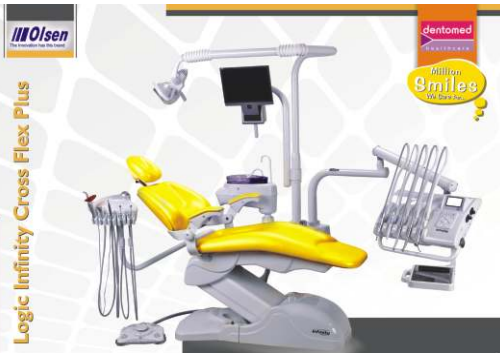
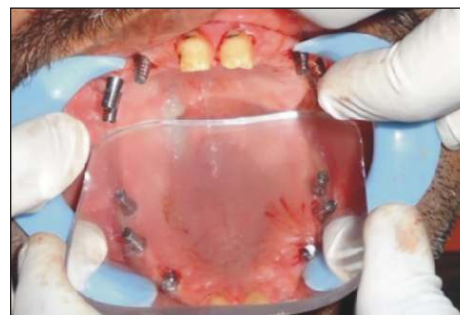
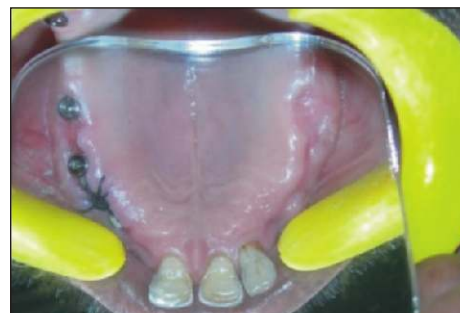implant was made, so that proper angulation for placement was decided. Full thickness flap was removed and after crestotomy implant field was prepared. Followed by this using the stent implant angulations was decided. Implants were placed.

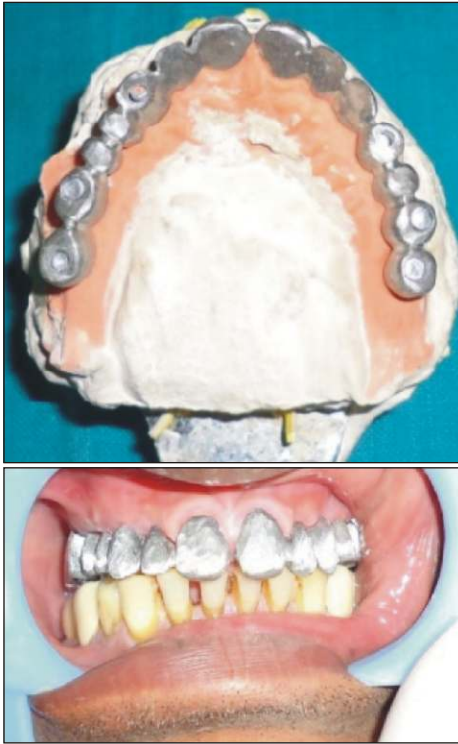In lower quadrant for replacing lower molar and in upper quadrant 1 implant in canine region, 1 in premolar and one in molar region was placed on both side of arch.

After 4 months the second stage procedure was done and gingival former was placed followed by this prosthetic component was attached. With light body putty impression was made and metal ceramic crown was luted. After more 2 months i.e after 6 months in maxilla second stage procedure was done and prosthesis was loaded.

Metal tryin was done and occlusal

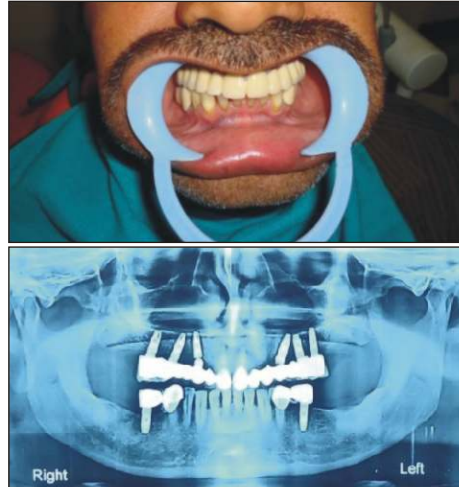


+91-9654350641, 9560223355



pattern was decided prosthesis was delivered.

Post operative orthopentram (OPG)



was taken and patient was given instruction about hygiene maintenance of prosthesis and oral structure .

Refrences

1 Carl.E.Misch : Implant Dentistry, 2nd ed.,pp 609-

629,1999

2 Cury P.R.,Sendyk W.R.,Sallum A.W. Factors associated with early and late failure of osseointegrated implant.Braz J Oral Sci.2003;2
 3. Davies S.J.,Gray R.J.M.,Young M.P.J.:Good occlusal practice in the provision of implant borne prostheses.BDJ 2002;192:79-88
 4. Esposito M.,Hirsch J.M.,Lekholm U.,Thomsen P. Biological factors contributing to failures of osseointegrated oral implants.Euro.J.of Oral Sc.1998;106:527-551
 5. Hobo, Ichida, Garcia: Osseointegration and Occlusal Rehabilitation,1st ed. pp.239-47,1988
 6. Michael D.Wise : Failure in the Restored Dentition:Management and Treatment,1st ed. pp.489-564,1995
 7. Palmer R,Palmer P,Howe L Dental implants: Part 10.Complications and maintenance.

HT Heal Talk

Dental Journal

Log on

http://www.healtalkht.com

Go

Writers can send their article in an easiest way. You can access your journal when you want to relax after your hectic schedule of OPD. You can get the latest about dentistry.

Healtalk is glad to inform you that it has got **Index Copernicus**, Poland, European state. It is an international indexing. Earlier **Healtalk** has got **International Standard Serial Number** also.

Healtalk invite you comment & suggestions. Please share this journal with your colleagues and encourage them to logon for an **easy subscription**.

Thank you for continuing support.

Download Current Issue

CRISTOFOLI

dentomed

healthcare

www.dentomedhc.com

+91-9654350641,9560223355