

Cytotherapy for Osteonecrosis of Hip

Najmul Huda¹, Asif Iqbal², Ajay Pant³, M Julfiqar², Nitin Kumar Agarwal², Pankaj Gupta⁴

¹Associate Professor, ²Assistant Professor, ³Professor and Head, ⁴Senior Resident, Department of Orthopaedics, Teerthanker Mahaveer Medical College and Research Centre, Moradabad U.P., India

Osteonecrosis of hip is a pathological condition that leads to collapse of the femoral head, & the need for total hip replacement (THR). Research has shown that at the cellular level there is decrease in osteoblastic activity & the local mesenchymal stem cells (MSC) population that leads to osteonecrosis of femoral head (ONFH). Cellular therapy could thus be used to improve the local cellular environment. This can be achieved by implanting bone marrow, containing osteogenic precursors into the necrotic lesion of the femoral head.

Keywords: Cytotherapy, Hip, Osteonecrosis, Stem cells

INTRODUCTION

Osteonecrosis is a fairly common disorder that is associated with trauma, steroid intake, alcoholism, storage disorders, fat embolism, sickle cell disease, radiation, caisson's disease & may also be idiopathic. At the cellular level there seems to be an alteration in the function & number of bone progenitor cells. This led to the belief that treatments incorporating cytotherapy have promising results.

Ficat & Arlet¹ described core decompression as the treatment in early stages of ONFH before collapse of femoral head has occurred. The rationale of this treatment is based on the findings that there is neovascularization along the channel of the core decompression.

In a normal adult, hematopoietic red marrow containing progenitor cells is present in the proximal femur; however, MRI studies in patients of ONFH have shown that the red marrow is replaced by fatty marrow as a consequence of which there is decrease in the mesenchymal stem cell pool, alteration in the intramedullary vascularity & decrease in the number of osteogenic cells.^{2,4} These cellular alterations in the proximal femur lead to inefficient creeping substitution in patients of ONFH.

Coronal T1-weighted magnetic resonance image (MRI) of the pelvis in a patient with avascular necrosis of the femoral head shows increased signal within the superior aspect of the femora head, representing fat. This is an MRI class 1 hip.

Hernigou et al.^{2,3} compared the bone marrow progenitor cell activity in patients of ONFH to a control group & found a decrease in the no. of "Colony forming units" (CFU) in patients of corticosteroid induced ONFH. In another study Suh et al⁵ observed that the MSCs showed reduced potential to differentiate in 33 patients of alcohol related ONFH.

Cytotherapy that aims to introduce progenitor cells directly to the necrotic site would increase the level of progenitor cells, & promote bone remodeling by creeping substitution thus leading to preservation of the femoral head.

Autologous bone – marrow transplantation in the treatment of ONFH have also shown good results.^{6,7} Direct implantation of bone marrow leads to local increase in the osteogenic progenitor cells that stimulate & guide bone remodelling. The injected bone marrow cells also produce angiogenic cytokines that promotes neovascularization of dead & dying osteoid tissue.

Technique for Treatment of Osteonecrosis of Hip with Bone Marrow Cells

1. Bone marrow aspiration & cell harvesting:

Bone marrow can be aspirated from the anterior or posterior iliac crest. In lean to average build patients the needle may be directly inserted into the iliac crest however in obese patients a small incision over iliac crest may be made for needle insertion.

A single beveled aspirating needle along with a 10 cc or 20 CC syringe is used to collect the aspirate (Figure 1). Rinsing the syringe & needle with a heparin

Corresponding Author:

Dr. Najmul Huda, Associate Prof., Department of Orthopaedics, Teerthanker Mahaveer Medical College and Research Centre, Delhi Road, Moradabad U.P. India: 244001. E-mail: najamajam@rediffmail.com

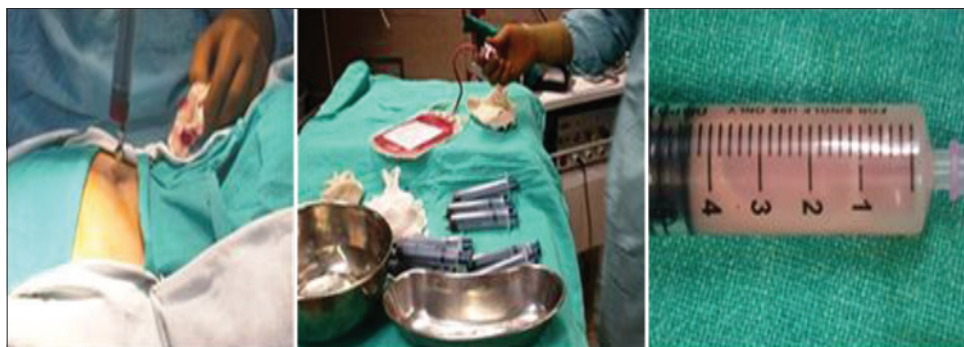

Figure 1: Showing technique of bone marrow aspiration & cell harvesting

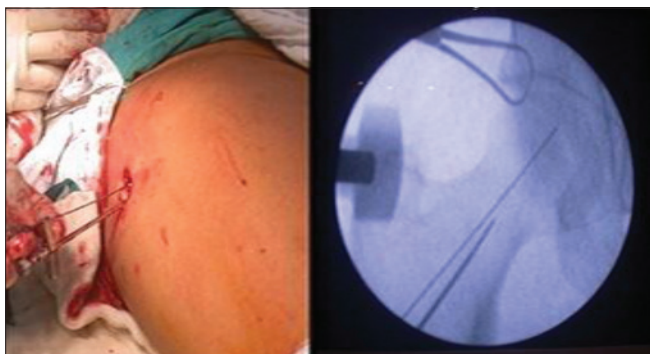


Figure 2: Showing technique of intra osseous injections of MSCs

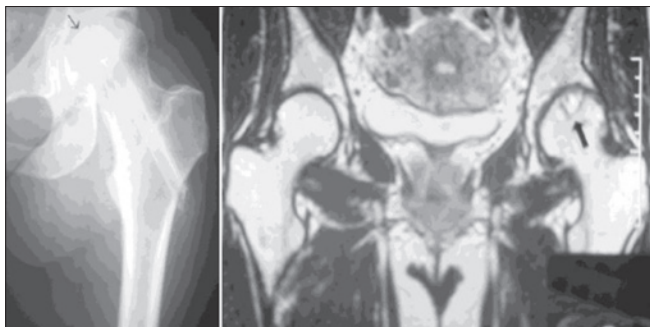


Figure 3: AP view of the left hip in a patient with AVN obtained 6 months after presentation shows that the patient has undergone core decompression but has developed mild flattening of the femoral head, indicating progression of disease despite treatment

solution, prior to its use prevents clotting of the aspirate. The needle is advanced into the iliac crest & is attached to the syringe, the plunger of which is pulled till the syringe is half filled. then exchanged & the needle is turned 45° to reorient the level successive aspirations are done, till there is a complete 360° turn of the beveled tip of needle. The aspirations are collected in plastic bags containing cell culture medium & anticoagulants, & are filtered to separate cellular aggregates & fat (Figure 2).

2. Intra osseous injections of MSCs:

Patients are placed supine on a radiolucent table. Decompression of the head is done by using a trocar & BM is injected into the necrotic segment.

RESULTS

Hernigou et al^{8,9} treated 189 hips with autologous bone marrow cells, with a follow up between 5-10 years & reported satisfactory results with respect to improvement of Harris hip score, radiographic assessment & absence from the need of THA (Figure 3). Results were better in patients in whom the disease was early & received more no. of BMC injections. In a retrospective study undertaken by Hernigou et al,⁷ 371 of the 534 hips that were treated by autologous BMC injection, showed a decrease in the volume of necrosis from 26 cm³ to 12 cm³ at an average follow up of 12 years, & only 94 patients required THR.

Gangji et al⁶ conducted a double blind RCT in 13 patients. (18 Hips) with stage I or II AVN of femoral head. They divided the patients into control group (only core decompression) & Bone marrow graft group (core decompression & implantation of autologous bone marrow). They found that at 24 months follow up there was a significant reduction in pain & joint symptoms in the bone marrow graft group.

Yoshiko et al,⁹ undertook a study to evaluate concentrated autologous bone marrow aspirate transplantation in the treatment of steroid induced AVN & found a significant improvement in pain & Harris hip score. Similar results have been reported by Wang et al¹⁰ who treated 59 hips of AVN by core decompression & autologous bone marrow concentrate. The average Harris hip score improved from 71 to 83.

CONCLUSION

Core decompression as a treatment for pre collapse stage of AVN has been used since years. However with recent research analyzing the cellular changes in patients of AVN, the use of autologous bone marrow aspirate has achieved substantial repair & stabilization of a necrotic femoral head.

A successful therapeutic outcome depends on the stage of the disease, cell number & activity of the injected cells, to overcome the limitation of inherent patient to patient

variability of MSCs, in bone marrow, tissue engineering may offer a potential solution to provide an effective number of cells to the patients.

REFERENCES

1. Arlet J, Ficat P. Forage-biopsie de la tête fémorale dans l'ostéonécrose primitive. Observations histopathologiques portant sur huit forages. *Rev Rhum Mal Osteoartic.* 1964; 31:257.
2. Hernigou PH, Beaujean F. Bone marrow activity in the upper femoral extremity in avascular osteonecrosis. *Rhum (Eng Ed)* 1993; 60:610.
3. Hernigou PH, Beaujean F, Lambotte JC. Decrease of mesenchymal stem cell pool in the upper femoral extremity of patients with osteonecrosis related to corticosteroid therapy. *J Bone Joint Surg Br.* 1999; 81:349–55. [PubMed]
4. Goujon E. Recherches expérimentales sur les propriétés du tissu osseux. *J Anat.* 1869; 6:399–421.
5. Suh KT, Kim SW, Roh HL, et al. Decreased osteogenic differentiation of mesenchymal stem cells in alcohol induced osteonecrosis. *Clin Orthop Relat Res.* 2005; 431:220-225.
6. Gangji V, Hauzeur JP. Cellular-based therapy for osteonecrosis. *Orthop Clin N Am.* 2009; 40:213-221.
7. Hernigou P, Beaujean F. Treatment of osteonecrosis with autologous bone marrow grafting. *Clin Orthop Relat Res.* 2002; 405:14-23.
8. Hernigou P, Poignard A, Zilber S, et al. Cell therapy of hip osteonecrosis with autologous bone marrow grafting. *Indian J Orthop.* 2008; 43:40-45.
9. Tomokazu Yoshioka. Hajime Mishima. Hiroshi Akaogi. Shinsuke Sakai. Meihua Li. Naoyuki Ochiai. Concentrated autologous bone marrow aspirate transplantation treatment for corticosteroid – induced osteonecrosis of the femoral head in systemic lupus erythematosus, *International Orthopaedics (SICOT)*201;1 35:823-829 DOI 10.1007/s00264-010-1048-y.
10. Wang BL, Sun W, Shi ZC, et al. Treatment of nontraumatic osteonecrosis of the femoral head with the implantation of core decompression and concentrated autologous bone marrow containing mononuclear cells. *Arch Orthop Trauma Surg.* 2010; 130:859-865.

How to cite this article: Huda N, Iqbal A, Pant A, Julfiqar M, Agarwal NK, Gupta P. Cytotherapy for Osteonecrosis of Hip; *Acta Medica International* 2014;1(1):36-38.

Source of Support: Nil, **Conflict of Interest:** None declared.