

## Rehabilitation of a Partial Rhinectomy Patient with Eyeglass Supported Provisional Nasal Prosthesis – A Case Report

Dipti Shah<sup>1</sup> Kalpesh Vaishnav<sup>2</sup> Sareen Duseja<sup>3</sup> Saloni Naik<sup>4\*</sup>

<sup>1</sup>Professor and Head, Department of Prosthodontics, Karnavati School of Dentistry, Gandhinagar, Gujarat, India.

<sup>2</sup>Professor, Department of Prosthodontics, Karnavati School of Dentistry, Gandhinagar, Gujarat, India.

<sup>3</sup>Assistant Professor, Department of Prosthodontics, Karnavati School of Dentistry, Gandhinagar, Gujarat, India.

<sup>4</sup>Post Graduate Student, Department of Periodontics, Karnavati School of Dentistry, Gandhinagar, Gujarat, India.

### ABSTRACT

**Background:** Acquired facial defects caused by extirpation of neoplasms, congenital malformations or traumatic injury results in a huge functional, cosmetic and psychological handicap in those patients. These defects can be restored by facial prosthesis using different materials and retention methods to achieve a life-like appearance and function. This clinical report describes a treatment schedule using mechanically retained poly methyl methacrylate (PMMA) resin nasal prosthesis for a patient who has undergone a partial rhinectomy due to squamous cell carcinoma of the nose. The prosthesis was made to restore the esthetic appearance of patient with mechanically retained spectacle glass frame prosthesis without any prosthetic adhesives so that the patient is more comfortable and confident to resume daily activities.

**Keywords:** Rhinosurgery, Prosthesis, Poly methyl methacrylate.

### INTRODUCTION

Squamous cell carcinoma is an aggressive malignant neoplasm. Malignancies of the nasal septum are considered rare, and accounts for 9% of all cancers of nasal cavity<sup>1,2,3,4</sup>. Squamous cell carcinoma comprises about 66% of such lesions<sup>1</sup>.

The quality of life after rhinectomy is severely compromised if an efficient surgical reconstruction or a prosthetic device is not provided. Prosthetic management of nasal defects that result from trauma or surgery has been well-documented.

A temporary nasal prosthesis may be considered for these patients. Such prosthesis can be delivered as soon as 3 to 4 weeks after surgery thus providing the patient with an improved appearance. This



enables the patient to resume social interactions while permitting easy access to observe tissue bed changes during healing. The literature indicates that 3 to 5 months of post-operative healing may be required to allow for contraction and organization of the tissue bed before commencing fabrication of a definitive nasal prosthesis<sup>1,2,3</sup>.

The purpose of this clinical report is to describe a custom sculpted acrylic resin nasal prosthesis retained by eye glasses frame.

### CASE REPORT

A 60 years old man was referred to the Department of Prosthodontics, Karnavati School of Dentistry for nasal prosthesis. Patient's history revealed surgery for squamous cell carcinoma of nose along with partial rhinectomy 5 weeks ago. The ala of the nose was not included in the resection.

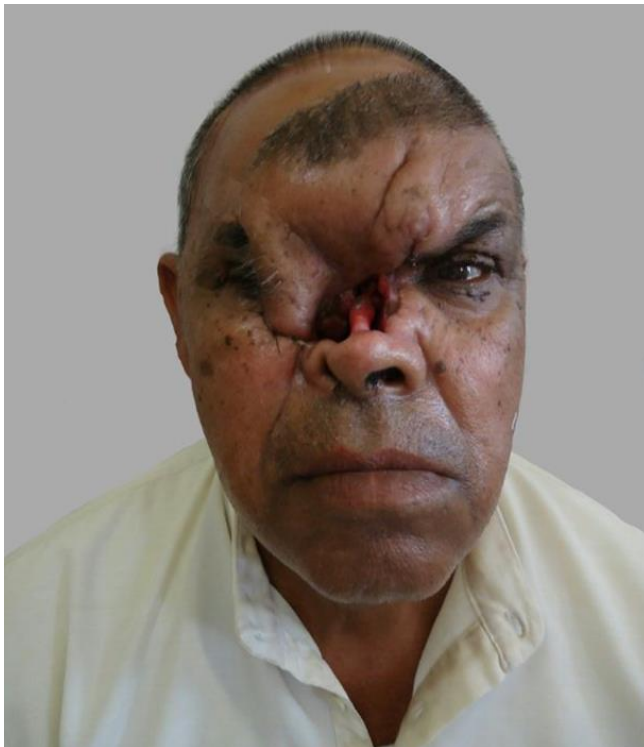Received: Jan. 19, 2014; Accepted: Apr. 2, 2014

\*Correspondence: Dr. Saloni Naik

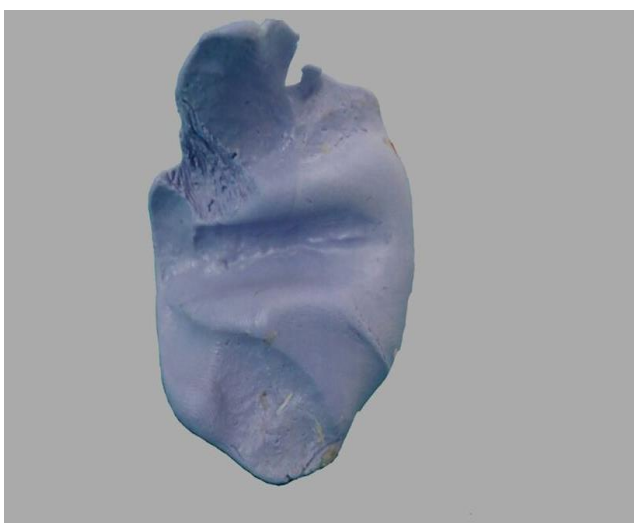
Department of Prosthodontics, Karnavati School of Dentistry, Gandhinagar, Gujarat, India.

E-mail: saloninaik.13@gmail.com

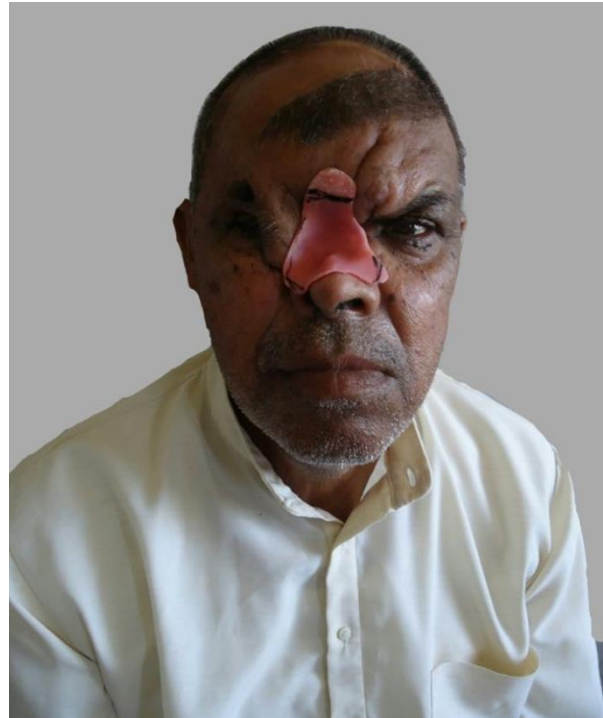Examination revealed that the patient was dissatisfied with his appearance and was especially concerned about his facial disfigurement. Various definitive prosthetic treatment modalities ranging from acrylic resin nasal prosthesis to implant retained silicone prosthesis were explained and discussed with the patient. However provisional acrylic resin prosthesis was planned for at least up to 5 months and the outcome of this treatment was explained to the patient. It was decided to use a spectacle glass frame for retaining the prosthesis.



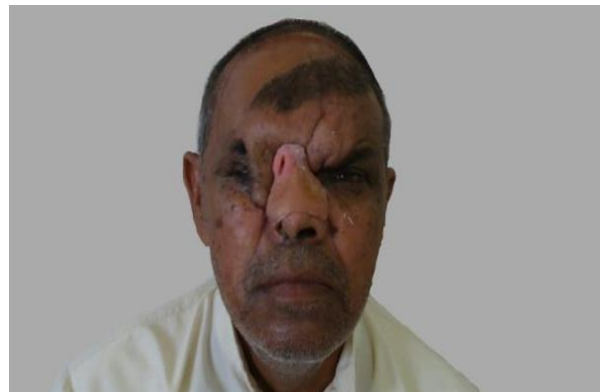**Fig 1:** Preoperative view.



**Fig 2:** Tissue surface of impression with polyvinyl siloxane.



**Fig 3:** Try in of inner part of prosthesis.



**Fig 4:** Prosthesis trial on face.



**Fig 5:** Final prosthesis with glass frame.

The patient was draped and petroleum jelly was applied to the patient's eyebrows and eyelashes. Moist gauze was packed to prevent the flow of material into the undesired areas of the defect. An impression of the defect and adjacent tissues was made using putty consistency poly vinyl siloxane (Aquasil Dentsply, U.S) in an upright position in order to minimize tissue bed distortion.

The impression was then poured in the type III dental stone (Kala stone, Mumbai, India). For better comfort, hollow nasal prosthesis was planned. Acrylic resin was first adapted to the inner surface of the mould. Try in of this inner part was then done.

Once the peripheral borders were adapted, a model of prosthesis was sculpted on the facial cast with polyvinyl siloxane (Aquasil Dentsply, U.S). Taking into account the patient's general appearance and previous photographs, the esthetic contours was developed.

The pattern adaptation on the patient's face was checked especially in the border areas. Tissue texture and relevant contours were evaluated on the face of the patient. The remaining anatomic landmarks were used as a reference augmented by a pre-operative photograph of the patient.

The polyvinyl siloxane model was placed into a flask. After flasking, the nasal prosthesis was processed using a clear PMMA resin material (DPI Heat Cure, Mumbai, India). Intrinsic coloration was done using an acrylic based paint (Fevicryl®, Pidilite®) to match the basic skin tones.

The prosthesis was evaluated on the patient face. The feather edge borders were given with the help of acrylic bur to blend with the surface of the skin<sup>4,5</sup>. Extrinsic coloration was done to further match with the skin tone of the patient. This coloration was made water resistant by painting it with Mono-poly using camel hairbrush.

After the final contouring and matching, the superior margin at the bridge of the nose was adapted as closely as possible to the point of contact with the eye glass frames. The eyeglasses were used to improve retention and to mask the margins of the prosthesis. Glass frame was modified in the bridge area.

The placement of the prosthesis was demonstrated to the patient and was then delivered. Detailed instructions regarding care and use were given to the patient.

The patient was scheduled for the first post-insertion adjustment one day after the insertion to ensure health of the tissues and to relieve the prosthesis from pressure areas on the tissues.

At the follow-up evaluation after 4 weeks, the prosthesis appeared to be functioning within normal limits. The patient was satisfied with the results of treatment and felt comfortable attending the social events while wearing the prosthesis.

Patient was then asked to come for recall visit once in every 3 months for evaluation of prosthesis and observation of any recurrence of the lesion.

## DISCUSSION

Facial defects can result from trauma, treatment of neoplasm's or congenital malformations. The choice between the surgical reconstruction and prosthetic restoration of large defects remains a difficult one and depends on the size and etiology of the defect as well as on the wish and condition of the patient. Multidisciplinary team approach including ENT surgeon, plastic surgeon and prosthodontist for restoration of facial defects is preferred, as both surgical reconstruction and prosthodontic restorations have distinct limitations<sup>6</sup>.

The surgeons are limited by the availability of tissue, the compromised local vascular bed, the need for the periodic visual inspection of an oncological defect and physical condition of the patient. Whereas, the prosthodontist is limited by inadequate materials available for facial restorations, movable tissue beds, difficulty in retaining large prosthesis and patient capability to accept the final outcome. When surgical reconstruction is not possible for patients with facial deformities, the choice of treatment is prosthetic rehabilitation. The literature indicates that 3 to 5 months are required for healing of the tissue bed. This delay in rehabilitation can be a hardship for the patient and result in adverse psychological consequences. Early rehabilitation

through the use of temporary nasal prosthesis offers means of overcoming these difficulties<sup>7,8</sup>.

Long term success of facial prosthesis mainly depends on retention. Anatomic undercuts, secondary mechanical factors, skin adhesives and implants have been reported to provide sufficient retention<sup>9</sup>.

Although the undercuts available for mechanical retention may be most advantageous at times, the presence of moisture, mobile soft-tissues or lack of stable tissue support affects the retention adversely. In this case, the eye glass frame was used to increase the mechanical retention and to achieve a lifelike appearance.

Biomaterials such as polymethyl methacrylate and silicone have been used for prosthetic rehabilitation for facial defects. PMMA resin is one of the oldest materials to be used in maxillofacial prosthetics. It has been recommended as one possible material for use in fabricating a temporary nasal prosthesis but can also be used for making a definitive prosthesis. Ease of marginal re-adaptation using chair side denture lining makes this a useful material during the period of post healing scar contraction and wound organization. However, PMMA resin results in a prosthesis that feels much less life-like because of the rigidity and opacity. Also PMMA lacks color stability but the color stability can be increased by using Mono-poly as the top layer of the prosthesis. Mono-poly is syrup made by combining 10 parts of type I, class I (heat cure) acrylic resin monomer to 1 part of type I, class I clear acrylic resin polymer by weight. The monomer is poured into a Pyrex beaker and placed in a pan of boiling water. When the monomer is warm, the polymer is shifted slowly into the monomer while stirring continuously with a glass rod. After 10 min, the solution obtains the viscosity of light oil. After the Mono-poly has cooled to room temperature, it is poured into a dark glass bottle and refrigerated<sup>10</sup>.

The advantages of this prosthesis are that the technique is non-invasive and the resultant prosthesis is tissue tolerant, aesthetic and comfortable to use, easy to fabricate and clean. Additionally, this prosthesis is often preferred by the patients because of less weight and low cost of such prosthesis.

Traditionally facial prosthesis has been made by hand worked sculpted wax or clay pattern. Recently, the computer-aided design of a nasal prosthesis based on pre-operative virtual laser scanning of the affected site with virtual adaptation to the post-operative laser-scanned surface is used. The mould for the nasal prosthesis was rapid prototyped using a computer-aided design and manufacturing (CAD-CAM) procedure increasing the quality of the final product<sup>11</sup>.

With this protocol, the eyeglasses can also be digitized, and the relative position of the nasal prosthesis can be planned and evaluated in a virtual environment without any try-in appointment.

There have been pertinent technological advances in computerized shade selection, three-dimensional digital photography, virtual surgical planning, surface scanning, and three-dimensional imaging to obtain the wax pattern.

The noncontact optical impression procedure eliminates the patient's discomfort. Three-dimensional data imaging allow visualization of a whole face without distortion, but all these technologies are still in its infancy stage and are beyond the reach of many patients.

## CONCLUSION

Defects resulting from diseases like squamous cell carcinoma can be rehabilitated using prosthetic rehabilitation so that the patient more comfortably and confidently resumes the regular daily activity. In developing countries like India, where cost of the treatment is still a primary concern for the patient, PMMA resin can be used as a material even for definitive prosthesis.

## CONFLICT OF INTEREST

No potential conflict of interest relevant to this article was reported.

## REFERENCES

1. Jain S, Maru K, Shukla J, Vyas A, Pillai R, Jain P. Nasal Prosthesis Rehabilitation: A case report. J Indian Prosthodont Soc 2011;11(4):265-9.
2. Guttal SS, Patil NP, Shetye AD. Prosthetic rehabilitation of a mid-facial defect resulting

- from lethal midline granuloma- A clinical report. *J Oral Rehabil* 2006;33(11):863-7.
3. Reisberg DJ, Habakuk SW: Nasal conformer to restore facial contour. *J Prosthet Dent* 1990;64:699-701.
  4. Rodrigues S, Shenoy V, Shenoy K. Prosthetic rehabilitation of a patient after partial rhinectomy- A clinical case report. *J Prosthet Dent* 2005;93:125-8.
  5. Fonseca EP. The importance of form, characterization and retention in facial prosthesis. *J Prosthet Dent* 1966;16:338-43.
  6. Brown KE. Fabrication of nose prosthesis. *J Prosthet Dent* 1971;26(5):543-54.
  7. Toljanic JA, Lee J, Bedard JF. Temporary nasal prosthesis rehabilitation-A clinical case report. *J Prosthet Dent* 1999;82:384-6.
  8. Beumer J, Curtis T, Firtell D. Maxillofacial rehabilitation: prosthetic and surgical considerations. St Louis Ishiyaku Euroamerica 1996.
  9. Gurbuz A, Kalkan M, Ozturk AN, Eskitascioglu G. Nasal prosthesis rehabilitation. A case report. *Quintessence Int* 2004;35:655-6.
  10. Godoy AJ, Lemon JC, Nakamura SH, King GE. A shade for acrylic facial prosthesis. *J Prosthet Dent*. 1992;68:120-2.
  11. Chalian V, Drane J, Standish SM. Maxillofacial Prosthetics: Multidisciplinary practice. Williams and Wilkins Co. Baltimore 1972.