

A Case Report of Ridge Augmentation using Onlay Interpositional Graft: An Approach to Improve Prosthetic Prognosis of a Deficit Ridge

Devanand Shetty¹ Suyog Dharmadhikari^{2*} Arvind Shetty³ Ranjeet Bapat⁴

¹Professor, Department of Periodontics and Implantology, Dr. DY Patil Dental College, Navi Mumbai, Maharashtra, India.

²Lecturer, Department of Periodontics and Implantology, Dr. DY Patil Dental College, Navi Mumbai, Maharashtra, India.

³Professor and Head, Department of Periodontics and Implantology, Dr. DY Patil Dental College, Navi Mumbai, Maharashtra, India.

⁴Associate Professor, Department of Periodontics and Implantology, Dr. DY Patil Dental College, Navi Mumbai, Maharashtra, India.

ABSTRACT

Periodontal therapy has developed beyond the scope of the treatment of periodontal pathoses. Periodontal plastic surgery consists of the reconstructive procedures designed to enhance the both function and esthetics. Deficient ridges pose a severe problem to the restorative dentist in restoring the natural form, function and esthetics of the prosthesis replacing the natural dentition. Depending upon the severity, location of these defects and the prosthetic option chosen, hard and soft tissue ridge augmentation or non-surgical approach or a combination may help to address them. The present clinical report describes a soft tissue ridge augmentation of a localized ridge defect in maxillary aesthetic region using onlay interpositional graft followed by fixed partial denture.

Keywords: Alveolar resorption, Tissue graft, Alveolar ridge augmentation.

INTRODUCTION:

The post extraction resorption of an extraction socket occurs in horizontal, vertical, buccal as well as lingual directions. The consequent bone loss is greatest in the horizontal direction and on the buccal aspect of the ridge leading to transposition of the ridge to palatal/lingual aspect. This resorptive pattern may form a residual ridge which is not suitable for optimum prosthodontic rehabilitation¹.

A deformed ridge may result from traumatic tooth extractions, advanced periodontal disease, abscess formations, congenital defects and surgical procedures². The deformity that exists in the ridge is directly related to the volume of root structure and associated missing

or destroyed bone³.

The localized alveolar ridge defects have been classified quantitatively^{4,5}, on the basis of their three dimensional form and on the basis of their severity and extent⁵⁻⁷. Such preoperative classification systems are of great clinical relevance in estimating the prognosis and the degree of difficulty of the surgical intervention.

Prosthetic treatment of uncorrected ridge defects with a fixed restoration may lead to esthetic as well as functional complications⁷. The esthetic complications include the open interdental spaces due to lack of papillae i.e. black triangles, difficult design of an esthetic pontic rest causing inadequate emergence profile, unaesthetic gingival texture or missing gingival breadth⁸. The functional problems may comprise of food impaction under the pontic,



Received: July, 20, 2013; Accepted: Aug, 06, 2013

*Correspondence Dr. Suyog Dharmadhikari.

303, shiv parvati apartment, plot-35

Sector-17, Koparkhirane, Navi Mumbai, Maharashtra, India.

Email: drsuyogd@gmail.com

phonetic problems and percolation of saliva during speech^{2,7}.

The localized ridge defects can be solved in one of the two ways i.e. non surgical and surgical. The non surgical modality includes compensation of the defect with fixed or removable prosthesis, using pontic teeth that are longer than their natural counterparts or use of palatally inclined design of the pontic. Other non-surgical means can be the use of a flange placed to simulate the missing soft tissue contours using pink ceramic or silicon in the cervical region of pontic. Though this saves the patient from a surgical intervention, such prostheses lack realism and are readily detectable when patients smile⁹.

The surgical methods used during the preprosthetic phase include correction of the ridge defect by soft tissue augmentation¹⁰⁻¹³, correction with autogenous bone and/or alloplastic bone substitutes, correction through guided bone regeneration alone or in combination with bone graft materials¹⁴⁻¹⁶. The severity of the ridge deficiency and method of tooth replacement dictate the method of choice. For small to moderate defects, soft tissue augmentation may give satisfactory outcome, especially when an FPD is scheduled. Severe defects may require a staged approach or hard tissue augmentation, the latter is of choice when implant therapy is planned¹⁷.

The present case report describes an interdisciplinary approach of soft tissue ridge augmentation procedure utilizing an autogenous soft tissue onlay interpositional graft (OIG) followed by porcelain fused to metal (PFM) fixed partial denture to replace the missing teeth and to achieve optimal form, function and esthetics.

CASE REPORT

A 32 year-old male patient reported to the Department of Prosthodontics for replacement of missing right maxillary canine and right first premolar. The dental history revealed that the patient underwent extraction of canine and first premolar, 1 year back due to the failure of endodontic treatment. On clinical examination a Siebert's class III defect was observed in the edentulous region⁴ (Figures 1 and 2).

The patient was then referred to the Department of Periodontics for the correction of the ridge defect. The treatment plan was explained to the patient and a written consent was obtained from him. Prior to the surgical phase, the abutment teeth were prepared. Partial veneer preparation for the right second premolar and full crown preparation for right lateral incisor was done. This was followed by fabrication of provisional restoration with auto-polymerizing acrylic resin (DPI RR Cold cure, Dental Products of India, Mumbai, India) and its cementation was carried out (Figure 3). The provisional prosthesis helped in estimating the size of the ridge defect to be repaired and in shaping the outline of the augmented ridge to the desired form during post surgical phase. The provisional pontic contours and tissue surface were fabricated in such a way that it simulated the final prosthesis. The tissue surface of the provisional restoration was highly polished to reduce the plaque accumulation and subsequent tissue irritation.

TECHNIQUE

The surgical technique as described by Seibert (1996)¹² was followed.

Recipient site preparation: After obtaining the written consent form the patient, the surgical procedure was performed under local anesthesia using 2% Xylocaine with 1:100,000 adrenaline. A mesiodistal crestal incision was made at the crest of the deficient ridge and was continued as a sulcular incision along the right lateral incisor (Figure 4). The incision was then carried labially to create a labial partial thickness envelope flap with sufficient apical extension to create a pouch (Figure 5). The interdental papilla distal to right lateral incisor was completely elevated and included in the flap. The palatal side of the incision was not elevated as this immobile palatal tissue served as a source of anchorage for the graft after suturing. The amount of relaxation of the envelope flap was then tested with a periosteal elevator.

Determination of interpositional onlay graft dimensions- For this, the provisional prosthesis was replaced and the prepared pouch was gently displaced labially until it is in the desired relationship to the cervical areas of the pontic teeth. A calibrated probe was then used to measure the

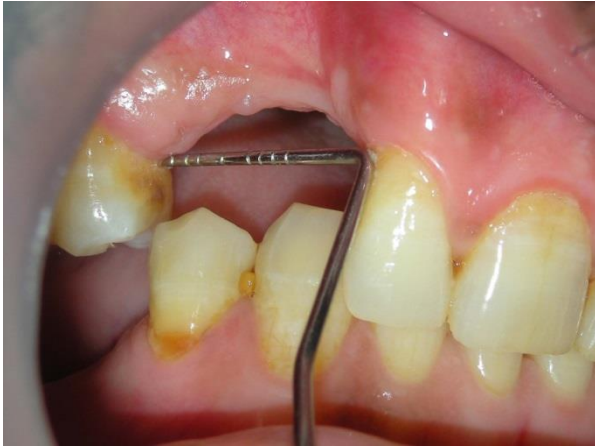

Fig 1: Ridge deficiency in vertical and horizontal dimensions.

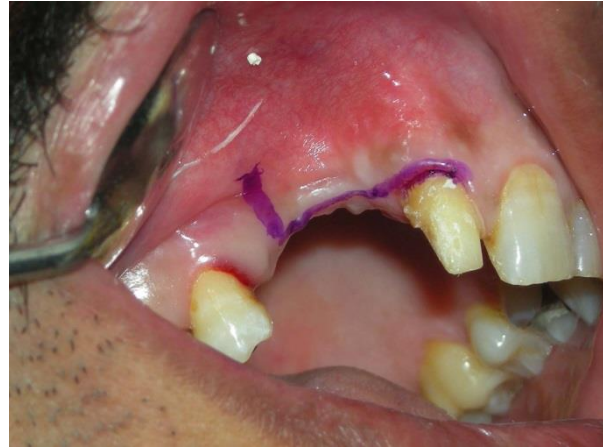

Fig 4: Marking for the pouch to receive the onlay interpositional graft.

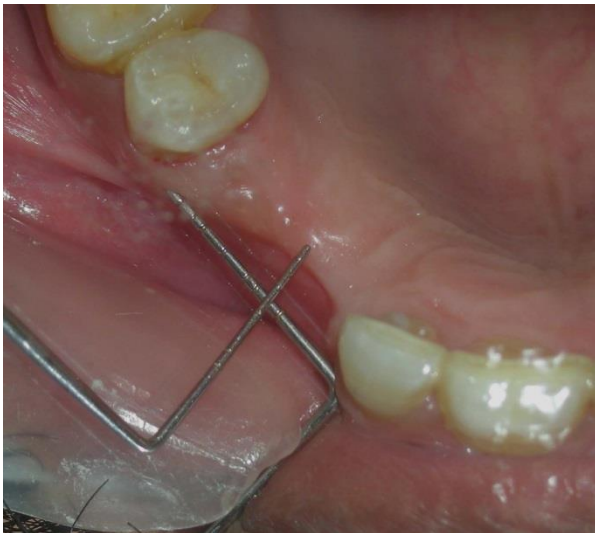

Fig 2: Ridge deficiency in vertical and horizontal dimensions.

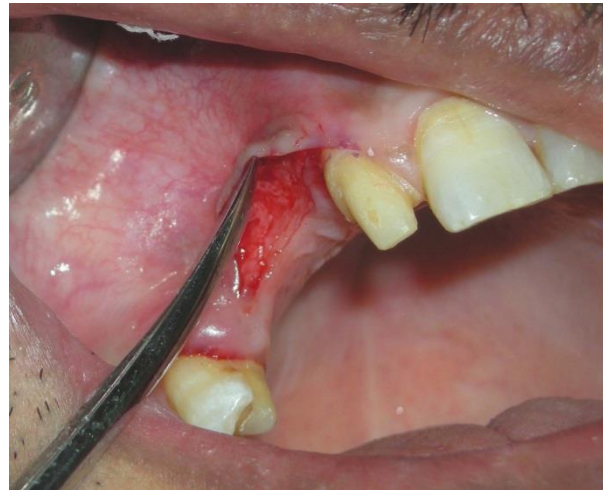

Fig 5: Soft tissue pouch created to receive the onlay interpositional graft.

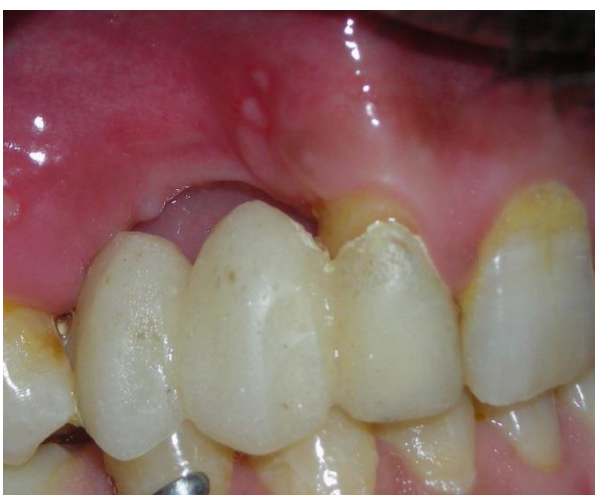

Fig 3: Temporary prosthesis cemented.

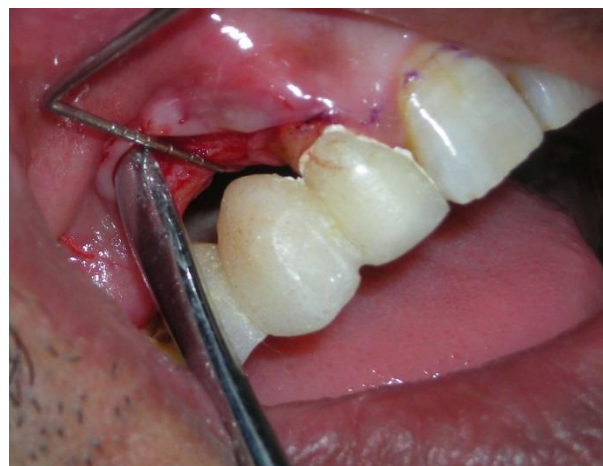

Fig 6: Measuring the onlay interpositional graft to be harvested.

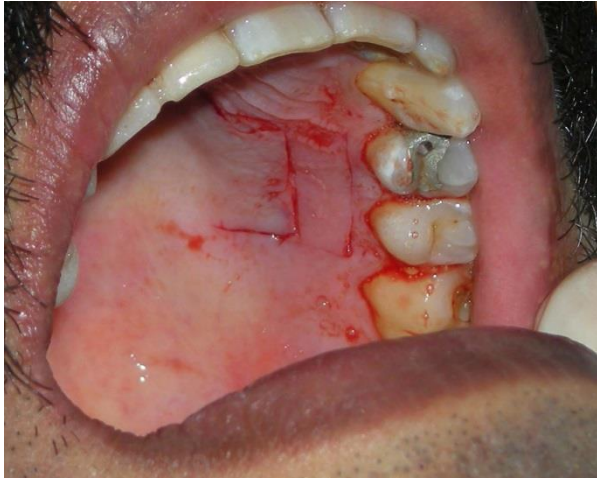

Fig 7: Incision placed at the donor site to harvest onlay interpositional graft.

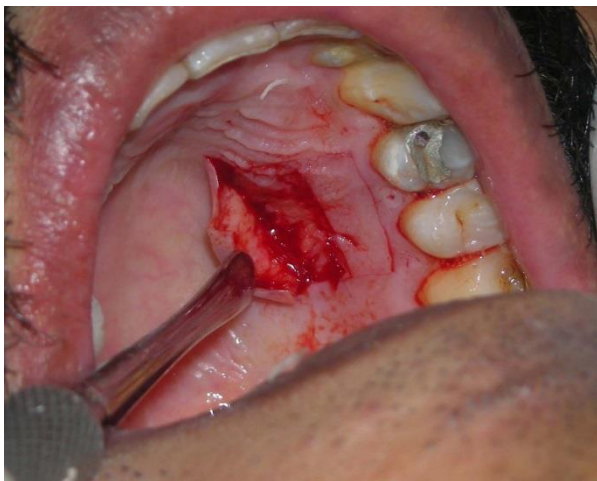


Fig 8: Onlay interpositional graft being harvested.

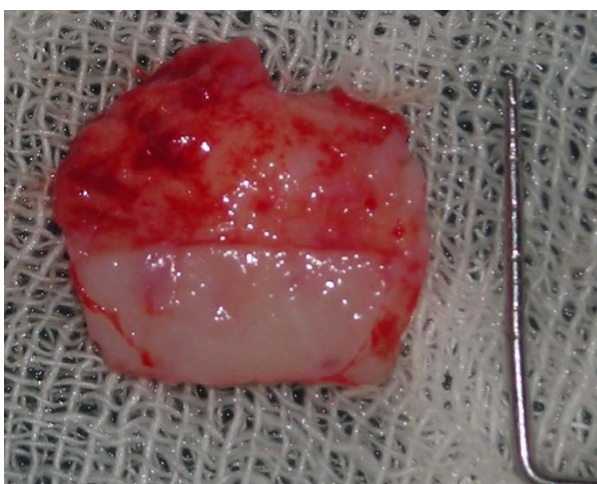


Fig 9: Onlay interpositional graft.

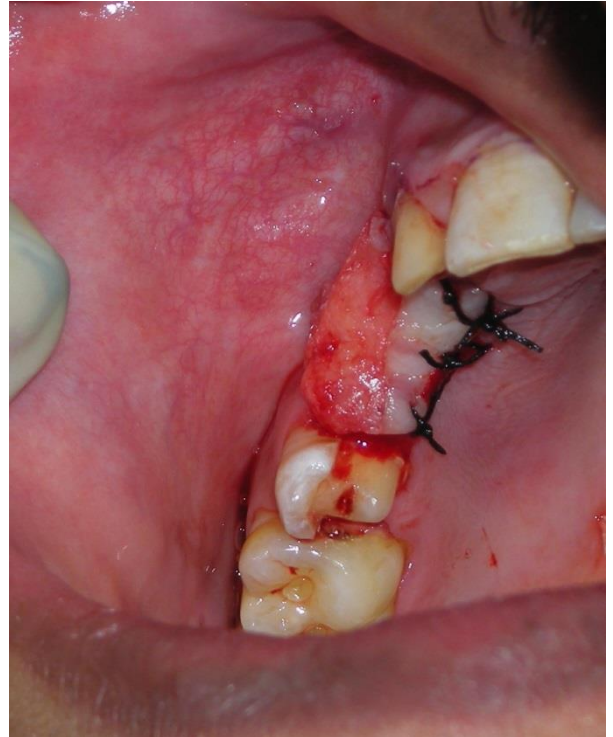

Fig 10: Onlay interpositional graft sutured at the recipient site.

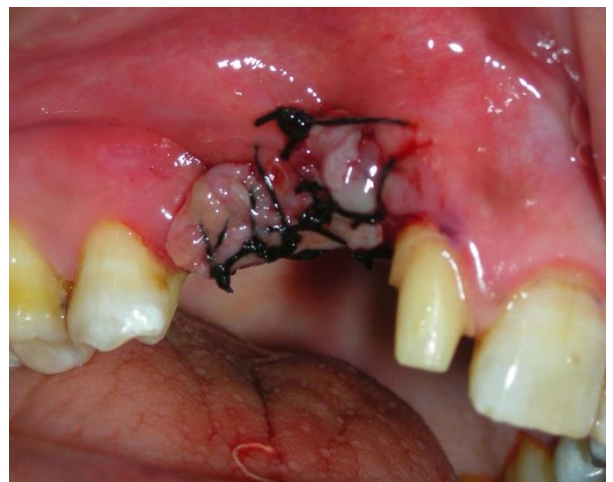


Fig 11: Onlay interpositional graft sutured at the recipient site.

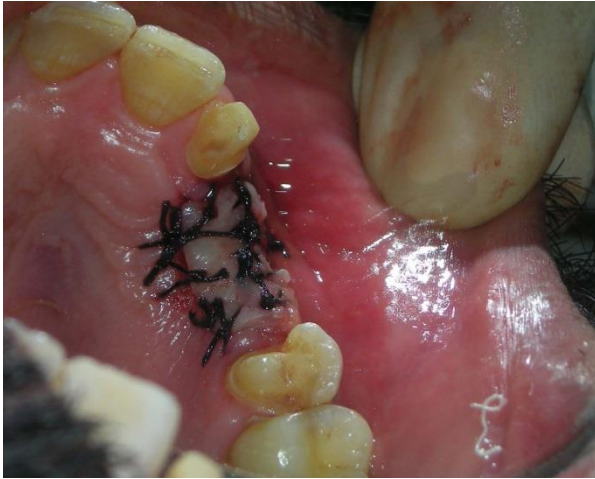

Fig 12: Onlay interpositional graft sutured at the recipient site.

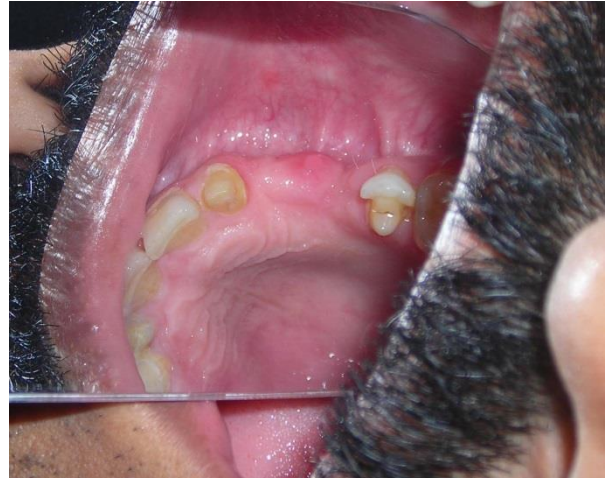

Fig 15: Result after 1 month follow up.

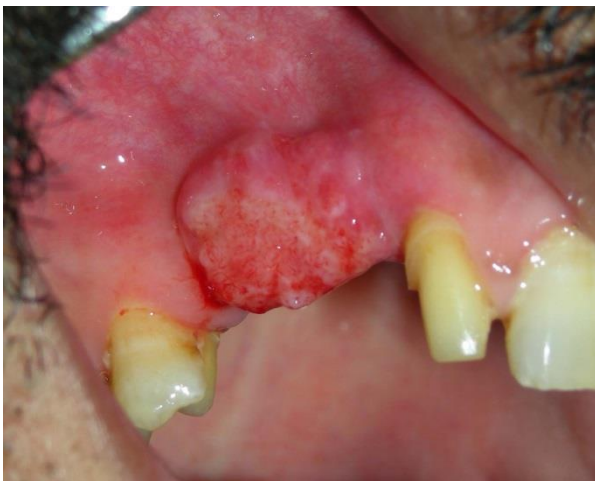

Fig 13: Result after 15 Days follow up.

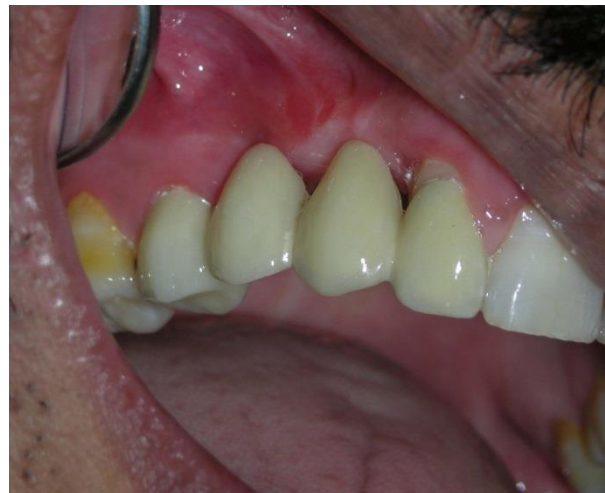

Fig 16: Result after 1 year follow up with final PFM bridge.

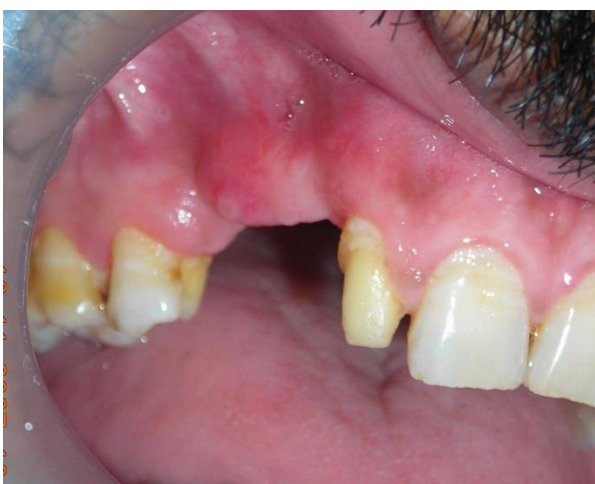

Fig 14: Result after 1 month follow up.

horizontal distance to which the flap was displaced (Figure 6). This determined the width of the onlay portion of the OIG to be harvested. The height of the interpositional portion of the OIG was also measured using the probe and a template was fabricated from the sterile aluminum foil to transfer the desired shape to the surface of the palate.

Procedure to harvest the interpositional onlay graft – The graft was harvested from palatal side of opposite premolar, as the palate is thickset in that area and the use of premolar area avoids interference with the larger branches of greater palatine artery located posteriorly. After anaesthetizing the donor site, the template was placed on the surface of palate leaving atleast 2 mm of gingiva with left premolars to avoid postsurgical gingival recession. The borders of the template were scribed 1.5 mm deep with a #15 no. scalpel

blade. For harvesting the onlay portion, two vertical incisions (anterior and posterior) and a horizontal incision (occlusal) were made perpendicular to the surface and deep into the periosteal region of the palate. The incision on the palatal border was made in the same manner as the incision for the subepithelial connective tissue graft for root coverage procedure is prepared (Figure 7). From the initial depth of 1.5 mm the incision was continued as a long bevel aimed upto the desired length towards the midline of the palate over the entire mesiodistal incision (Figure 8). This secured the de-epithelized connective tissue segment of the interpositional part of the graft.

The harvested graft was then soaked with isotonic saline and kept on wet sterile gauze (Figure 9). Hemostasis was achieved at the donor site with the help of pressure applied using moistened gauze. The edges of the palatal wound were drawn together as closely as possible with multiple sutures to minimize the exposed surface area.

Placement and suturing of the graft- The harvested graft was tried in the prepared recipient site and the necessary adjustments were made in it.

The first sutures were placed on the crestal-palatal border from the graft into the immobile palatal tissue, which stabilized the graft and fixed it into position. The de-epithelized connective tissue segment of the graft was tucked into the pouch and was sutured to the labial flap of the pouch (Figure 10). The edge of the labial flap of the pouch was sutured to the onlay graft along its labial-epithelial border, flushing at the level of epithelium (Figures 11 and 12).

The postoperative discomfort was adequately controlled with analgesic medication during the first postoperative period, and patient was instructed for oral hygiene maintenance. To prevent undue pressure from the pontics on the grafted tissue, the pontics were shortened in the cervical area prior to the recementation of the provisional prosthesis.

The tissue in the augmentation site was permitted to mature for 8 weeks, during which the patient was periodically recalled and reviewed for home care instructions. The healing at the recipient and donor site was uneventful (Figures 13, 14 and

15). Full crown preparation was done with right second premolar and impressions were made for the fabrication of four unit PFM-partial denture.

The final prosthesis was tried for its fit and necessary occlusal adjustments were made prior to its cementation with zinc phosphate cement.

The patient was scheduled for recall after two weeks, 1,3,6,12 months. At all the recall appointments home care instructions were reviewed again and the ridge-prosthesis assembly was examined for acceptability with respect to esthetics, form and function (Figure 16).

DISCUSSION

Successful tooth replacement depends on appropriate management of hard and soft tissues adjacent to the edentulous ridge¹⁷. Esthetic reconstruction of deficient ridges specially class III type, pose a major challenge to clinicians who attempt to provide life like prostheses.

In the present case, an onlay interpositional type of autogenous graft was used for the correction of deficient ridge. This type of graft was developed in an attempt to incorporate the best features of both the onlay and subepithelial connective tissue graft procedures, thus permitting a wider scope to improve the soft tissue bulk of the ridge in horizontal and vertical planes in a single procedure¹². The procedure has the advantages like, the submerged connective tissue section of the interpositional graft aids in revascularization of the onlay portion of the graft. Vestibular depth and mucogingival junction remain unchanged thereby eliminating the need for follow up corrective procedures. Smaller postoperative open wound at the donor palatal site accelerate the healing and reduced the patient discomfort. Follow up of the patient at 12 months demonstrated the clinical success of the procedure in satisfactorily restoring the esthetics, form and function.

Thus to conclude, recognition of the mucogingival problems associated with partially edentulous ridges and full understanding of the appropriate techniques available for their correction are the prerequisites for the esthetic and functional success in prosthodontic rehabilitation.

ACKNOWLEDGEMENT

Dr Pravin G Patil, Lecturer, Department of Prosthodontics, Government Dental College and Hospital, Nagpur

CONFLICT OF INTEREST

No potential conflict of interest relevant to this article was reported.

REFERENCES

1. Iasella JM, Greenwell H, Miller RL, Hill M, Drisco C, Bohra AA et al. Ridge preservation with freeze-dried bone allograft and a collagen membrane compared to extraction alone for implant site development: A clinical and histologic study in humans. *J Periodontol* 2003; 74:990-9.
2. Mishra N, Singh BP, Rao J, Rastogi P. Improving prosthetic prognosis by connective tissue ridge augmentation of alveolar ridge. *Indian J Dent Res* 2010; 21(1): 129-31.
3. Jan Lindhe, Niklaus P Lang, Thorkild Karring. *Clinical Periodontology and Implant Dentistry*. 5th ed. Wiley-Blackwell 2008.
4. Seibert JS. Reconstruction of deformed, partially edentulous ridges, using full thickness onlay grafts. Part I. technique and wound healing. *Compend Contin Edu Dent* 1983;4:437-53.
5. Allen EP, Gainza CS, Farthing GG, Nebold DA. Improved technique for localized ridge augmentation. A report of 21 cases. *J Periodontol* 1985;56:195-9.
6. Studer S, Hubschmid R, Scharer P. Volume changes after soft tissue augmentation procedures in multiple teeth defects. *J Dent Res* 1996;75:427 [Abstract 3278].
7. Studer S, Naef R, Scharer P. Adjustment of localized alveolar ridge defects by soft tissue transplantation to improve mucogingival esthetics: a proposal for clinical classification and evaluation of procedures. *Quintessence Int* 1997;28: 785-805.
8. Seibert JS, Cohen WD. Periodontal considerations in preparation for fixed and removable prosthodontics. *Dent Clin North Am* 1987;31: 529-55.
9. Seibert JS, Salama H. Alveolar ridge preservation and reconstruction. *Periodontology* 2000 1996;11: 69-84.
10. Abrams L. Augmentation of the residual edentulous ridge for fixed prosthesis. *Compend Contin Educ Gen Dent* 1980;1:205-13.
11. Seibert JS. Ridge augmentation to enhance esthetics in fixed prosthetic treatment. *Compendium* 1991;12:548, 550,552 passim
12. Seibert JS, Louis JV. Soft tissue ridge augmentation utilizing a combination onlay-interpositional graft procedure: A case report. *Int J Periodontics Restorative Dent* 1996;16:310-21.
13. Harris RJ. Soft tissue ridge augmentation with an acellular dermal matrix. *Int J Periodontics Restorative Dent* 2003;23(1):87-92.
14. Keller EE, Tolman DE. Mandibular ridge augmentation with simultaneous onlay iliac bone graft and endosseous implants: a preliminary report. *Int J Oral Maxillofac Implants* 1992;7(2):176-84.
15. Keith JD Jr. Localized ridge augmentation with a block allograft followed by secondary implant placement: a case report. *Int J Periodontics Restorative Dent* 2004;24(1):11-7.
16. Gher ME, Quintero G, Assad D, Monaco E, Richardson AC. Bone grafting and guided bone regeneration for immediate dental implants in humans. *J Periodontol* 1994;65:881-91.
17. Prato GP, Cairo F, Tinti C, Cortellini P, Muzzi L, Mancini EA. Prevention of alveolar ridge deformities and reconstruction of lost anatomy: a review of surgical approaches. *Int J Periodontics Restorative Dent* 2004;24:434-45.