

## Two Rooted Mandibular First Molar with Three Distal Canals – A Case Report

LR Surendra<sup>1\*</sup> Y NarendraNath Reddy<sup>2</sup> E Sivaprasad Reddy<sup>3</sup> D Ramaraju<sup>4</sup> T Yehoshuva Reddy<sup>5</sup>

<sup>1</sup>Professor, Department of Conservative Dentistry, SVS Institute of Dental Sciences, Mahaboobnagar, Andhra Pradesh, India.

<sup>2</sup>Professor, Department of Orthodontics, MNR Dental College, Sangareddy, Andhra Pradesh, India.

<sup>3</sup>Professor, Department of Oral Medicine and Radiology, BR Ambedkar Institute of Dental Sciences, Patna, Bihar, India.

<sup>4</sup>Professor, Department of Oral Medicine and Radiology, SVS Institute of Dental Sciences, Mahaboobnagar, Andhra Pradesh, India.

<sup>5</sup>Professor, Department of Oral Medicine and Radiology, Ideas Dental College, Gwalior, Madhya Pradesh, India.

### ABSTRACT

The Mandibular first molar is the tooth that requires root canal treatment most often. It usually has two roots with two canals mesially and one or two canals distally. A mandibular first molar with more than four canals represents a rare anatomical variation, especially when the three canals are found in distal root. With increasing reports of aberrant canal morphology, the clinician needs to be aware of this varied anatomy. This case report discusses endodontic management of 2 rooted mandibular molar with 3 distal canals (disto-buccal, middle-distal, disto-lingual) and 2 mesial canals.

**Keywords:** Molar, Root canal, Root canal obturation.

### INTRODUCTION

Success or failure of root canal treatment depends upon thorough cleansing of entire pulp cavity and impermeable sealing with inert filling material. An awareness and understanding of presence of additional canal and unusual root canal morphology is essential as it determines the successful outcome of endodontic treatment<sup>1</sup>. One of the main reasons for failure of root canal treatment is incomplete pulp tissue removal and microorganisms from the root canal system<sup>2</sup>.

In spite of all procedural protocol, if the clinician misses an additional root or canals it could pose great challenge to the clinician and thus could lead to failure of endodontic treatment. The mandibular first molar being earliest permanent posterior tooth to erupt, is considered to be the one most frequently involved in



endodontic procedures<sup>2</sup>. It exhibits considerable anatomic variation and abnormalities regarding number of roots and root canals. The majority of mandibular first molars are two rooted with two mesial and one distal canal<sup>3</sup>.

The purpose of the present article is to report the successful nonsurgical endodontic management of a 2 rooted left permanent mandibular first molar with 3 distal canals.

### CASE REPORT

A 23-year-old male patient reported to the Department of Conservative Dentistry and Endodontics, with the chief complaint of spontaneous dull pain in the lower left back tooth region for the preceding few months. His medical history was non contributory. An intraoral clinical examination revealed a deep proximo-occlusal carious lesion in the left mandibular first molar

Received: July. 15, 2013: Accepted: Sept. 1, 2013

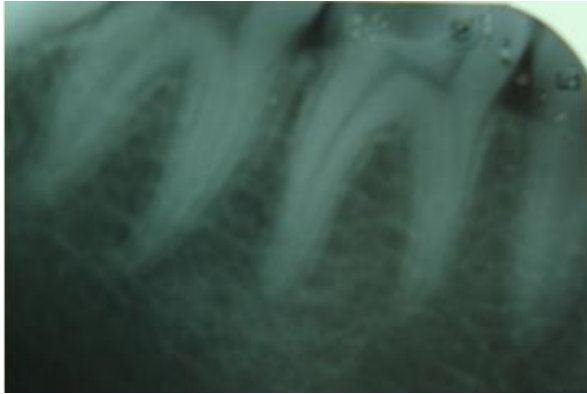\*Correspondence: Dr. LR Surendra

Department of Conservative Dentistry,

SVS Institute of Dental Sciences, Mehboobnagar, Andhra Pradesh, India.

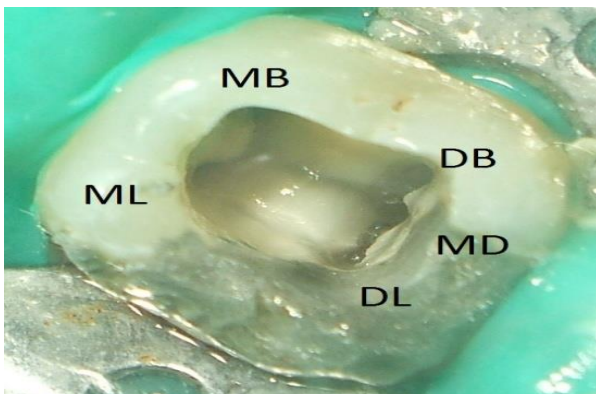
Email: nath\_reddy@yahoo.com

Copyright ©2013



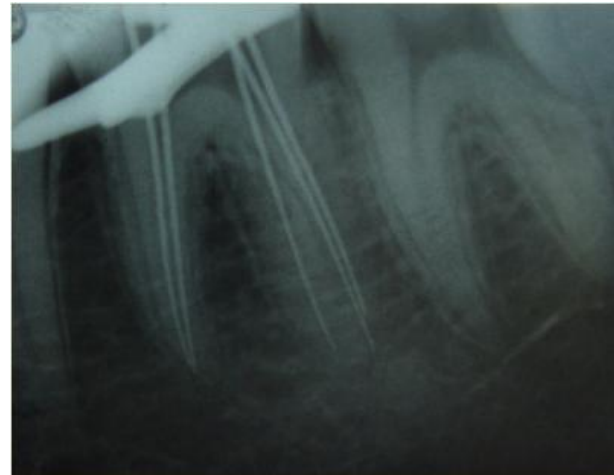
**Fig 1:** Pre Operative IOPA

(tooth #36) with tenderness on percussion. Radiographic and sensitivity tests were performed that led to the diagnosis of irreversible pulpitis with apical periodontitis, (Figure 1) warranting endodontic management. The tooth was anesthetized using 2% lignocaine and isolated under rubber dam (Hygenic Dental Dam, Coltène Whaledent, Germany). Caries was excavated and an adequate endodontic access cavity was made using an Endo Access bur (Dentsply Maillefer, Ballaigues, Switzerland). The chamber was flushed with 2.5% sodium hypochlorite to remove the debris. The dentinal map on the floor of the chamber was traced and explored using a DG 16 endodontic explorer (Hu-Friedy, Chicago, IL) following which the pulp tissue was extirpated using barbed broaches (Dentsply Maillefer, Tulsa, UK). On the developmental line between distobuccal and distolingual orifice a bleeding point was identified. On inspection with 2.5 magnification prismatic loupes (Seiler, St. Louis, MO) 5 distinct orifices were identified; 2 in the mesial root (mesiobuccal and mesiolingual) and 3 in the distal root (distobuccal, distolingual and middle distal) (Figure 2).



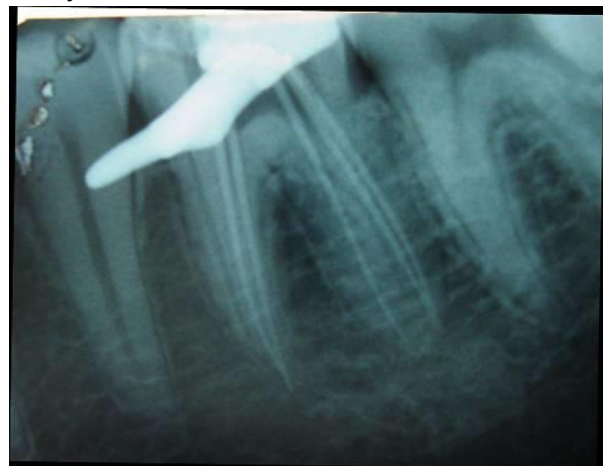**Fig 2:** Showing Access Cavity

Coronal flaring was done with Gates Glidden burs (#1, #2). Working length was determined using an electronic apex locator (Root ZX; J. Morita, Tokyo, Japan) and subsequently verified with an intraoral periapical radiograph (Figure 3). Instrumentation was performed in



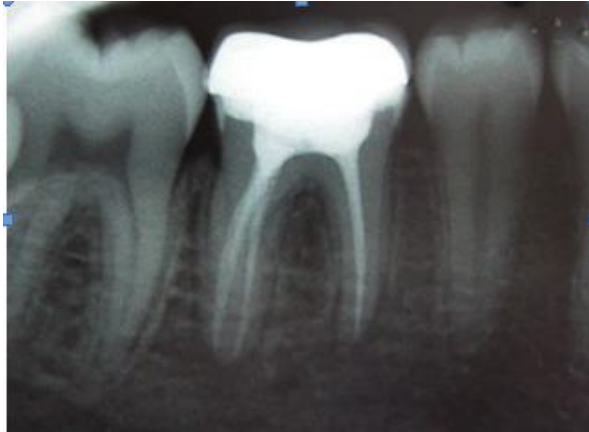
**Fig 3:** Showing working length Determination IOPA

all the canals using hand K-files (Dentsply Maillefer) by step back preparation using copious irrigation with 2.5% Sodium hypochlorite. Master cone radiograph was taken (Figure 4). The canals were finally



**Fig 4:** Showing Master cone IOPA

rinsed with Smearclear (Sybronendo), 2.5% sodium hypochlorite and normal saline and dried with sterile absorbent paper points (Dentsply Maillefer). The tooth was obturated with laterally condensed gutta-percha (Dentsply Maillefer) using AH Plus resin sealer (Dentsply Maillefer). In the subsequent appointments post endodontic restoration was done (Figure 5).



**Fig 5:** Post Obturation IOPA

## DISCUSSION

Understanding root canal morphology is one of the most important steps in successful root canal treatment<sup>4</sup>. If a clinician cannot locate the root canal, it cannot be properly cleaned, shaped, filled, and sealed. Insufficient knowledge of the anatomy of the teeth is one of the main reasons for failure of root canal therapy<sup>5</sup>; knowledge of anatomical aberrations will markedly decrease the failure rate<sup>6</sup>.

This case report highlights the rare incidence of 3 canals in the distal root of a permanent mandibular first molar. This rare entity of mandibular first molar with 3 distal canals was first reported by Berthiaume in 1983; however, the 3 distal canals ended in 2 apical foramina. According to the literature Stroner et al<sup>7</sup>, Beatty and Interian<sup>8</sup>, Martinez and Bandanell<sup>9</sup>, Friedman et al<sup>10</sup>, Goel et al 1997, Caliskan et al<sup>11</sup>, Sperber and Moreau<sup>12</sup>, Reeh<sup>13</sup>, Kimura and Matsumoto<sup>14</sup>, Gulabivala et al<sup>15</sup>, Ghodusi et al<sup>16</sup>(4 distal canals), Chandra et al<sup>17</sup> reported cases with additional canals in the distal root. This shows that occurrence of 3 distal canals in mandibular molar is a rare phenomenon.

## CONCLUSION

Successful endodontic treatment begins with proper clinical and radiographic examinations. A practitioner must be vigilant, as variations of root and canal anatomy might be encountered at any time during treatment. These anatomic variations directly affect the treatment prognosis. The idea that a tooth has only a fixed number of root canals is

now obscure and it is the responsibility of the endodontist to locate and treat the extra canals.

## CONFLICT OF INTEREST

No potential conflict of interest relevant to this article was reported.

## REFERENCES

1. Malagnino V, Gallotini L, Passariello P. Some unusual clinical cases on root anatomy of permanent maxillary molar. *J Endod* 1997;23:127-8.
2. Cohen AS, Brown DC. Orofacial dental pain emergencies: Endodontic diagnosis and management. In: Cohen S, Burns RC editors. *Pathways of the pulp*. 8<sup>th</sup>ed. Boston, MA, USA: Mosby;2002. p. 31-75.
3. Vertucci FJ. Root canal anatomy of the human permanent teeth. *Oral Surg Oral Med Oral Pathol* 1984;58:589 –99.
4. Fahid A, Taintor JF. Maxillary second molar with three buccal roots. *J Endod* 1988;14:181-3.
5. Pecora JD, Woelfel JB, Sousa-Neto MD, Issa EP. Morphology study of the maxillary molars. Part II: internal anatomy. *Braz Dent J* 1992;3:53-7.
6. Alani AH. Endodontic treatment of bilaterally occurring four rooted maxillary second molars: Case report. *J Can Dent Assoc* 2003;69:733-5.
7. Stroner WF, Remeikis NA, Carr GB. Mandibular first molar with three distal canals. *Oral Surg Oral Med Oral Pathol Oral Radiol Endod* 1984;57:554-7.
8. Beatty RG, Interian CM. A mandibular first molar with five canals: report of case. *J Am Dent Assoc* 1985;111:769-71.
9. Martinez-Berna A, Badanelli P. Mandibular first molars with six root canals. *J Endod* 1986;11:348-52.

10. Friedman S, Moshonov J, Stabholz A. Five root canals in a mandibular first molar. *Endod Dent Traumatol* 1986;2:226-8.
11. Caliskan MK, Pehlivan Y, Sepetcioglu F, Turkun M, Tuncer SS. Root canal morphology of human permanent teeth in a Turkish population. *J Endod* 1995;21:200-4.
12. Sperber GH, Moreau JL. Study of the number of roots and canals in Senegalese first permanent mandibular molars. *Int Endod J* 1998;31:117-22.
13. Reeh ES. Seven canals in a lower first molar. *J Endod* 1998;24:497-9.
14. Kimura Y, Matsumoto K. Mandibular first molar with three distal root canals. *Int Endod J* 2000;33:468-70.
15. Gulabivala K, Aung TH, Alavi A, Ng YL. Root and canal morphology of Burmese mandibular molars. *Int Endod J* 2001;34:359-70.
16. Ghoddusi J, Naghavi N, Zarei M, Rohani E. Mandibular first molar with four distal canals. *J Endod* 2007;33:1481-3.
17. Chandra SS, Rajasekharan M, Shankar P, Indira R. Endodontic management of mandibular molar with three distal canals confirmed with the aid of spiral computerized tomography: A case report. *Oral Surg Oral Med Oral Pathol Oral Radiol Endod* 2009;108:e77-81.