

INTRAORAL LIPOMA : A CASE REPORT AND REVIEW OF LITERATURE

Swati Choudhary¹, Krishan Deo Prasad², Abhishek Prakash³, Akshay Verma⁴

1. Post Graduate Student, Department of Oral Pathology, Shree Bankey Bihari Dental College, Ghaziabad

2. Professor and HOD, Department of Oral Pathology, Shree Bankey Bihari Dental College, Ghaziabad

3. Post Graduate Student, Department of Oral Pathology, D.J. College of Dental Sciences & Research, Modinagar

4. Post Graduate Student, Department of Oral Pathology, Rajasthan Dental College, Jaipur, Rajasthan

ABSTRACT:

Lipoma is a rare benign tumor of adipose tissue in the oral cavity. It accounts for 1 to 4% of benign neoplasms affecting predominantly the buccal mucosa, floor of mouth and tongue. We report a case of intraoral lipoma in buccal mucosa. The clinical presentation is a painless yellowish mass. The usual lesions consist of a well circumscribed, lobulated mass of mature fat cells. In other situations the covering mucosa becomes ulcerated and presents difficulties in diagnosis. They have been known to grow to large sizes causing mastication and speech difficulties. An excisional biopsy was done and histopathological examination revealed proliferation of mature adipocytes arranged in lobules and separated by fibrous septa.

Key words: Adipocytes, Lipoma, cellular atypia

INTRODUCTION:

Lipomas are the most common soft tissue neoplasms, with 15–20% of cases involving the head and neck region and only 1–4% affecting the oral cavity [1]. The first description of an oral lesion was provided in 1848 by Roux in a review of alveolar masses, where he referred to it as a "yellow epulis" [2-4]. They seem as slow growing painless lesions with a characteristic yellowish color and soft, doughy feel in the buccal mucosa, floor of the mouth and tongue, in the fourth and fifth decades and generally with no sex predilection. Some studies, however, have

shown a male predominance than females. The male to female ratio for all lipomas is 1: 2, but oral lipomas occur more in men than in women (1.5: 1). In most cases the size of the lesion is less than 3 cms, but can reach up to 4-6cms over a period of few years. The pathogenesis of lipoma is unclear, but they appear to be more common in obese people. However, the metabolism of lipoma is completely independent of the normal body fat. If the caloric intake is reduced, lipomas do not decrease in size. Multiple lipomas of head and neck have been observed in neurofibromatosis, Gardner syndrome,

encephalocraniocutaneous lipomatosis, multiple familial lipomatosis and proteus syndrome. Generalised lipomatosis have been reported to contribute to unilateral facial enlargement in hemifacial hypertrophy. Although its etiology is unknown, possible causes may include infection, trauma, chronic irritation and hormone alterations. Lipomas are usually asymptomatic until they grow to large size and may interfere with speaking and mastication. Although malignant counterpart of this tumor, liposarcoma, is another common soft tissue neoplasm, but its occurrence in oral cavity is rare. Histologically, lipomas can be classified into the following microscopic subtypes: simple lipomas, fibrolipomas, intramuscular or infiltrating lipomas, salivary gland lipomas, myxoid lipomas, spindle cell lipomas, and atypical lipomas.

CASE DETAIL:

A 25 years old male patient, reported with painless soft slowly growing mass in the buccal mucosa since last 2 years. It was solitary, lobulated soft mass, 2X1 cm in size, with smooth margins and was not fixed to underlying deeper structures (Figure 1). There were not any associated medical problems. There were no previous personal or family histories related to this problem. Other blood investigations included full blood count, serum and urea electrolytes, and urine analysis, all were in normal limits.

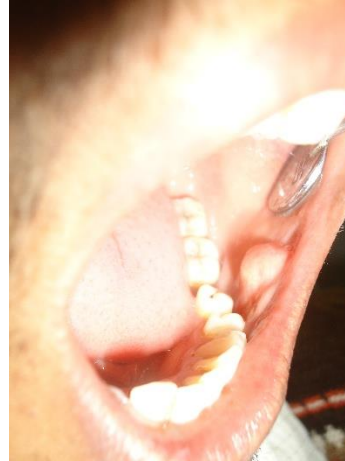

Figure 1

Excisional biopsy was done for all the cases under local anaesthesia

Histopathology: Grossly, these tumors were soft, well circumscribed, and non-infiltrating (figure 2). Microscopically, these tissues revealed sheets of mature adipocytes containing clear cytoplasm and eccentric nucleus, with no evidence of

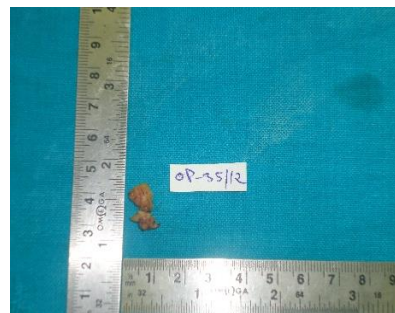

Figure 2

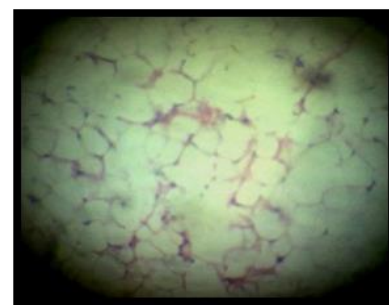


Figure 3

cellular atypia or metaplasia (figure 3). The tumor cells were arranged in lobules with intervening fibrovascular connective tissue septa. Based on the histopathological features, the diagnosis of lipoma was made.

DISCUSSION:

Lipomas are the most common mesenchymal tumors especially in trunk and proximal portions of the extremities but they are rare tumors of oral cavity. Generally, their prevalence does not differ with gender, although a predilection for men has been reported,^[5] and they occur most often in patients older than 40 years^[8]. Similar pattern was seen in our reported cases. They present as slow growing asymptomatic lesions with yellowish color and soft, doughy feel.. The cheek is the commonest site of occurrence in the intraoral cavity followed by tongue, floor of the mouth, buccal sulcus and vestibule, palate, lip and gingiva^[9]

Oral lipomas are slow growing masses, and patients commonly present with a well-circumscribed nodule that has been developing for several years.^[1] Clinically, oral lipomas generally present as mobile, painless submucosal nodules, with yellowish tinge, as observed in our cases. In some cases, oral soft tissue lipomas can present as a fluctuant nodule. Because of these clinical features, other lesions, such as oral dermoid and epidermoid cysts and oral lymphoepithelial cysts must be considered in the differential diagnosis of oral lipomas.^[10] Although, oral lymphoepithelial cysts present as

movable, painless submucosal nodules with a yellow or yellow-white colouration, they differ from oral lipomas in that the nodules are usually small at the time of diagnosis and usually occur in the first to third decade of life. Also, most oral lymphoepithelial cysts are found on the floor of the mouth, soft palate and mucosa of the pharyngeal tonsil,^[11] which are uncommon sites for oral lipomas. Oral dermoid and epidermoid cysts also present as submucosal nodules and, typically, occur on the midline of the floor of the mouth.^[12] However, oral dermoid and epidermoid cysts can occur in other locations of oral mucosa. Because an oral lipoma can occasionally present as a deep nodule with normal surface colour, salivary gland tumors and benign mesenchymal neoplasms should also be included in the differential diagnosis.^[13] Lipomas have a less dense and more uniform appearance than the surrounding fibrovascular tissue when transilluminated. Magnetic resonance imaging scans are very useful in the clinical diagnosis while CT scan and ultrasonography are less reliable. Definitive diagnosis depends on correlation between the histological and clinical features.^[14]

They may present as solitary or multiple lesions.^[1,2] Their mean size is 20 mm.^[15] Microscopically, it is difficult to differentiate between lipoma and normal adipose tissue.^[5] The microscopic appearance of a circumscribed but not encapsulated aggregate of mature adipocytes with large clear cytoplasm in the absence of vascularity is diagnostic of

a classical lipoma.^[5] Microscopically, differential diagnoses are angiolipoma, liposarcoma and normal soft fatty tissue.^[7] Lipomas of oral cavity are rare, 50% of them are in buccal mucosa and less common sites are tongue, floor of the mouth and lips. Lipoma of palate was rare in the literature and most of them are developmental lesions but true neoplasms of fat cells are rare in this place.^[16,17]

The histopathology remains the gold standard in the diagnosis of lipoma. Lipomas are not very different in microscopic appearance from the surrounding fat. Like fat, they are composed of mature fat cells, but the cells vary slightly in size and shape and are somewhat larger, measuring up to 200 µm in diameter. Subcutaneous lipomas are usually thinly encapsulated and have distinct lobular patterns. Deep-seated lipomas have a more irregular configuration, largely depending on the site of origin. All are well vascularised, but under normal conditions, the vascular network is compressed by the distended lipocytes and is not clearly discernible. Lipomas are occasionally altered by the admixture of other mesenchymal elements that comprise an intrinsic part of the tumor. The most common element is fibrous connective tissue, which is often hyalinized and may or may not be associated with the capsule or the fibrous septa. Lipomas with these features are often classified as fibrolipomas.^[15] Quite often, however, lesional fat cells are seen to “infiltrate” into surrounding tissues, perhaps producing long thin extensions of fatty tissue radiating from the central

tumor mass. When located within striated muscle, this infiltrating variant is called intramuscular lipoma (infiltrating lipoma), but extensive involvement of a wide area of fibrovascular or stromal tissues is best termed as lipomatosis. Occasional lesions exhibit excess numbers of small vascular channels (angiolipoma), a myxoid background stroma (myxoid lipoma, myxolipoma), or areas with uniform spindle shaped cells interspersed among normal adipocytes (spindle cell lipoma). When spindle cells appear somewhat dysplastic or mixed with pleomorphic giant cells with or without hyperchromatic enlarged nuclei, the term “pleomorphic lipoma” is applied. When the spindle cells are of smooth muscle origin, the term myolipoma may be used, It is angiomylipoma when the smooth muscle appears to be derived from the walls of arterioles. Rarely, chondroid or osseous metaplasia may be seen in a lipoma which is described as chondroid lipoma, osteolipoma or ossifying lipoma. On occasions, lipomas of the buccal mucosa cannot be distinguished from a herniated buccal fat pad, except by the lack of a history of sudden onset after trauma. Otherwise, lipomas of the oral and pharyngeal region are not difficult to differentiate from other lesions, although spindle cell and pleomorphic types of lipoma must be distinguished from liposarcoma.^[14] Most of these microscopic variations do not affect the prognosis, which is usually good.^[16]

The treatment of oral lipomas, including all the histological variants is simple surgical excision. No recurrence has been

observed.^[1] Although the growth of oral lipomas is usually limited, they can reach great dimensions, interfering with speech and mastication¹⁹ and reinforcing the need for excision.^[17] In the current series, all tumors were excised surgically, and no recurrence has been observed till now.

CONCLUSION:

Lipomas found in the oral and maxillofacial region are usually slow growing lesions. The clinical course is usually asymptomatic until they get larger in size. Solitary lipomas have enthused

little interest in the past and have largely been ignored in the literature. The reason is that the most lipomas grow insidiously and cause few problems other than those of a localised mass. Approximately 15-20% of lipoma occurs in the head and neck region. Among the reported intraoral lipomas, 50% occur in the buccal mucosal region. Surgical excision is the ideal treatment with excellent outcome, however complete resection should be emphasized as this is the key factor to avoid recurrence.

REFERENCES:

1. Fregnani ER, Pires FR, Falzoni R, Lopes MA, Vargas PA. Lipomas of the oral cavity: clinical findings, histological classification and proliferative activity of 46 cases. *Int J Oral Maxillofac Surg.* 2003;32(1):49–53. [[PubMed](#)]
2. Rajendran R. 5th ed. Amsterdam: Elsevier; 2006. *shafer's Oral Pathology*; pp. 194–5.
3. Cawson RA, Binnie WH, Speight PM, Barrett AW. 4th ed. New York: Churchill Livingstone; 1984. *Lucas's Pathology of Tumors of The Oral Tissues*; pp. 176–9.
4. Lawoyin JO, Akande OO, Kolude B, Agbaje JO. Lipoma of the oral cavity: clinicopathological review of seven cases from Ibadan. *Niger J Med.* 2001;10(4):189–91. [[PubMed](#)]
5. Furlong MA, Fanburg-Smith JC, Childers EL. Lipoma of the oral and maxillofacial region: Site and subclassification of 125 cases. *Oral Surg Oral Med Oral Pathol Oral Radiol Endod.* 2004;98(4):441–50. [[PubMed](#)]
6. Vindenes H. Lipomas of the oral cavity. *International Journal of Oral Surgery.* 1978;7(3):162–6. [[PubMed](#)]
7. Miles DA, Langlais RP, Aufdemorte TB, Glass BJ. Lipoma of the soft palate. *Oral Surg Oral Med Oral Pathol.* 1984;57(1):77–80. [[PubMed](#)]
8. Epivatianos A, Markopoulos AK, Papanayotou P. Benign tumors of adipose tissue of the oral cavity: a clinicopathologic study of 13 cases. *J Oral Maxillofac Surg.* 2000;58(10):1113–7. [[PubMed](#)]
9. de Visscher JG. Lipomas and fibrolipomas of the oral cavity. *J Maxillofac Surg.* 1982;10(3):177–81. [[PubMed](#)]
10. Anavi Y, Gross M, Calderon S. Disturbed lower denture stability due to lipoma in the floor of the mouth. *J Oral Rehabil.* 1995;22(1):83–5. [[PubMed](#)]

11. Flaitz CM. Oral lymphoepithelial cyst in a young child. *Pediatr Dent*. 2000;22(5):422–3. [[PubMed](#)]
12. Longo F, Maremonti P, Mangone GM, De Maria G, Califano L. Midline (dermoid) cysts of the floor of the mouth: report of 16 cases and review of surgical techniques. *Plast Reconstr Surg*. 2003;112(6):1560–5. [[PubMed](#)]
13. Tan MS, Singh B. Difficulties in diagnosing lesions in the floor of the mouth--report of two rare cases. *Ann Acad Med Singapore*. 2004;33(4 Suppl):72–6. [[PubMed](#)]
14. Gnepp DR. 1st ed. Philadelphia: Saunders; 2010. Diagnostic Surgical Pathology of the Head and Neck; p. 192.
15. Weiss SW, Goldblum JR. 5th ed. Philadelphia: Mosby; 2007. Enzinger and Weiss's Soft Tissue Tumors; pp. 571–639.
16. Neville B, Damm DD, Allen CM, Bouquot J. Philadelphia: Saunders; 2008. Oral and Maxillofacial Pathology; pp. 523–4.
17. Chidzonga MM, Mahomva L, Marimo C. Gigantic tongue lipoma: a case report. *Med Oral Patol Oral Cir Bucal*. 2006;11(5):E437–9. [[PubMed](#)]