

DIAGNOSTIC ACCURACY OF PROVOCATIVE TESTS IN LATERAL EPICONDYLITIS

G Saroja ¹, Antony Leo Aseer P ^{*2}, Venkata Sai P M ³.

¹ Faculty of physiotherapy, Sri Ramachandra University, Chennai, Tamil Nadu, India.

² Reader in physiotherapy, Sri Ramachandra University, Chennai, Tamil Nadu, India.

³ Professor & Head in Radiology, Sri Ramachandra University, Chennai, Tamil Nadu, India.

ABSTRACT

The aim of the present study was to analyze the diagnostic accuracy of the commonly used provocative tests in the diagnosis of lateral epicondylitis (LE). Cozen's test, Mills test and Maudsley test are most widely used. Till date no studies have been reported on the diagnostic accuracy of these tests. Musculoskeletal ultrasonography serves as a gold standard tool in the diagnosis of LE. Thirty subjects participated in the study. Baseline measurements of pain severity, elbow joint mobility, hand grip strength and three provocative tests were recorded by the principal investigator. A second investigator accompanied the subjects for musculoskeletal ultrasonography who was blinded of the test results. The thickness of common extensor tendon, echo texture and lateral epicondyle bony contour was measured. The test results of the three provocative tests with ultrasonographic findings were analyzed. The sensitivity for Cozen's test, Maudsley test and Mills test was found to be 84%, 88% and 53% respectively. The specificity for Cozen's Maudsley and Mills test was found to be 0%, 0% and 100% respectively. Mills test showed significant area under receiver operator curve (ROC) i.e. (0.769), which explains that the test has good diagnostic accuracy. This validation study, concludes that Mills test has an excellent diagnostic value for ruling in LE.

KEYWORDS: Lateral epicondylitis, Tennis elbow, Provocative tests, Diagnostic accuracy.

Address for correspondence: P. Antony Leo Aseer, Reader in Physiotherapy, Sri Ramachandra University, Chennai-600 116. Tamil Nadu, India. **E-Mail:** antonyleo@yahoo.com

Access this Article online

Quick Response code



DOI: 10.16965/ijpr.2014.699

International Journal of Physiotherapy and Research

ISSN 2321- 1822

www.ijmhr.org/ijpr.html

Received: 08-11-2014

Accepted : 24-11-2014

Peer Review: 08-11-2014

Published (O): 11-12-2014

Revised: 15-11-2014

Published (P): 11-12-2014

INTRODUCTION

The elbow complex comprises of three articulations, namely humeroradial, humero-ulnar and superior radioulnar joints. Even though elbow joint is not a weight bearing joint, but it is subjected to various stresses and loads during explosive activities of the upper limb. A cycle of excessive loading, overuse and repetitive activities leads to elbow pathologies. Lateral epicondylitis (LE) is known colloquially as tennis elbow, shooter's elbow, archer's elbow or simply lateral elbow pain. Runge was the first to describe this condition in 1873. The term tennis

elbow exhibits its link to racquet sports. The incidence of lateral epicondylitis varies from 1% to 3% in general population and in tennis players it only accounts for about 5% between 30-50 years of age.¹

As the name suggests the primary site of pathology in LE is at the common extensor origin. Extensor carpi radialis brevis (ECRB) tendon is most commonly involved and less frequently Extensor carpi radialis longus (ECRL) tendon. In some cases the anterior portion of EDC has also been reported to be involved. The injury occurs at the tenoperiosteal junction but scar tissue

may form over the tendon itself or at the musculotendinous junction. The cyclic loading of stresses causes micro tears with formation of granulation tissue under the tendon and at the tenoperiosteal junction.

LE is most common among athletes over 30 years with a history of repetitive movements of wrist extension combined with forearm supination. Occupational activities such as hammering, painting, using heavy spanners are considered to be the causative factors. Pain increases while gripping small objects as this hand position places additional stretch on the forearm extensors. However in LE the pathophysiology involves microscopic as well as macroscopic changes at the common extensor origin.

Biomechanically the ECRB is under maximum tension when it contracts during forearm pronation, wrist flexion and ulnar deviation. This is the typical position for a backhand shot in racquet sports. Repeated movement causes hypertrophy of this muscle and often results in loss of flexibility. In addition an imbalance exists between the forearm flexors and extensors.²

Tennis elbow is a troublesome disorder which usually presents as pain over the lateral epicondyle extending distally. The pain gradually increases with overuse or may result from a single incident (trauma). Pain may further aggravate by adding forearm supination and radial deviation. Wasting of the affected muscles and weak grip strength may also be seen in long standing cases.³

Most of the LE cases are diagnosed based on the subjective history and physical examination. Findings such as history of pain over lateral elbow on occupational activities and ADLs, point tenderness over common extensor origin, reduced grip strength, range of motion and wrist extensor strength testing help in the diagnosis. But very few studies are available on the reliability of these measures for the diagnosis of LE. The reliability of hand grip testing using a dynamometer in lateral epicondylitis was assessed in 2002. The inter examiner reliability was found to be .98, inferring maximum pain perception while gripping the dynamometer.⁴

Later, a preliminary clinical prediction rule (CPR)

was postulated to identify those with lateral epicondylitis who were likely to benefit from mobilization with movement (MVM) for which exercises were devised in 2009. The variables were based on history taking and physical examination findings. The CPR was formed using three variables namely age < 49 years, affected pain less grip strength > 112N and unaffected pain less grip strength < 336N. If all the three variables were present, the diagnostic accuracy (i.e.) specificity was shown to be 100% and sensitivity 1%.⁵ Chair test and Coffee cup test (Coonrad,1986) was also suggested to confirm the diagnosis.⁶ The most widely accepted and used tests are Cozens test, Mill's test and Maudsley test.⁷

Provocative tests are typically used to pin point or isolate specific tissues with pathology. Reliability and Validity remains the most important element of a provocative test. Compared to the other regions, physical examination tests used in upper extremity lacks reliability and validity.⁸ With extensive search, there were no psychometric properties available for lateral epicondylitis.⁹ Joshua Cleland an extensive researcher on evidence based orthopedic special tests, in his recent text edited in 2011, and reported no diagnostic accuracy of the commonly used provocative tests in lateral epicondylitis.¹⁰

Mohamed Waseema et al in 2012 in a review reported that physical examination of LE includes palpation, use of special tests such as Cozen's and mills and grip strength measure. They also reported that by far the validity i.e. specificity and sensitivity of Cozen's test and mills test has not been studied. All of the above recent studies highlight the lacunae in the currently available tests and paves way for evaluating the diagnostic accuracy of the tests employed in LE.

To measure the diagnostic accuracy of the above mentioned tests, a gold standard method is the need of the hour. Musculoskeletal ultrasonography has been proven to have high sensitivity but low specificity in the diagnosis of LE and is the most useful tool in the diagnosis of a disorder based on pathological tissue changes.¹¹

Ultrasonography is advantageous as it is the most simple and cost effective method of musculoskeletal system imaging with portability and real-time dynamic examination.¹²

Overall, Musculoskeletal Ultrasonography can be considered as a tool of reference in the diagnosis of LE. The various parameters that can be assessed include tendon thickness, echotexture, fluid content and appearance of cortical surfaces. Increase in tendon thickness is a significant feature of LE. Echo texture of tendon in fibrillar pattern depicts normalcy whereas hyper echoic pattern signifies inflammation, hypo echoic pattern is seen in case of fluid loss in tendon and anechoic pattern signifies presence of fluid. Specks of hyperechoic pattern are seen in case of calcification and cortical irregularities which are evident in chronic cases.

Hence, this study is the first of its kind that focuses on the psychometric properties of Cozen's, Mills and Maudsley tests in the diagnosis of LE.

MATERIALS AND METHODS

This validation study was approved by the ethics committee for student's proposal of Sri Ramachandra University (CSP/12/SEP/25/139).

Study participants: All patients diagnosed with LE referred to physiotherapy outpatient department of Sri Ramachandra Hospital who met the inclusion criteria were included in the study.

Subjects with lateral elbow pain, age group of 30 to 45 years of both genders and medical diagnosis of lateral epicondylitis / tennis elbow were included and those presenting with diagnosis of cervical radiculopathy or myelopathy, neurological disorders, fractures in and around elbow joint and other musculoskeletal disorders related to lateral elbow pain were excluded.

Study design: Validation study

Sample size: The sample size was estimated using data taken from a study done in 2008 in which 28 subjects were recruited.¹³

Instrumentation: Universal Goniometer Jamar Dynamometer Musculoskeletal Ultrasonography Imaging – LOGIQ P5

Procedure: 30 subjects who were referred for LE participated in the study, 10 males and 20 females. Hand dominance was checked for all the subjects of whom 28 subjects were right handed while 2 subjects were left handed. All subjects underwent a physical examination of elbow and wrist joint by the principal investigator to confirm the presence of LE.

History and physical examination: Pain location, characteristics, behavior, severity, nature of lesion, history of overuse, repetitive stresses were examined. Pain severity was measured using visual analog scale.¹⁴ The location of pain and tissue integrity was analyzed by palpation of bony contours and surrounding soft tissues. The elbow joint motion of the involved elbow was measured using a plastic Goniometer. The Jamar dynamometer with third spacing was used to measure grip strength.

Physical examination tests/ Provocation tests:

Mill's test: The Subject was positioned in a sitting posture with the shoulder slightly abducted, elbow flexed to 90°, forearm pronated and wrist flexed so that the palm of the hand would face downwards. The therapist stood behind the subject's affected side, with one hand grasping the upper arm for support and the subject's arm was elevated to 70° of abduction. The thumb of the other hand was then placed in the patient's palm between the index finger and thumb and the fingers wrapped around the dorsum of the wrist, to maintain the forearm position in full pronation and wrist in flexion. While maintaining this position, the elbow was extended slowly. Pain over the lateral aspect of the elbow joint indicated a positive test.

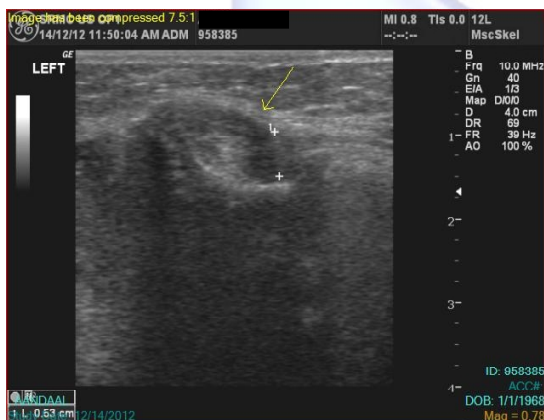Cozen's test: The subject stood with the affected elbow fully extended and forearm pronated. The therapist stabilized the subject with one hand by placing his/her thumb over lateral epicondyle. Instruction was given to make a full fist with wrist extension against resistance followed by pronation and passive radial deviation. Pain over the lateral aspect of elbow joint indicated a positive test.

Maudsley test: The Subject sat with the elbow flexed to 90° and forearm pronated. He was then asked to extend the middle finger against resi-

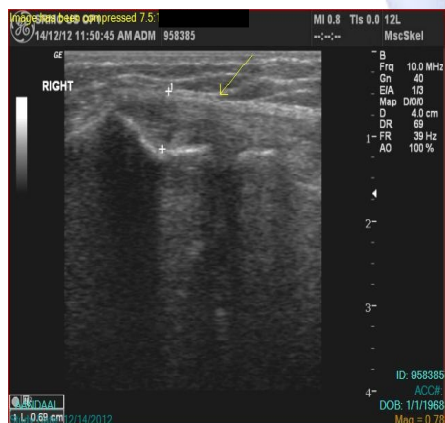
-stance. Pain over the lateral aspect elbow joint indicated a positive test.

The test results of the three provocative tests were correlated with the gold standard method i.e. musculoskeletal ultrasonography. The test results of physical examination were kept confidential with the principal investigator. The second examiner, who accompanied the subjects for Musculoskeletal Ultrasonography was blinded to the test results. All musculoskeletal ultrasonic examination was done by the same examiner who has an experience of 7 years in musculoskeletal imaging. Ultrasound machine of LOGIQ P5 of GE Company was used in which a linear transducer is used with a high frequency probe of 12MHz frequency. The subject was comfortably seated with elbow supported and flexed at 90 degrees. The scan was performed in a longitudinal fashion with the transducer over the lateral epicondyle and with the linear array parallel to the radius. The common extensor origin (CEO) was looked for tendon thickness which was compared to the uninvolved side, echotexture, presence of fluid and bony contour of lateral epicondyle for cortical irregularity.

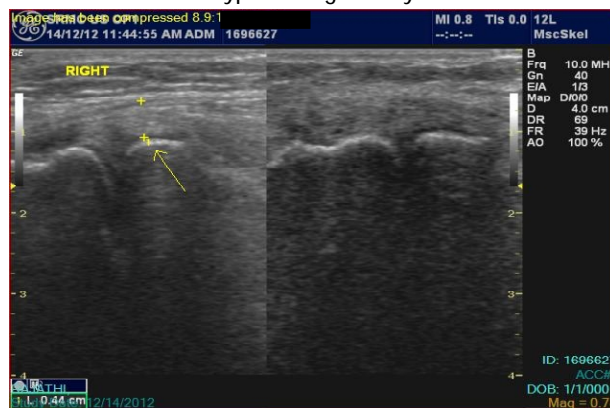
MSUS report- (i) Normal tendon thickness



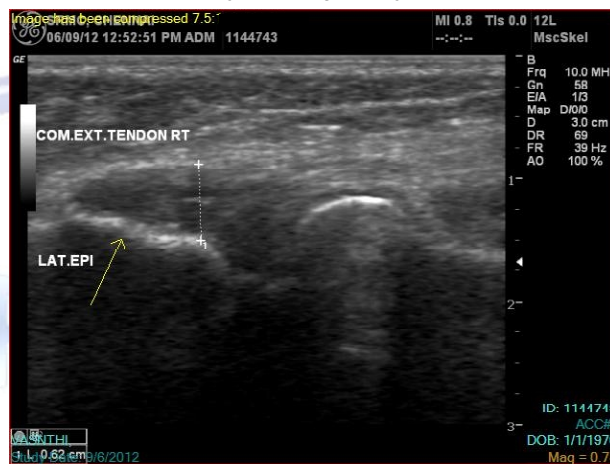
(ii)-Increase in tendon thickness(involved)



(iii) Common extensor tendon showing hyperechogenicity



(iv) Common extensor tendon showing hypoechogenicity.



Finally, the principal investigator compared the test results of physical examination with the ultrasonographic findings for diagnostic accuracy of the three provocative tests. The sensitivity, specificity, positive and negative likelihood ratios of cozen's, mills and maudsley tests were analyzed.

RESULTS

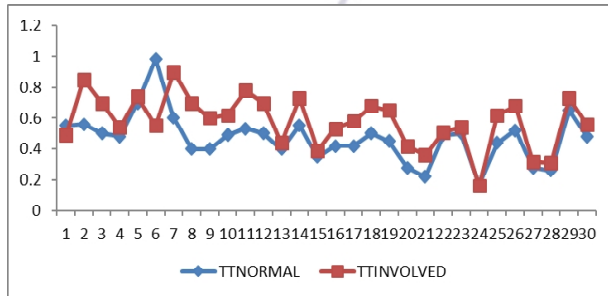
During Musculoskeletal ultrasonography subjects had a thorough examination for lateral epicondylitis by considering the parameters. The ultrasonographic findings were then compared with physical examination findings to determine the diagnostic accuracy of Cozen's, Mill's and Maudsley test in LE.

A total of 30 subjects underwent physical examination for lateral elbow pain and also musculoskeletal ultrasonography. Out of 30 subjects, males accounted for 33% and female's 67%. The mean age was 43 years. The percentage of dominant side involved was 80% and non dominant side is 20%. The mean value of pain severity was 3.6 and elbow flexion ROM

was 133 degrees and elbow extension was 0 degrees. The mean grip strength of the involved extremity was 14.5 kg. degrees and elbow extension is 0 degrees. The Mean grip strength of involved extremity is 14.5 kg.

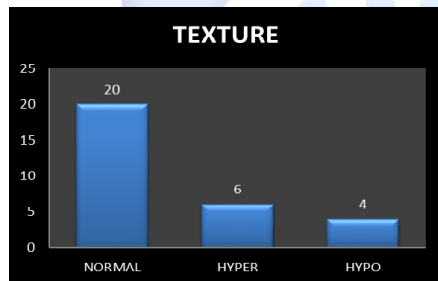
Musculoskeletal Ultrasonography findings:

Line diagram: Comparison of tendon thickness of uninvolved and elbows with LE.



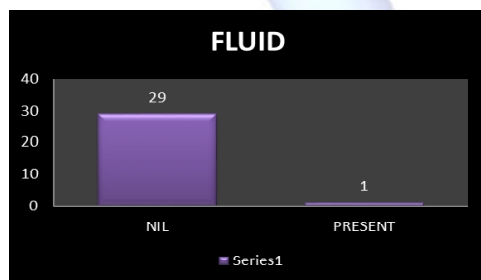
On ultrasonography, the tendon thickness varied significantly in patients who were positive for LE with a mean of .46cm of uninvolved tendon and .57cm for the involved tendon.

Graph 1: Distribution of tissue texture.

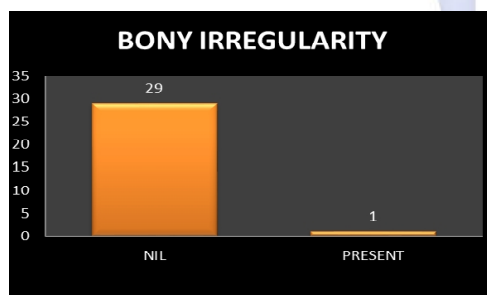


When considering the texture of the tendon, out of 30 patients 20 showed normal echotexture while 10 patients showed altered echogenecity.

Graph 2: Distribution of fluid.

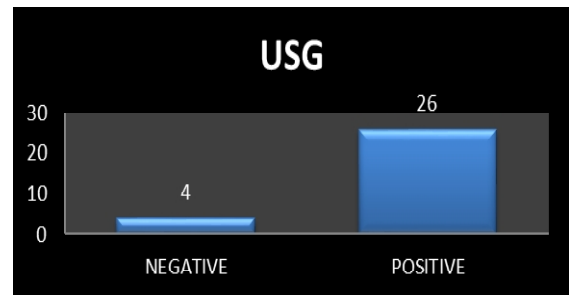


Graph 3: Distribution of bony irregularity.



Out of 30 subjects, only one exhibited fluid content and bony irregularity which denotes less number of subject's exhibit chronicity of the condition.

Graph 4: Provisional diagnosis is based on Musculoskeletal Ultrasonography.



Overall, out of 30 patients with lateral elbow pain 26 showed positive results on musculoskeletal imaging while 4 showed negative results for LE.

Diagnostic accuracy values:

Table 1: 2x2 contingency table for Cozen's test.

		USG		Total
		NEGATIVE	POSITIVE	
COZENS	NEGATIVE	0	4	4
	POSITIVE	4	22	26
Total		4	26	30

26 subjects were positive for LE and 4 were negative when tested with Cozen's test. Of those 26 subjects, 22 were positive for lateral epicondylitis on testing with ultrasonogram while the remaining 4 subjects tested negative. 4 subjects who were asymptomatic with cozen's showed positive for LE on ultrasonography.

Table 2: Diagnostic accuracy values of Cozen's test.

USG WITH COZENS	
SENSITIVITY	84%
SPECIFICITY	0
POSITIVE PREDICTIVE VALUE	84%
NEGATIVE PREDICTIVE VALUE	0
POSITIVE LIKELIHOOD	0.84
NEGATIVE LIKELIHOOD	INFINITY

The results infer that Cozen's test has a good amount of true positive rate with a sensitivity of 84% to rule out LE while the specificity of this test is 0 denoting very poor specificity. There was a positive predictive value of 84%, negative predictive value of 0 and positive likelihood ratio of 0.84 and negative likelihood of infinity.

Table 3: 2x2 contingency table for Maudsley test.

		USG		Total
		NEGATIVE	POSITIVE	
MAUDSLEY	NEGATIVE	0	3	3
	POSITIVE	4	23	27
Total		4	26	30

27 subjects tested positive for lateral epicondylitis and 3 tested negative. Out of 27 subjects, 23 were positive and 4 were negative for LE on ultrasonographic examination. Remaining 3 subjects who were negative with maudsley, tested positive for LE on ultrasonography.

Table 4: Diagnostic accuracy values of Maudsley test.

USG WITH MAUDSLEY	
SENSITIVITY	88%
SPECIFICITY	0
POSITIVE PREDECTIVE VALUE	85%
NEGATIVE PREDECTIVE VALUE	0
POSITIVE LIKELIHOOD	0.88
NEGATIVE LIKELIHOOD	INFINITY

The results infer that the Maudsley test has a good true positive rate with a sensitivity of 88% whereas it is a poorly specific test. It showed positive predictive value of 85%, negative predictive value of 0 and positive likelihood ratio of 0.88 and negative likelihood of infinity.

Table 5: 2x2 contingency table for Mill's test.

		USG		Total
		NEGATIVE	POSITIVE	
MILLS	NEGATIVE	4	12	16
	POSITIVE	0	14	14
Total		4	26	30

14 subjects were tested positive and 16 subjects tested negative for lateral epicondylitis on examination with Mills test. The 14 subjects who were positive for Mills test showed a positive correlation for LE on ultrasonography. Out of the 16 negative subjects on physical examination, 4 tested positive on ultrasonic examination.

Table 6: Diagnostic accuracy values of Mill's test.

USG WITH MILLS	
SENSITIVITY	53%
SPECIFICITY	100%
POSITIVE PREDECTIVE VALUE	100%
NEGATIVE PREDECTIVE VALUE	25%
POSITIVE LIKELIHOOD	INFINITY
NEGATIVE LIKELIHOOD	0.47

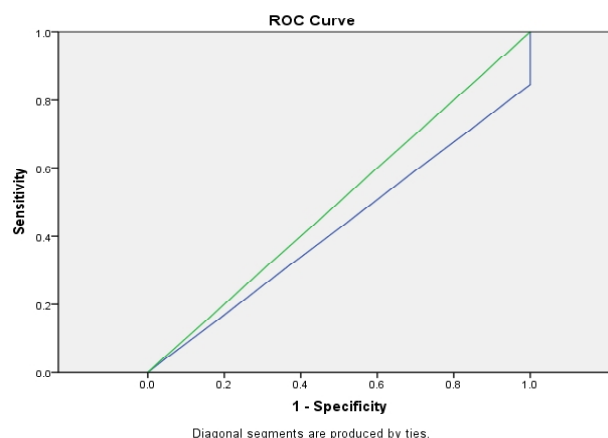
The results infer that Mills test has an average true positive rate with sensitivity of 53% to rule out LE but a very good true negative rate to rule in LE with 100% specificity. Positive predictive value of 100% and negative predictive value of 25% was seen. A positive likelihood ratio of infinity and 0.47 negative likelihood ratio. Out of the three provocative tests, Mills test showed good specificity and partial sensitivity, whereas Cozen's and Maudsley exhibited good sensitivity and poor specificity.

Receiver operator characteristic (ROC) curve:

A good test results in a ROC curve that rises to the upper left hand corner in a rapid manner. Therefore the area under the curve is the measure of the quality of the diagnostic test. Hence, larger the area, better the diagnostic value.

ROC curve for Cozen's test

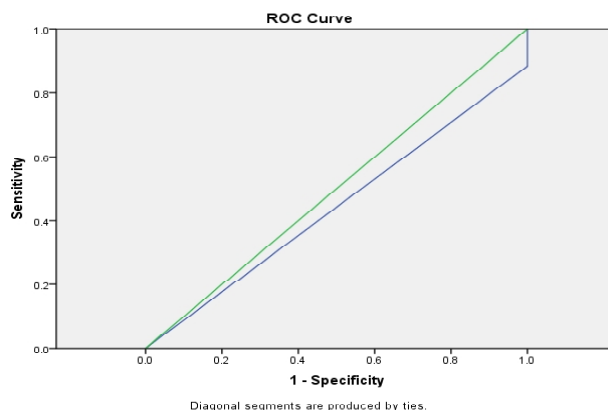
Graph 5: ROC curve for Cozen's test.



Since, the area under the curve is very less of 0.423, the cozen's test is found to have less accuracy value.

ROC curve for Maudsley test

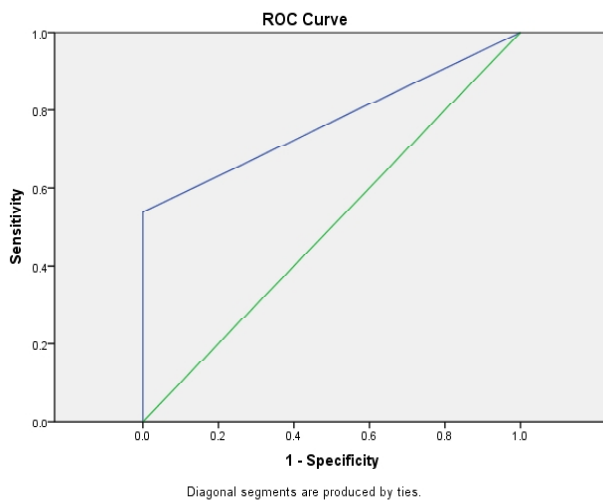
Graph 6: ROC curve for Maudsley test.



The area under the curve is 0.442 which is very less and hence the Maudsley test has lower accuracy for LE.

ROC curve for Mill's test

Graph 10: ROC curve for Mill's test.



The ROC curve for Mill's test shows significant area under curve i.e 0.769 which indicates the test has a good diagnostic accuracy for lateral epicondylitis.

DISCUSSION

The purpose of this study was to ascertain the diagnostic value of the most widely used provocative tests i.e Cozen's test, Mills test and Maudsley test in the diagnosis of lateral epicondylitis.

The study results with Cozen's test and Maudsley test indicate 84% sensitivity and 88% sensitivity respectively and 0% specificity. This infers the ability of Cozen's and Maudsley test to correctly identify subjects who do not have the disease. Out of 30 subjects, 4 tested to be negative for lateral epicondylitis on musculoskeletal ultrasonography and the above two tests were unable to identify these 4 patients as not having the disease but instead produced positive results on testing. Whereas, the ability of the test to correctly identify subjects who have the disease is 84% and 88% with respect to Cozen's and Maudsley test. Out of the 26 subjects who were diagnosed to have LE, Cozen's test showed positive result for 22 subjects and Maudsley showed positive for 23 subjects.

The diagnostic predictive value of Cozen's and Maudsley failed to show a strong tendency.

Although the positive predictive value for Cozen's is 84% and 85% for Maudsley test. The negative predictive value is 0% which implies that an individual is truly disease free when Cozen's and Maudsley show clinically negative results. In the present study, Cozen's and Maudsley failed to produce negative clinical results in 4 subjects, indicating 0% poor probability of detecting disease free.

The most valuable data was the likelihood ratio (LR). In this study the positive LR for Cozen's was 0.84 indicating that Cozen's test is .84 times more likely to be positive in the presence of disease than in the absence of disease. The negative LR for Cozen's and Maudsley is found as infinity. This suggests subjects with LE had a negative cozen's and maudsley is infinite times as often as those who did not have LE.

Considering the test results, Mills test shows 100% specificity which is a good reliable tool for identifying individuals who do not have the disease as really not having it. It also has a 50% chance of correctly identifying individuals who have the disease as positive as it has 53% sensitivity. The positive predictive value of Mills test is 100%, so the probability that the disease is present when the test result is positive is 100%. Out of 30 subjects, 14 subjects were symptomatic on Mills test and all 14 of them were diagnosed with lateral epicondylitis on musculoskeletal ultrasonography. It has 25% negative predictor value which shows that there is a 25% probability that the disease is not present when the test result is negative. Out of 16 subjects with negative Mills test only 4 showed negative results for lateral epicondylitis on ultrasonography while 12 were positive for the condition.

On the analysis of LR values, positive LR of infinity for Mills test indicates that it is infinite times more likely to be positive in the presence of disease than in its absence. It can also be stated in another way that individuals who truly have LE were infinite times as likely to have a positive Mills as those who did not have LE. With negative likelihood ratio 0.47, the negative test is .47 times less likely to be made in the presence of disease than in the absence of it. The individuals who actually have LE had negative mills examination 47% as often as

those who did not have.

The commonly used provocative tests in clinical practice are those that have both high sensitivity and specificity. A shoulder test with high psychometric properties i.e Crank test, has 83% sensitivity and 100% specificity is reported to be the most valid special test available in determining shoulder labrum pathologies. A study in 2008 analyzed diagnostic accuracy of Clarke's test in the diagnosis of chondromalacia patella assigned sensitivity of 0.39, specificity of 0.67, likelihood ratio for a positive test was 1.18, likelihood ratio for a negative test was 0.91, positive predictive value was 0.25, and negative predictive value was 0.80 was not recommended for use as a diagnostic test for any patellofemoral syndromes as its diagnostic value deemed highly susceptible.¹⁵

Hence, the above study shows that Mills test is highly significant for ruling in LE. If Mills test is positive there are 100 % chances for the individual of having the disease and thereby Cozen's and Maudsley have a high sensitivity of ruling out the lateral epicondylitis. But in the diagnosis of LE other variables such as tenderness over lateral elbow, reduced painful grip strength are also significant measures for the therapist for ruling in LE.

The limitation of the study was a limited sample size, pretest probability and post test probability was not carried out. Further, a more precise tool like MRI can be used as a gold standard in the diagnosis of LE while musculoskeletal ultrasonography could be used as an efficient tool in evaluating the efficacy of a therapeutic program.

CONCLUSION

The validation study on finding the diagnostic accuracy of provocative tests in lateral epicondylitis highlighted that Cozen's test and Maudsley test are better tests for ruling out lateral epicondylitis whereas Mills test is an excellent diagnostic test for ruling in lateral epicondylitis.

Conflicts of interest: None

REFERENCES

1. Mohamed Waseem, S. Nuhmanib, C.S. Ramc and Yadav Sachind. Lateral epicondylitis: A review of the Literature. *Journal of Back and Musculoskeletal Rehabilitation* 2012;25:131–142.
2. Christopher M Norris, *Sports Injuries: Diagnosis and Management*. 3rd edition, 2004.
3. Halle JS, Franklin RJ, Karalfa BL. Comparison of four treatment approaches for lateral epicondylitis of the elbow. *J Ortho Sports Phys Ther* 1986;8(2):62-69.
4. Smidt N, Vander Windt DA, Assendelfl WJ, Mourits AJ, Deville WL, de Winter AF, Bouter LM. Intraobserver reproducibility of the assessment of severity of complaints, grip strength, and pressure pain threshold in patients with Lateral Epicondylitis. *Arch Phys Med Rehabil* 2002 Aug;83(8) :1145 – 50.
5. Vicenzino B, Smith D, Cleland J, Bisset L. Development of clinical prediction rule to identify initial responders to movement with mobilisation and exercise for lateral epicondylalgia. *Manual therapy*. 2010 Oct;14(5):550-4.
6. Coonrad RW, Hooper WR. Tennis elbow: its course, natural history, conservative and surgical management. *J Bone Joint Surg Am* 1973; 55-A: 1177-82.
7. Tuomo Pienimäki, Tuula Tarvainen, Pertti Siira, P. Antti Malmivaara, and Heikki Vanharanta. Associations Between Pain, Grip Strength, and Manual Tests in the Treatment Evaluation of Chronic Tennis Elbow. *The Clinical Journal of Pain* 18:164–170.
8. Robert G Max, Claire Bombardier, James G. Wright. What do we know about the reliability and validity of physical examination tests used to examine the upper limb? *The Journal of Hand Surgery*; 1999 Vol 24(1):185-193.
9. Joy C Mac Dermid, Susan L, Micholovitz. Examination of the elbow: Linking diagnosis, prognosis and outcomes as a framework for maximizing therapy interventions. *Journal of Hand Therapy*; Apr 2006 vol. 19(2):82-97.
10. Joshua Cleland, *Orthopaedic clinical examination: An evidence-based approach for physical therapist*. 2nd edition, 2011.
11. Dayna Levin, Levon N. Nazarian, Theodore T. Miller, Patrick L. O'Kane, Rick I. Feld, Laurence Parker, John M. McShane. Lateral Epicondylitis of the Elbow: US Findings. *Radiology* 2005; 237:230–234.
12. Pravin Patil and Bhaskar Dasgupta. Role of diagnostic ultrasound in the assessment of musculoskeletal diseases. *Ther Adv Musculoskelet Dis*. 2012 October; 4(5): 341–355.
13. Serdar Tarhan, Zeliha Ünlü, Gülgün Yılmaz Ovalı, Yüksel Pabuçcu. Value of Ultrasonography on Diagnosis and Assessment of Pain and Grip Strength in Patients with Lateral Epicondylitis. *Turk J Rheumatol* 2009; 24: 123-30.

14. Donald D.Price,Pratricia A.McGrath,Amir Rafii and Barbara Buckingham(2003).The validation of visual analogue scales as ratio scale measures for chronic and experimental pain.Pain;Volume 17,Issue 1,pp 45-56.
15. Scott T. Doberstein; Richard L. Romeyn;David M. Reineke.The Diagnostic Value of the Clarke Sign in Assessing Chondromalacia Patella, Journal of Athletic Training2008; 43(2):190–196.

How to cite this article:

G Saroja, Antony Leo Aseer P, Venkata Sai P M. DIAGNOSTIC ACCURACY OF PROVOCATIVE TESTS IN LATERAL EPICONDYLITIS. *Int J Physiother Res* 2014;2(6): 815-823. **DOI:** 10.16965/ijpr.2014.699

