

REVIEW

Effectiveness of risankizumab in the treatment of palmoplantar psoriasis: a 52-week Italian real-life experience

Giacomo Caldarola^{1,2}, Arianna Zangrilli³, Gerardo Palmisano^{1,2}, Mauro Bavetta⁴, Gaia Moretta⁵, Gianluca Pagnanelli⁵, Vincenzo Panasiti⁶, Luca Bianchi³, Clara De Simone^{1,2}, Ketty Peris^{1,2}

¹Institute of Dermatology, Università Cattolica del Sacro Cuore, Rome, Italy; ²Fondazione Policlinico Universitario A. Gemelli IRCCS, Rome, Italy; ³Department of Dermatology, University of Rome Tor Vergata, Rome, Italy; ⁴UOC Dermatologia, Ospedale San Sebastiano, Frascati (RM), Italy; ⁵Istituto Dermopatico dell'Immacolata – IRCCS, Roma, Italy; ⁶Plastic and Reconstructive Surgery Unit, Campus Bio-Medico University, Rome, Italy

Abstract

Background: Data on the treatment of palmoplantar psoriasis (PP) are scarce, representing a therapeutic challenge. This study aims to assess the efficacy and safety of risankizumab in a population of patients with psoriasis with a palmoplantar involvement, over a 52-week treatment period.

Methods: We performed a retrospective analysis in a cohort of patients with PP, with or without involvement of other skin sites. Palmoplantar Psoriasis Area and Severity Index (ppPASI) was assessed at baseline and after 4, 16, 28 and 52 weeks, to evaluate the PP severity.

Results: Sixteen patients were enrolled. The rates of ppPASI90 responses constantly increased during the period of observation and were 18.7%, 62.2%, 75.0% and 81.2% at

weeks 4, 16, 28 and 52, respectively. Only two patients suspended treatment because of ineffectiveness at week 16.

Conclusion: Our data from a series of 16 patients reveal that risankizumab could represent an effective and safe therapeutic choice in patients with PP.

Keywords: efficacy, IL-23, psoriasis, real-life, risankizumab, safety.

Citation

Caldarola G, Zangrilli A, Palmisano G, Bavetta M, Moretta G, Pagnanelli G, Panasiti V, Bianchi L, De Simone C, Peris K. Effectiveness of risankizumab in the treatment of palmoplantar psoriasis: a 52-week Italian real-life experience. *Drugs Context*. 2023;12:2023-1-8. <https://doi.org/10.7573/dic.2023-1-8>

Introduction

Palmoplantar psoriasis (PP) consists of erythematous, hyperkeratotic plaques that may be associated with painful and disabling fissures.¹ This presentation may be the unique localization of psoriasis, accounting for 3–4% of all cases² or be associated to other site involvement. Currently, several biological treatments, in addition to first-line therapies like retinoids, methotrexate or small molecules, have been suggested as effective options. However, there are limited data on the treatment of this area since only few clinical trials have been designed to evaluate it specifically.^{3,4} Moreover,

PP is frequently resistant to therapies, making it difficult to treat.¹

Risankizumab is a humanized immunoglobulin (Ig) G1 monoclonal antibody directed against the p19 subunit of IL-23, and has been approved by the European Medicines Agency since 2019 for the treatment of moderate-to-severe plaque psoriasis in adult patients who have indication for systemic therapy or phototherapy.⁵ Several authors have already reported their experiences in real-world clinical practice, confirming its short-term and long-term effectiveness in plaque psoriasis.^{6,7} Some data have also been reported about

its effectiveness in difficult-to-treat areas, such as nails and scalp^{8,9} but few data are available regarding its use for PP.^{9–13}

The objective of this multicentre, retrospective study was to evaluate the efficacy and safety of risankizumab in a population of patients with psoriasis with palmoplantar involvement over a 52-week treatment period.

Patients and methods

We performed a retrospective analysis in a cohort of adult patients with PP, with or without involvement of other skin sites, who started treatment with risankizumab between December 2019 and February 2021. The study population was composed of patients attending the dermatological clinics of the four participating centres (Fondazione Policlinico Universitario A. Gemelli IRCCS; Università Campus Biomedico; Istituto Dermopatico dell'Immacolata – IDI; Policlinico Tor Vergata) in Lazio, Italy. Patients with pustular PP were excluded from the study, as were patients who concurrently received any other antipsoriatic systemic therapy or who received risankizumab at unscheduled dosages. For each patient, demographic and clinical data and previous therapeutic history were collected at the time of initiation of biological therapy. The severity of PP was estimated by the Palmoplantar Psoriasis Area and Severity Index¹⁴ (ppPASI) – measured at baseline and after 4, 16, 28 and 52 weeks. Standard PASI score was also recorded at the same time points in patients with other site involvement. Data were summarized using descriptive statistics (mean ± standard deviation (SD) for continuous variables and number and percentage for categorical variables). Data about potential safety issues and adverse events were also collected.

The entire study was conducted according to the principles of the Helsinki Declaration. Institutional review board approval was not required for this study because the procedures did not deviate from routine clinical practice. Informed consent was obtained.

Results

Sixteen patients were enrolled and their demographic and clinical characteristics at the beginning of treatment are summarized in Table 1. PASI and ppPASI decreased rapidly after the first 4 weeks of treatment and continued to decrease with a similar trend (Figures 1 and 2). The rates of ppPASI₉₀ responses constantly increased during the period of observation and were 18.7% (3/16), 62.2% (10/16), 75.0% (12/16) and 81.2% (13/16)

Table 1. Clinical and demographic characteristics of the study population.

Characteristics (total n=16)		n (%) (unless otherwise stated)
Sex	Male	10 (62.5)
	Female	6 (37.5)
Age, mean (SD)		47.9 (13.7)
BMI, mean (SD)		28.9 (4.6)
Comorbidities	Psoriatic arthritis	2 (12.5)
	Hypertension	4 (25.0)
	Diabetes	3 (18.7)
	Dyslipidemia	4 (25.0)
	Ulcerative colitis	1 (6.2)
	Thyroiditis	2 (12.5)
Age of onset, mean (SD)		28.8 (18.1)
Other skin site involvement	No	4 (25.0)
	Yes	12 (75.0)
Previous treatment	Phototherapy	2 (12.5)
	CyA	8 (50.0)
	Methotrexate	6 (37.5)
	Acitretin	5 (31.2)
	Etanercept	2 (12.5)
	Adalimumab	5 (31.2)
	Ustekinumab	1 (6.2)
	Secukinumab	4 (25.0)
	Ixekizumab	1 (6.2)
	Guselkumab	1 (6.2)
	Last biological treatment	Naive
Anti-TNF α		3 (18.7)
Anti-IL-17		4 (25.0)
Anti-IL-23 or anti-IL-12/23		2 (12.5)
Treatment suspension	No	14 (87.5)
	Yes	2 (12.5)
ppPASI at baseline, mean (SD)		11.1 (5.5)
PASI at baseline, mean (SD)		15.4 (9.9)

CyA, cyclosporin A; BMI, body mass index; PASI, Psoriasis Area and Severity Index, pp, palmoplantar.

at weeks 4, 16, 28 and 52, respectively. Moreover, the rates of ppPASI₁₀₀ responses were 12.5% (2/16), 56.2% (9/16), 68.7% (11/16) and 75.0% (12/16) at the same time

Figure 1. Mean PASI and ppPASI variations during the observation period (as observed analysis).

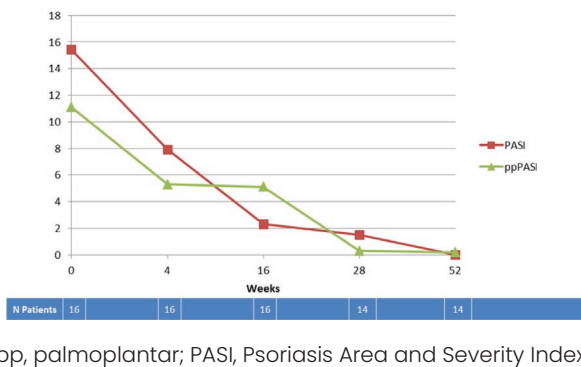
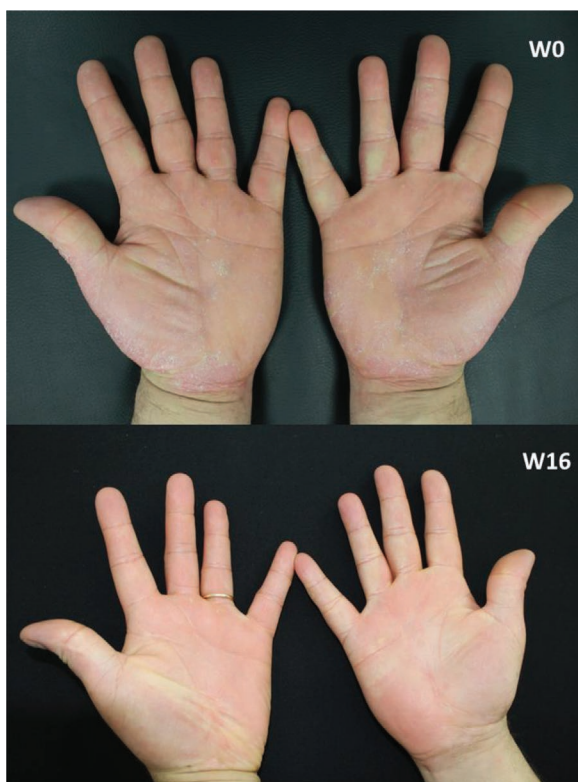

Figure 2. Clinical pictures of an enrolled patient.



W, week.

Discussion

This observational study showed that risankizumab is an effective therapeutic option for psoriasis in difficult-to-treat sites such as palms and soles. In fact, whilst previous treatments had proved largely ineffective, risankizumab induced a rapid improvement in PP as well as in concomitant plaques psoriasis in these patients. This rapidity of action is consistent with some previously published cases^{10,11} that reported an almost complete clearance of PP even after the first two drug injections. Similar data were also reported by Megna et al, who compared the efficacy of guselkumab, risankizumab and tildrakizumab in a 28-week retrospective study.¹² They found all three drugs displayed a high efficacy in palmoplantar involvement, with a body surface area reduction for risankizumab of 41.9%, 94.8% and 91.7%, respectively, at weeks 4, 16 and 28.

In our opinion, these real-life experiences are very supportive because no clinical trials ad hoc have been designed to evaluate the efficacy of risankizumab in PP and, to date, only a sub-analysis of the LIMMitless study is available.¹⁵ This sub-analysis reported a mean ppPASI improvement from baseline of >97% at week 256, with >81% of 164 patients with psoriasis with palmoplantar involvement achieving ppPASI = 0.

Although our small sample size did not permit the performance of statistical analyses nor evaluation of the impact of the clinical and demographic factors on drug response, we consider worthy of note that, in our population, more than half of patients were bio-experienced and that the drug was effective in patients with and without other skin site involvement. However, this study has several limitations in addition to the small sample size, including the retrospective design and absence of a control group. Moreover, although patients receiving any other antipsoriatic systemic therapy were not enrolled in this study, we cannot rule out the possibility that they may have applied some topical therapies. Finally, data about smoking habits were not available. Despite these limitations, we consider our experience noteworthy because it is amongst the first reported experiences with risankizumab in this subpopulation of patients with psoriasis and because of the relatively long follow-up period.

Conclusion

Our data from a series of 16 patients demonstrate that risankizumab could represent an effective and safe therapeutic option in patients affected by PP as previously reported only in few isolated cases.^{10–13} However, longer longitudinal prospective studies with larger cohorts of patients are needed to confirm these results.

points. Only 2 (12.5%) patients suspended the treatment because of ineffectiveness at week 16: one patient was bio-naïve and with other skin site involvement, and one patient had previously received secukinumab and had only PP involvement. No mild or serious safety issues occurred during the observation period, and no discontinuations related to adverse events were reported.

Contributions: All authors contributed equally to the preparation of this manuscript. All named authors meet the International Committee of Medical Journal Editors (ICMJE) criteria for authorship for this article, take responsibility for the integrity of the work as a whole, and have given their approval for this version to be published.

Disclosure and potential conflicts of interest: G Caldarola has received consulting fees, honoraria and support for attending meetings from Abbvie, Lilly, Janssen, UCB, Novartis and Leopharma; A Zangrilli has received support for consulting fees, honoraria and support for attending meetings from Abbvie; L Bianchi has received support for consulting fees, honoraria, support for attending meetings and taken part in advisory boards for Amgen, Abbvie, Novartis, Janssen-Cilag, Pfizer, UCB, Sanofi and LeoPharma; C De Simone has received support for consulting fees, honoraria and support for attending meetings from Abbvie, Lilly, Janssen, UCB, Novartis, Leopharma, Sanofi and Almiral; K Perris has received support for consulting fees and honoraria from Abbvie, Almiral, Biogen, Celgene, Fresenius Kabi, Galderma, Novartis, Lilly, Novartis, Pierre Fabre, Sandoz, Sanofi and Sun Pharma. All other authors declare that they have no conflicts of interest relevant to this manuscript. The International Committee of Medical Journal Editors (ICMJE) Potential Conflicts of Interests form for the author is available for download at: <https://www.drugsincontext.com/wp-content/uploads/2023/03/dic.2023-1-8-COI.pdf>

Acknowledgements: None.

Funding declaration: There was no funding associated with the preparation of this article.

Copyright: Copyright © 2023 Caldarola G, Zangrilli A, Palmisano G, Bavetta M, Moretta G, Pagnanelli G, Panasiti V, Bianchi L, De Simone C, Peris K. Published by *Drugs in Context* under Creative Commons License Deed CC BY NC ND 4.0, which allows anyone to copy, distribute, and transmit the article provided it is properly attributed in the manner specified below. No commercial use without permission.

Correct attribution: Copyright © 2023 Caldarola G, Zangrilli A, Palmisano G, Bavetta M, Moretta G, Pagnanelli G, Panasiti V, Bianchi L, De Simone C, Peris K. <https://doi.org/10.7573/dic.2023-1-8>. Published by *Drugs in Context* under Creative Commons License Deed CC BY NC ND 4.0.

Article URL: <https://www.drugsincontext.com/effectiveness-of-risankizumab-in-the-treatment-of-palmoplantar-psoriasis-a-52-week-italian-real-life-experience>

Correspondence: Giacomo Caldarola, Istituto di Dermatologia, Università Cattolica del Sacro Cuore, L.go F. Vito 1 00135 Roma. Email: giacomocaldarola@libero.it

Provenance: Submitted; externally peer reviewed.

Submitted: 31 January 2023; **Accepted:** 13 March 2023; **Published:** 13 April 2023.

Drugs in Context is published by BioExcel Publishing Ltd. Registered office: 6 Green Lane Business Park, 238 Green Lane, New Eltham, London, SE9 3TL, UK.

BioExcel Publishing Limited is registered in England Number 10038393. VAT GB 252 7720 07.

For all manuscript and submissions enquiries, contact the Editorial office editorial@drugsincontext.com

For all permissions, rights and reprints, contact David Hughes david.hughes@bioexcelpublishing.com

References

1. Raposo I, Torres T. Palmoplantar psoriasis and palmoplantar pustulosis: current treatment and future prospects. *Am J Clin Dermatol*. 2016;17(4):349–358. <https://doi.org/10.1007/s40257-016-0191-7>
2. Engin B, Aşkın Ö, Tüzün Y. Palmoplantar psoriasis. *Clin Dermatol*. 2017;35(1):19–27. <https://doi.org/10.1016/j.clindermatol.2016.09.004>

3. Menter A, Warren RB, Langley RG, et al. Efficacy of ixekizumab compared to etanercept and placebo in patients with moderate-to-severe plaque psoriasis and non-pustular palmoplantar involvement: results from three phase 3 trials (UNCOVER-1, UNCOVER-2 and UNCOVER-3). *J Eur Acad Dermatol Venereol*. 2017;31(10):1686–1692. <https://doi.org/10.1111/jdv.14237>
4. Gottlieb A, Sullivan J, van Doorn M, et al. Secukinumab shows significant efficacy in palmoplantar psoriasis: results from GESTURE, a randomized controlled trial. *J Am Acad Dermatol*. 2017;76(1):70–80. <https://doi.org/10.1016/j.jaad.2016.07.058>
5. Blair HA. Risankizumab: a review in moderate to severe plaque psoriasis. *Drugs*. 2020;80(12):1235–1245. <https://doi.org/10.1007/s40265-020-01357-1>
6. Caldarola G, Zangrilli A, Bernardini N, et al. Risankizumab for the treatment of moderate-to-severe psoriasis: a multicenter, retrospective, 1 year real-life study. *Dermatol Ther*. 2022;35(6):e15489. <https://doi.org/10.1111/dth.15489>
7. Torres T, Puig L, Vender R, et al. Drug survival of interleukin (IL)-17 and IL-23 inhibitors for the treatment of psoriasis: a retrospective multi-country, multicentric cohort study. *Am J Clin Dermatol*. 2022;23(6):891–904. <https://doi.org/10.1007/s40257-022-00722-y>
8. Trovato E, Cortonesi G, Orsini C, et al. Anti-IL23for nail psoriasis in real life: results of efficacy and safety during a 52-week period. *Dermatol Ther*. 2022;35(7):e15506. <https://doi.org/10.1111/dth.15506>
9. Megna M, Cinelli E, Gallo L, Camela E, Ruggiero A, Fabbrocini G. Risankizumab in real life: preliminary results of efficacy and safety in psoriasis during a 16-week period. *Arch Dermatol Res*. 2022;314(6):619–623. <https://doi.org/10.1007/s00403-021-02200-7>
10. Calabrese L, Caldarola G, Peris K, de Simone C. Severe and resistant palmar psoriasis successfully treated with risankizumab. *Ital J Dermatol Venerol*. 2022;157(1):118–119. <https://doi.org/10.23736/S2784-8671.21.06972-8>
11. Al Muqrin AM, Alghamdi AA, AlShaalan ZM. Rapid response of palmoplantar psoriasis to risankizumab: a case report. *Clin Cosmet Investig Dermatol*. 2022;15:2129–2132. <https://doi.org/10.2147/CCID.S384990>
12. Megna M, Tommasino N, Potestio L, et al. Real-world practice indirect comparison between guselkumab, risankizumab, and tildrakizumab: results from an Italian 28-week retrospective study. *J Dermatolog Treat*. 2022;33(6):2813–2820. <https://doi.org/10.1080/09546634.2022.2081655>
13. Alajlan AM, Qadoumi TA. Palmoplantar psoriasis successfully treated with risankizumab. *Cureus*. 2021;25;13(8):e17434. <https://doi.org/10.7759/cureus.17434>
14. Bissonnette R, Poulin Y, Guenther L, Lynde CW, Bolduc C, Nigen S. Treatment of palmoplantar psoriasis with infliximab: a randomized, double-blind placebo-controlled study. *J Eur Acad Dermatol Venereol*. 2011;25(12):1402–1408. <https://doi.org/10.1111/j.1468-3083.2011.03984.x>
15. Elewski BE, Crowley J, Armstrong A, et al. Efficacy and safety of long-term risankizumab treatment for nail, scalp, and palmoplantar psoriasis: a 4.5-year interim analysis from the LIMMitless open-label extension trial. Poster PI551. Presented at: 31st Congress of the European Academy of Dermatology and Venerology (EADV 2022); September 7–10, 2022; Milan, Italy.