



doi: 10.4103/2221-6189.362819

jadweb.org

Blue–green crystals: A telltale sign of poorer outcome?

Rajeev Ranjan¹, Soumya Jagannath Mahapatra², Tushar Sehgal¹✉

¹Department of Laboratory Medicine, ²Department of Gastroenterology, All India Institute of Medical Sciences, New Delhi, 110029, India

Dear editors,

Here we present the case of a 27-year-old male who came to the emergency with a high spiking fever, worsening upper abdominal pain, and shortness of breath for the last 3 weeks. Informed consent had been taken from the patient. The patient had complaints of multiple episodes of vomiting and obstipation. On examination, the patient was febrile (101 °F) with a pulse rate of 130 per minute (normal: 60-100 per minute) and blood pressure of 108/68 mmHg (normal: 120/80 mmHg). His abdomen was distended and tender on touch. The past history was significant for alcoholism for the last 10 years. There was no history of diabetes mellitus, hypertension, or coronary artery disease. Real-Time reverse transcriptase-polymerase chain reaction for COVID-19 was negative. Abdominal CT showed diffusely edematous pancreas with >50% necrosis and large walled-off necrotic collection in lesser sac extending to paracolic gutters suggestive of severe acute pancreatitis. Chest and abdominal CT showed pulmonary thromboembolism in the right main pulmonary artery, left brachiocephalic vein, and left internal jugular vein. The left lung showed consolidation with collapse and mild pleural effusion. Plasma D-dimer was >500 ng/mL (normal: <500 ng/mL). Liver function tests showed alanine transaminase of 82 U/L (normal: 5-40 U/L), aspartate aminotransferase of 156 U/L (normal: 7-55 U/L), alkaline phosphatase of 186 U/L (normal: 35-104 U/L) and lactate dehydrogenase of 650 U/L (normal: 140-280 U/L). Total bilirubin was 3.5 mg/dL (normal: 0-1.2 mg/dL) with direct bilirubin of 2.2 mg/dL (normal: 0-0.2 mg/dL). Renal function tests showed serum creatinine of 1.56 mg/dL (normal: 0.5-0.9 mg/dL) and blood urea of 84 mg/dL (normal: 17-49 mg/dL). Sepsis profile showed C-reactive protein test of 25 mg/L (normal range <3.0 mg/L) and a procalcitonin level of 38.5 ng/mL (normal range <0.1 ng/mL). Blood culture revealed growth of *Escherichia coli*. A complete blood count showed hemoglobin of 7.7 gm/dL (normal: 13-17 gm/dL), a total leucocyte count of $25.80 \times 10^9/L$ (normal: $4-11 \times 10^9/L$), and a platelet count of $110 \times 10^9/L$ (normal range $150-450 \times 10^9/L$). The absolute neutrophil counts were $23.22 \times 10^9/L$ (normal range:

$2-7 \times 10^9/L$). Peripheral blood film revealed unusual-looking blue-green inclusions in cytoplasm of neutrophils (Figure 1). Literature search revealed blue-green cytoplasmic inclusions in neutrophils and monocytes (less common), a rare occurrence. They were first documented by Harris *et al*[1]. These rare inclusions are refractile and irregular in shape reported originally in patients with fulminant

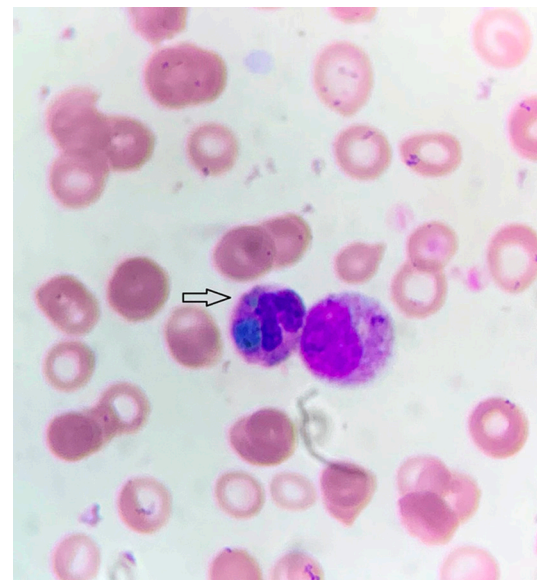


Figure 1. Photomicrograph of a 27-year-old male patient showing “blue-green” crystals in the cytoplasm of a neutrophil (arrow). Also seen is a myelocyte to the right of the neutrophil (Leishman-Giemsa $\times 1000$).

✉To whom correspondence may be addressed. E-mail: doctusharsehgal@yahoo.co.in

This is an open access journal, and articles are distributed under the terms of the Creative Commons Attribution-NonCommercial-ShareAlike 4.0 License, which allows others to remix, tweak, and build upon the work non-commercially, as long as appropriate credit is given and the new creations are licensed under the identical terms.

For reprints contact: reprints@medknow.com

©2022 Journal of Acute Disease Produced by Wolters Kluwer- Medknow.

How to cite this article: Ranjan R, Mahapatra SJ, Sehgal T. Blue-green crystals: A telltale sign of poorer outcome?. J Acute Dis 2022; 11(6): 254-255.

Article history: Received 17 October 2022; Revision 21 October 2022; Accepted 21 November 2022; Available online 10 December 2022

hepatic injury[2]. Smith *et al.* in 1967 described a case of an infant who died at 7 months of age due to biliary cirrhosis caused by congenital atresia of the bile ducts was noted to have dull green, circular or oval inclusions in the cytoplasm of granulocytes and monocytes[3]. Various studies have shown that these crystals can also occur in patients with tissue injury other than the liver, and patients with multiorgan failure. On cytochemical analysis the crystals have been found to be negative for bile stains, iron or myeloperoxidase, periodic acid-Schiff, Warthin-Starry, Gomori methenamine silver, and Gram stains[2]. It is now thought that these crystals contain lipofuscin-like deposits representing lysosomal degradation products, and may be present in multiple types of tissue injury[2]. They usually indicate a poor prognosis and are also called “green crystals of death” or “death crystals.” In published reports, it has been shown that mortality in patients with these crystals is about 60%[2].

Our patient was a young male who was diagnosed with acute pancreatitis and pulmonary thromboembolism with sepsis and blue-green inclusions in blood cells. He was started on non-invasive ventilatory support with broad-spectrum antibiotics and anticoagulant therapy. The patient however succumbed on day 3 of admission due to septic shock. Our case serves to remind clinicians that the presence of blue-green inclusion bodies on the peripheral blood film of critically ill patients might be utilized as a predictor of mortality.

Conflict of interest statement

The authors report no conflict of interest.

Funding

This study received no extramural funding.

Authors' contributions

RR, SJM and TS contributed equally to the idea, design, literature search, editing and final approval of the manuscript.

References

- [1] Harris VN, Malysz J, Smith MD. Green neutrophilic inclusions in liver disease. *J Clin Pathol* 2009; **62**(9): 853-854.
- [2] Yang J, Gabali A. Green neutrophilic inclusions: Current understanding and review of literature. *Curr Opin Hematol* 2018; **25**(1): 3-6.
- [3] Smith H. Unidentified inclusions in haematopoietic cells, congenital atresia of the bile ducts and livedo reticularis in an infant: A new syndrome. *Br J Haematol* 1967; **13**(5): 695-705.

Publisher's note

The Publisher of the *Journal* remains neutral with regard to jurisdictional claims in published maps and institutional affiliations.