

EFFECTS OF ANTIOXIDANTS CONSUMPTION AND LOW PROTEIN DIETS ON LIVER AND INTESTINE HISTOPATHOLOGY AND PERFORMANCE OF JAPANESE QUAILS (*COTURNIX COTURNIX JAPONICA*)

¹JAFARGOLIPOUR, Mohammadali, ²VAHDATPOUR, Tohid, ³MAHMOODPOUR, Hamid and ³VAHDATPOUR, Sina

¹Department of Research and Development, Razi Vaccine and Serum Research Institute, Agricultural Research Education and Extension Organization (AREEO), Marand, Iran.

²Department of Animal Sciences, Faculty of Animal and Veterinary Sciences, Shabestar Branch, Islamic Azad University, Shabestar, Iran.

³Faculty of Veterinary Medicine, Tabriz Branch, Islamic Azad University, Tabriz, Iran.

Corresponding Author: Vahdatpour, S. Faculty of Veterinary Medicine, Tabriz Branch, Islamic Azad University, Tabriz, Iran. **Email:** sinavahdatpour@gmail.com **Phone:** +984114777840

ABSTRACT

The study investigated the effects of two types of antioxidants, a natural antioxidant (E-selenium) and a synthetic antioxidant (loxidan) in diets containing protein value lower than essential requirements, on performance and histopathological changes in the liver and intestine of Japanese quails. The experimental diets were: Group A – basal diet (control), Group B – 15 % crude protein reduction without recommended antioxidant, Group C – 15 % crude protein reduction plus 1 g/kg E-selenium, Group D – 15 % reduction in crude protein plus 0.2 g/kg loxidan, Group E – 30 % reduction in crude protein without recommended antioxidant, Group F – 30 % reduction in crude protein plus 1 g/kg E-selenium. Group G - 30 % reduction in crude protein plus 0.2 g/kg loxidan. Birds in groups B and E showed a significant reduction ($p<0.05$) in body weight compared to the control group. Birds fed E-selenium and loxidan exhibited significantly better ($p<0.05$) body weights compared to the birds in groups D and F groups. Birds in group E fed with 30 % reduction in the dietary protein had significantly higher ($p<0.05$) liver weights. The relative weight of the intestine decreased in the birds in groups B and E compared to the control group. 15 and 30 % reduction in dietary protein intake of birds caused mild hyperemia and edema of the intestine. The severity of liver congestion and edema were lower in group E birds when compared with birds in group B. Results indicated that the used of two kinds of antioxidants (natural and synthetic) effect on the performance parameters of Japanese quails which were exposed to nutritional stresses (such as reducing dietary protein) compensated parts of the adverse effects. Therefore, antioxidants intake is useful for recovery of quails performance fed low-protein diets.

Keywords: E-Selenium, Loxidan, Intestine, Liver, Performance, Protein, Quail

INTRODUCTION

Proteins and amino acids have various biological functions, including the biosynthesis of tissues and thus resulting in diverse economic products in farm animals. The importance of protein in feed formulation is more evident because it is the most costly nutrient in animal diets. The dietary crude protein (CP) requirement is high in

modern broiler strains as a result of their fast growth rates (Abbasi *et al.*, 2014). Because of high costs and prices of protein ingredients, poultry industries feed manufacturers try to reduce dietary protein cost as far as it does not affect the poultry produced. In animals, dietary protein reduction decreased plasma proteins and increased the destructive reactions of free radicals, which can be prevented by antioxidant

consumption (Surai, 2007). The oral administration of antioxidants has been demonstrated to reduce negative effects of reduced protein diets. The body's antioxidant system has the ability to prevent both damaging effects of free radicals and toxic products of their metabolism. The liver acts as a barrier or filter between the digestive system and the rest of the body and has an essential role in the metabolism of many chemicals and toxic substances entering the organism through the gastrointestinal system (Holoovská *et al.*, 2013). During the last few years, attempts have been made to use low-CP diets supplemented with synthetic amino acids for broiler chicks. Poultry producers are interested in using low-protein diets to minimize feed cost and the amount of nitrogen (N) excreted in litter (Tarasewicz *et al.*, 2007; Kamran *et al.*, 2008; Kamran *et al.*, 2010). Nevertheless, reduced protein diets results in negative effects such as a decrease in the rate and efficiency of growth and carcass proteins, as well as an increase in carcass fat contents, etc. (Kamran *et al.*, 2008). Additionally, a decrease in serum proteins, resulting from reduced protein diets, leads to elevated free radical activities (Surai, 2007) (Figure 1).

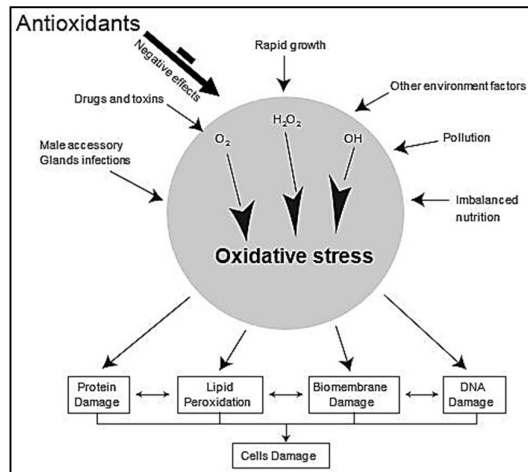


Figure 1: The effects of oxidants and antioxidants on poultry tissues including liver and intestine (Surai, 2007)

Dietary proteins protect quails against damaging effects of aflatoxins and other possible side effects. Because of their ability to reduce damaging effects of aflatoxins, antioxidants

compensate for the lack of proteins in quail diets (Kamran *et al.*, 2010).

In the present study, the efficacy of E-selenium (a combination of vitamin E and selenium) and Loxidan (a combination of ethoxyquin (E 324), propyl gallate (E 310) and citric acid (E 330)) was evaluated as natural and synthetic antioxidants consumption, respectively in diets with different low levels of protein on the performance and histopathology of liver and intestine of Japanese quails.

MATERIALS AND METHODS

Experimental Design and Housing: A total of 252 one day-old Japanese quail chicks, mean body weight 7.78 ± 0.39 g, that were randomly assigned in 21 pens with 12 birds per pen and each bird occupied 0.015 m^2 of wiry floor space. The pens (Figure 2) were randomized with respect to feed additives.



Figure 2: Experimental layout used for Japanese quail study (Tabriz-Iran)

The temperature was maintained at 35°C for the first 5 days and then gradually reduced according to normal management practices until a temperature of 22°C was achieved. Continuous lighting except for 2 hours of darkness a day was maintained during the experimental period (2.5 watt/m^2).

Treatments and Additives: The experimental design was a completely randomized design (CRD) of 7 treatments and 3 replicates for each treatment. Nutrients compositions of the quail's diets at 1 to 45 days old were based on the National Research Council (NRC, 1994) recommendations (Table 1).

Table 1: Ingredient and proximate composition of low protein experimental diets fortified varied levels of antioxidants fed to Japanese quails

Ingredients*	Starter 1 – 28 days	Starter (15 % reduction in protein)	Finisher 29 – 45 days	Finisher (30 % reduction in protein)
Corn grain	46	57.1	51.6	60.3
Soybean meal	46.7	36.1	36.0	27.5
Oyster shell	2.0	2.2	6.0	6.3
Di-calcium phosphate	2.0	2.2	2.0	2.2
Sunflower oil (without antioxidant)	2.5	1.3	3.5	2.6
DL-Methionine	0.3	0.4	0.4	0.5
L-Lysine	0.0	0.2	0.0	0.1
Salt	0.5	0.5	0.5	0.5
Total (%)	100	100	100	100
Nutrients				
Metabolizable energy (Kcal/Kg)	2920	2920	2920	2920
Crude protein (%)	24.5	20.8	20.3	17.3
Calcium (%)	1.4	1.4	3.0	3.0
Total phosphorous (%)	0.7	0.7	0.6	0.6
Methionine (%)	0.6	0.6	0.6	0.6
Lysine (%)	1.3	1.3	0.9	0.9

*To prevent the entry and intervention of other antioxidants such as vitamins A and E, and others in the basal diet, vitamin and mineral premix was not used

The experimental birds were divided randomly into seven groups [A – G]. Group A birds were fed basal diet without additive, group B birds were fed basal diet with 15 % reduction in protein without antioxidant, group C birds were fed basal diet with 15 % reduction in protein containing E-selenium at a level of 1 g/kg, group D birds were fed basal diet with 15 % reduction in protein containing loxidan at level of 0.2 g/kg, group E birds were fed with basal diet with 30 % reduction in protein without antioxidant, group F birds were fed with basal diet with 30 % reduction in protein containing E-selenium at a level of 1 g/kg and group G birds were fed basal diet with 30 % reduction in protein containing Loxidan at the level of 0.2 g/kg. Diets and water were given *ad libitum*.

Measurements and Preparation of Samples: At the end of the experimental period (45 days), feed intake (FI), body weight (BW) and feed conversion ratio (FCR) were calculated for all the birds in the various dietary treatments. Before slaughtering the final BW of each bird was measured and after slaughtering the weights of the liver and intestine were measured, recorded and presented as a percentage of live BW.

Slaughtered birds at 45 days of age were drained of blood and all abdominal contents and entrails were removed, weighted and relative weight expressed as percent of BW. Tissue samples of 3 – 5 mm thick from the liver and intestine were fixed in 10 % neutral buffered formalin and histopathological processed using routine paraffin embedding technique. Sections of 5 µm thickness were cut, stained using Hematoxylin and Eosin (H&E), and examined under light microscope (Bancroft *et al.*, 1994). Slides were examined with Olympus light microscope at x400 magnification. Photomicrographs of representative organ were taken using Motic camera.

Statistical Analysis: The experimental data on performance were analyzed using analysis of variance (ANOVA) and general liner model (GLM) procedures of SAS (2001). The level of the significance was fixed at $p < 0.05$. Treatment means were compared using Duncan’s new multiple range test at $p < 0.05$ (Duncan, 1955). The histopathological data were compared descriptively.

RESULTS AND DISCUSSION

Performance Investigation: The data on the effects of two different types of antioxidants that were added to low-protein basal diets on growth performance of Japanese quails are presented in Table 2.

Feed Intake: The analysis of variance showed that there was no significant difference ($p>0.05$) between FI treatment means. It can be concluded that the consumption of natural and synthetic antioxidants had no significant change in the amount of feed consumed. This result was in agreement with the study of Attia *et al.* (2006) that reported no significant interaction between distilled fatty acids level and antioxidants (E-selenium) in FI of Japanese quail males. Tarasewicz *et al.* (2007) reported that the reduction of dietary protein reduced FI and increased the FCR in Japanese quail. The antioxidant compounds of the body prevent the damaging effects of free radicals. The serum protein reduction due to dietary protein reduction is one of the reasons for increasing free radicals activities which could be one of the reasons of reduced performance due to low protein intake (Surai, 2007).

Feed Conversion Ratio: Data from the present study indicated that the best FCR occurred in birds fed the control diet. 3.3 g/g antioxidant consumption with low-protein diets could not improve FCR. Also in group D birds, FCR significantly increased ($p<0.05$) which is a disadvantageous indicator for the poultry industry. Dietary protein protects quails against the adverse effects of aflatoxins. Also, it is already known that one of the effects of antioxidants is reducing the adverse effects of aflatoxins. So the antioxidants can ameliorate for the effect of low-protein diet intake in birds (Surai *et al.*, 2002; Kamran *et al.*, 2010). However, much more research is needed. Tarasewicz *et al.* (2007) had earlier reported that the reduction of total protein level in diet decreased total amount of feed consumed in broiler chickens. Whereas Jamros *et al.* (1981) and Swierczewska *et al.* (2000) did not report

any change in FCR of broiler chicken fed low protein diets.

Body Weight: BW is an important indicator of production, and lighter birds on the average produced the lowest meat and egg mass, because this class would include mainly more unhealthy birds than the heavier birds (Singh and Nordskog, 1982). In the present study, BW of birds fed the control diet were significantly heavier ($p<0.05$) than those of birds in other groups. Moreover, birds in groups C and G showed significant increase ($p<0.05$) in BW when compared to birds in groups B, D and E, which were similar to the control group. Based on this study, dietary protein level is an effective factor in final BW. Lower levels of dietary protein reduced final BW but considerable amount of weight loss could be prevented by adding natural and synthetic antioxidants. Hashiguchi and Yamamoto (2006) reported that feeding quails with low protein rations caused weight loss and delayed sexual maturity. In this study, no significant differences ($p>0.05$) were observed between consumption by 24 and 19 % crude protein for the 56 days experimental period, but consumption of 14 % crude protein significantly decreased BW compared to other treatments. Ipek *et al.* (2007) showed that consumption of vitamins C and E increased the weight of the Japanese quail under heat stress. The BW of birds in the group that received 60 mg vitamin E and 60 mg vitamin C were lower than the BW of birds that received 240 mg vitamin E and 240 mg vitamin C (Table 2).

Entrails Weight: Reduction of dietary protein did not significantly change the entrails weights and the addition of natural and synthetic antioxidants did not significantly change ($p>0.05$) entrails weights (Table 2).

Liver Relative Weight: The present study demonstrated that 30 % reduction in dietary protein significantly increased ($p<0.05$) liver weight compared to control group and group B. Also liver relative weight showed a significant increase with increased antioxidants consumption probably due to the increased activity of the liver.

Table 2: Growth performance values and internal organs weights of Japanese quails fed low protein experimental diets fortified varied levels of antioxidants for 45 days

Groups	Feed intake (g)	Feed conversion ratio (g/g)	Body weight (g)	Entrails weight (%)	Liver weight (%)	Intestine weight (%)
A	587 ± 41.12	3.30 ± 0.15 ^c	178 ± 11.21 ^a	7.52 ± 0.41	1.64 ± 0.11 ^b	3.11 ± 0.21 ^a
B	595 ± 35.00	3.42 ± 0.19 ^b	174 ± 14.35 ^b	7.23 ± 0.57	1.66 ± 0.14 ^b	2.73 ± 0.19 ^b
C	601 ± 34.52	3.38 ± 0.09 ^b	177 ± 19.21 ^a	7.74 ± 0.44	1.89 ± 0.17 ^{ab}	2.70 ± 0.11 ^b
D	617 ± 43.92	3.59 ± 0.21 ^a	172 ± 19.21 ^{bc}	7.81 ± 0.31	2.15 ± 0.18 ^a	2.76 ± 0.19 ^b
E	584 ± 49.98	3.42 ± 0.18 ^b	171 ± 22.56 ^{bc}	7.63 ± 0.57	2.00 ± 0.14 ^a	2.55 ± 0.11 ^c
F	570 ± 41.32	3.41 ± 0.14 ^b	168 ± 16.22 ^c	7.53 ± 0.55	1.96 ± 0.11 ^a	2.54 ± 0.19 ^c
G	605 ± 38.85	3.44 ± 0.15 ^b	176 ± 12.32 ^{ab}	7.32 ± 0.47	2.03 ± 0.12 ^a	2.50 ± 0.16 ^c

Means ± standard deviation within each row with no common superscript differ significantly ($P < 0.05$)

It is worth noting that highest liver weight was observed in group D. Attia *et al.* (2006) reported that adding vitamin E-selenium to a diet containing 3 and 6 % of volatile fatty acid (VFA) showed a non-significant decreased in liver relative weight compared to a diet containing E-selenium without VFA. The result of Attia *et al.* (2006) was in disagreement with the present study.

Intestine Relative Weight: The average weight of intestines in experimental treatments were significant ($p < 0.05$). Relative weight of intestine in group a birds was the highest among the treatment groups. By reducing dietary protein level in groups B and E, intestine weight significantly decreased compared to control group. In addition, groups E, F and G compared with groups B, C and D had significant numerical decline, but antioxidants consumption could not affect weight loss. Reduction in dietary protein had effect on tissues weight and relative weight of the intestine. These tissues for their cell turnover had a greater need for protein. However, intestine enterocytes were replaced within 2 – 3 days (Nasrin *et al.*, 2012). In reovirus-challenged broilers, selenium caused a significant increase in intestine relative weight in affected birds (Ednes *et al.*, 2009).

Histopathology

Histopathological Changes in the Liver: Significant histopathological changes were observed in the liver cell of birds from the different groups. The structure of liver was normal in group A (Figure 3).

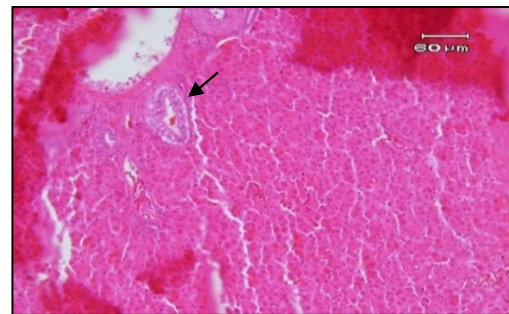


Figure 3: Photomicrograph of liver of quail from Group A showing mild hyperemia and bile retention in bile duct. H & E x200

Hepatocytes in group a birds had normal histological features. The cellular fatty changes were observed in the hepatocytes of birds from groups B, D, F and G. Cellular fats was more severe in groups C and E. Moreover, necrotic changes were not observed in the hepatocytes. Hyperemia and edema were observed in all groups liver parenchyma, but the majority of lesions was seen in groups A, B and C. Group E showed less damage compared to groups A and B. By adding E-selenium, edema and hyperemia reached lowest levels in group F (Figure 4).

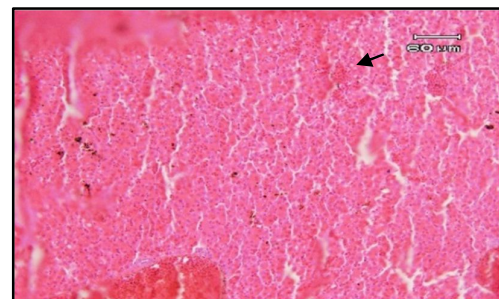


Figure 4: Photomicrograph of liver of quail from Group G showing sever hyperemia, sinusoid accumulation of RBC and fatty acid. H & E x200

Importantly, histopathology proved to be a more sensitive method to detect liver tissue damage than biochemical measurement of lipid peroxidation (Osičková *et al.*, 2014). The liver is a major detoxifying organ and the main source of reactive oxygen species (ROS) generation in birds. Therefore, it is the first organ to be damaged (Paskova *et al.*, 2011; Vitula *et al.*, 2011). Japanese quail is susceptible to fatty liver hemorrhagic syndrome (FLHS) and a combination of lipotropic and antioxidant nutrients are protective against liver hemorrhage (Spurlock and Savage, 1993). A study by Holovská *et al.* (2013) showed that in the Turkey, elemental zinc as an antioxidant had a protective effect against the harmful effects of cadmium on the liver cells. Nowadays, E-selenium consumption is suggested as a protective factor which protects the liver, heart and aorta against the risks of obesity in rats fed high-fat diets (Attia *et al.*, 2012).

Histopathological Changes in the Intestinal cells: Present study indicated that reducing dietary protein at levels 15 and 30 % caused no significant change in intestine histopathological criteria. According to previous studies, there were not any standard and specific criteria to classify the severity of lesions. The gastrointestinal tissues have relatively high turnover rate and high-protein diets provide adequate nutrient for basal metabolism and development of intestinal structure. Among group a birds, the structure of intestinal tissue was normal, although mild hyperemia and edema were observed only in one of the replications. Reducing dietary protein from 15 to 30 % did not change intestinal tissue (Figure 5). On the other hand, antioxidant consumption had no particular positive impact on intestine morphology. Observation showed that E-selenium and Loxidan consumption had no positive impact on intestinal tissue. In an investigation Ednes *et al.* (2009) reported that selenium had major impact on the intestinal morphology of Reovirus challenged broilers which increase nutrients absorption from the intestine. Also revealed that using diets with and without selenium compared to the diet containing sodium selenite increased perimeters

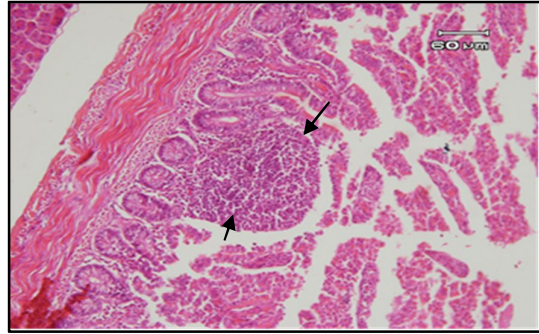


Figure 5: Photomicrograph of intestine of quail from Group G showing normal tissue. In the center of picture was an accumulation of lymphocytes that naturally occur in the intestine of birds. H & E $\times 200$

and heights of intestinal villi, which are not in accordant with the present study. Abbasi *et al.* (2014) reported that reduction of dietary crude protein level resulted in a significant decrease in villus height and crypt depth in jejunal epithelial cells, but the supplementation of low-crude protein diets with threonine up to 110 and 120 % of the recommended values resolved these changes. Except for the starter period, reducing dietary crude protein level to 90 % of recommendations had no harmful effects on performance parameters; however, the best values were obtained with diets containing 110 % threonine. Witaicenis *et al.* (2014) reported the intestinal anti-inflammatory activity of coumarin derivatives were related to their antioxidant properties, suggesting that consumption of coumarin and/or foods rich in coumarin derivatives, particularly daphnetin, esculin and scoparone could prevent intestinal inflammatory disease.

Conclusion: The results of the present study showed that the consumption of both antioxidants (E-selenium and Loxidan) in the Japanese quails, improve liver abnormalities on a lower protein diet. The consumption of natural antioxidant improved performance indexes (FBW as well as FCR) in Japanese quails fed low protein diets. Also loxidan consumption as a synthetic antioxidant improved final body weight in low protein diet at 30 percent level. The effects of antioxidants on blood parameters and gastrointestinal enzymes in the low protein diet should be a focus of further studies.

ACKNOWLEDGEMENTS

This paper was summarized from DVM thesis of Dr. Mohamadali Jafargholipour. We thanks and appreciate colleagues from the Shabestar Branch and Tabriz Branch, Islamic Azad University.

REFERENCES

- ABBASI, M. A., MAHDAVI, A. H., SAMIE, A. H. and JAHANIAN, R. (2014). Effects of different levels of dietary crude protein and threonine on performance, humoral immune responses and intestinal morphology of broiler chicks. *Brazilian Journal of Poultry Science*, 16(1): 35 – 44.
- ATTIA, H. F., SOLIMAN, M. M. and ISMAIL, T. A. (2012). Protective effect of vitamin E and selenium on the liver, heart and aorta. *Journal of Veterinary Anatomy*, 5(1): 17 – 29.
- ATTIA, Y. A., ABD-EL-HAMID, A. E., ABD-EL-GHANY, F. A. and HABIBA, H. I. (2006). Effect of oil source and antioxidant supplementations on growth performance and meat quality of Japanese quail males. *In: Proceedings of the EPC 2006 XII European Poultry Conference*, Verona, Italy.
- BANCROFT, J. D., COOK, H. C. and TURNER, D. R. (1994). *Manual of Histological Techniques and Their Diagnostic Application*. 2nd Edition, Churchill Livingstone, London, WC1X 8RW, United Kingdom.
- DUNCAN, D. B. (1955). Multiple range and multiple F test. *Biometrics*, 11: 1 – 42.
- EDNES, F. W., READ-SNYDER, J., CANTOR, A. H., PESCATORE, A. J. and PIERCE, J. L. (2009). Effect of dietary selenium on small intestine villus integrity in reovirus-challenged broilers. *International Journal Poultry Science*, 8(9): 829 – 835.
- HASHIGUCHI, M. and YAMAMOTO, Y. (2006). Effect of dietary protein levels on body growth and carcass fat and protein deposition in female Japanese quail. Pages 269 – 272. *In: Proceeding of 12th European Poultry Conference*, Verona, Italy.
- HOLOVSKÁ, K., SOBEKOVÁ, A., ALMÁŠIOVÁ, V. and CIGÁNKOVÁ, V. (2013). Morphological changes in the liver and the response of antioxidant enzymes after turkeys' chronic exposure to cadmium. *Polish Journal of Environmental Studies*, 22(5): 1371 – 1379.
- IPEK, A., CANBOLAT, O. and KARABULUT, A. (2007). The effect of vitamin e and vitamin c on the performance of Japanese quails (*Coturnix coturnix japonica*) reared under heat stress during growth and egg production period. *Asian-Australian Journal of Animal Science*, 20(2): 252 – 256.
- JAMROS, D., SCHLEICHER, A. and FRITZ, Z. (1981). Lowering of total protein level by about 30 % in complete feed mixes for broilers when applying supplements of synthetic amino acids. *Roczniki Naukowe Zootechniki*, 8: 209 – 219.
- KAMRAN, Z., SARWAR, M., MUKHTAR, N., NADEEM, M. A. and MAHMOOD, S. (2010). Effect of low levels of dietary crude protein with constant metabolizable energy on nitrogen excretion, litter composition and parameters of broilers. *International Journal of Agriculture and Biology*, 14: 401 – 405.
- KAMRAN, Z., SARWAR, M., NISA, M., NADEEM, M. A., AHMAD, S., MUSHTAQ, T., AHMAD, T. and SHAHZAD, M. A. (2008). Effect of lowering dietary protein with constant energy to protein ratio on growth, body composition and nutrient utilization of broiler chicks. *Asian-Australian Journal of Animal Science*, 21(11): 1629 – 1634.
- NASRIN, M., SIDDIQI, M. N. H., MASUM, M. A. and WARES, M. A. (2012). Gross and histological studies of digestive tract of broilers during postnatal growth and development. *Journal of Bangladesh Agricultural University*, 10(1): 69 – 77.
- NRC (1994). *Nutrition Requirements of Poultry*. National Research Council, National Academy Press, USA.

- OSIČKOVÁ, J., BANDOUCHOVÁ, H., KOVÁČOVÁ, V., KRÁL, J., NOVOTNÝ, L., ONDRÁČEK, K., POHANKA, M., SEDLÁČKOVÁ, J., ŠKOCHOVÁ, H., VITULA, F. and PIKULA, J. (2014). Oxidative stress and liver damage in birds exposed to diclofenac and lead. *Acta Veterinaria Brno*, 83(4): 299 – 304.
- PASKOVA, V., PASKEROVA, H., PIKULA, J., BANDOUCHOVA, H., SEDLACKOVA, J. and HILSCHEROVA, K. (2011). Combined exposure of Japanese quails to cyanotoxins, Newcastle virus and lead: oxidative stress responses. *Ecotoxicology and Environmental Safety*, 74(7): 2082 – 2090.
- SAS (2001). *SAS User's Guide: Statistic*. Version 8.2, SAS Institute incorporated, Cary, NC, USA.
- SINGH, H. and NORDSKOG, A. W. (1982). Significance of body weight as a performance parameter. *Journal of Poultry Science*, 61(10): 1933 – 1938.
- SPURLOCK, M. E. and SAVAGE, J. E. (1993). Effect of dietary protein and selected antioxidants on fatty liver hemorrhagic syndrome induced in Japanese quail. *Poultry Science*, 72(11): 2095 – 2105.
- SURAI, P. F. (2007). Natural antioxidants in poultry nutrition: New developments. Pages 669 – 675. *In: Proceedings of the 16th European Symposium on Poultry Nutrition*, Strasbourg, France, 26 – 30 August 2007.
- SURAI, P. F., DVORSKA, J. E., SPARKS, N. H. C. and JACQUES, K. A. (2002). Impact of mycotoxins on the body's antioxidant defense. Pages 131 – 141. *In: LYONS, T. P. and JACQUES, K. A. (Editors), Nutritional Biotechnology in the Feed and Food Industries*. Nottingham University Press, United Kingdom.
- SWIERCZEWSKA, E., NIEMIEC, J., MROCZEK, J., SIENICKA, A., GRZYBOWSKA, A. and GROCHALSKA, A. (2000). The effect of feeding chickens with feed mixes with different protein content on production results, carcass tissue content and meat chemical composition. *Zeszyty Naukowe Przeglad Hodowlany*, 49: 365 – 375.
- TARASEWICZ, Z., GARDZIELEWSKA, J., SZCZERBIŃSKA, D., LIGOCKI, M., JAKUBOWSKA, M. and MAJEWSKA, D. (2007). The effect of feeding with low protein feed mixes on the growth and slaughter value of young male Pharaoh Quails. *Archiv fur Tierzucht*, 50(5): 520 – 530.
- VITULA, F., PECKOVA, L., BANDOUCHOVA, H., POHANKA, M., NOVOTNY, L., JIRA, D., KRÁL, J., ONDRACEK, K., OSICKOVA, J., ZENDULKOVA, D. and ROSENBERGOVA, K. (2011). Mycoplasma gallisepticum infection in the grey partridge *Perdix perdix*: outbreak description, histopathology, biochemistry and antioxidant parameters. *BMC Veterinary Research*, 7(1): 34.
- WITAICENIS, A., SEITO, L. N., DA SILVEIRA CHAGAS, A., DE ALMEIDA, L. D., LUCHINI, A. C., RODRIGUES-ORSI, P., CESTARI, S. H. and DI STASI, L. C. (2014). Antioxidant and intestinal anti-inflammatory effects of plant-derived coumarin derivatives. *Phytomedicine*, 21(3): 240 – 246.