



doi: 10.4103/2221-6189.312215

jadweb.org

## “Triple-positive” renal limited vasculitis presenting with rapidly progressive glomerulonephritis: A case report

Amol Andhale<sup>1</sup>✉, Amol Bhawane<sup>1</sup>, Sourya Acharya<sup>1</sup>, Samarth Shukla<sup>2</sup>, Akhilesh Annadatha<sup>1</sup>, Vidyashree Hulkoti<sup>1</sup>

<sup>1</sup>Department of Medicine, <sup>2</sup>Pathology Jawaharlal Nehru Medical College, DMIMS (Deemed to be University), India

### ABSTRACT

**Rationale:** Coexistence of anti-glomerular basement membrane (anti-GBM) disease with anti-neutrophil cytoplasmic antibody (ANCA) in a case of glomerulonephritis is often identified as a “double-positive” disease. Interestingly, the majority of “double positive” ANCA is myeloperoxidase (MPO)-ANCA and some of the MPO-ANCA positive cases showed intrarenal arteritis, suggesting an ANCA-associated kidney lesion. Proteinase 3-ANCA positive diseases are also rarely reported. Patients positive for all three antibodies, *i.e.*, triple-positive patients, are extremely rare.

**Patient’s Concern:** A 53 year-old female presented with anasarca and oliguria of 2 months’ duration.

**Diagnosis:** Pauci-immune type renal limited crescentic glomerulonephritis positive for MPO-ANCA, proteinase 3-ANCA, and anti-GBM antibody (triple-positive).

**Interventions:** Intravenous high dose cyclophosphamide, oral azathioprine, intravenous methylprednisolone, and plasma exchange as per British Health Professionals in Rheumatology Guidelines.

**Outcomes:** After one-month follow-up, anasarca and proteinuria were lessened, serum creatinine was normalized, titers of MPO-ANCA levels were decreased, and anti-GBM antibody levels were normalized.

**Lessons:** Triple-positive renal limited vasculitis is rare and response to combined immunosuppressive therapy and plasma exchange can contribute to successful remission.

**KEYWORDS:** Anti-glomerular basement membrane; Anti-neutrophil cytoplasmic antibody; Rapidly progressive glomerulonephritis; Myeloperoxidase; Proteinase 3

### 1. Introduction

Anti-glomerular basement membrane (GBM) disorder and anti-neutrophil cytoplasm antibody (ANCA)-associated vasculitides are

uncommon diseases with an approximate prevalence between 1 to 20 per million each year[1]. Discrimination of both ANCA and anti-GBM antibodies in human cases, however, is well-recognized. It is evident that these two antibody-positive populations are antigenically distinct[2], and this trend is not attributable to cross-reactivity, although the associated mechanisms are specific. Some researches recorded the results of such double-positive patients, though with contradictory findings; some found stronger results than those with the single-positive anti-GBM disease[3], while others indicated that double-positive patients have similar or worse outcomes[4].

Anti-GBM glomerulonephritis (GN) is typically a fulminant, increasingly progressive disease triggered by autoantibodies to the non-collagenous  $\alpha 3$  domain of type IV collagen of the GBM. The prevalence of anti-GBM GN is low, with an average annual occurrence of 0.5-1 per million people[5]. This disease can appear as individual GN, or associated with pulmonary hemorrhage known as a pulmonary-renal syndrome. The survival in such cases remains low due to the delay in diagnosis and treatment[5]. The cornerstone of the management of anti-GBM GN is to eliminate pathogenic autoantibodies from circulation thereby avoiding further development of autoantibodies and attenuating the ongoing inflammation and injury[5]. Patient and kidney survival in untreated anti-GBM GN is poor. A study showed that immunosuppression plus plasmapheresis can improve patients’ and kidney’ survival rate[5].

✉To whom correspondence may be addressed. E-mail: dramoljnm@gmail.com

This is an open access journal, and articles are distributed under the terms of the Creative Commons Attribution-NonCommercial-ShareAlike 4.0 License, which allows others to remix, tweak, and build upon the work non-commercially, as long as appropriate credit is given and the new creations are licensed under the identical terms.

**For reprints contact:** reprints@medknow.com

©2021 Journal of Acute Disease Produced by Wolters Kluwer- Medknow. All rights reserved.

**How to cite this article:** Andhale A, Bhawane A, Acharya S, Shukla S, Annadatha A, Hulkoti V. “Triple-positive” renal limited vasculitis presenting with rapidly progressive glomerulonephritis: A case report. J Acute Dis 2021; 10(2): 83-86.

Article history: Received 5 June 2020; Revision 11 March 2021; Accepted 15 March 2020; Available online 29 March 2021

## 2. Case report

This study was approved by the Ethics Committee of Datta Meghe Institute of Medical Science Wardha (Sawangi Meghe). Informed consent was obtained from the patient.

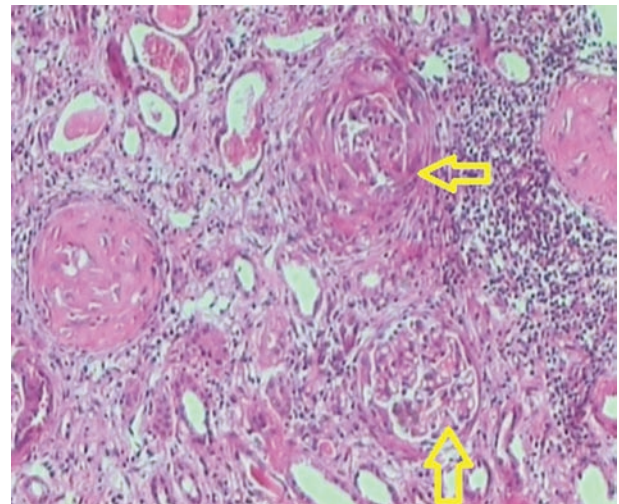
A 54-year-old female presented to us with complaints of swelling of feet and facial puffiness accompanied with oliguria 2 months ago (March 2020 to May 2020). The patient reported to us with no history of abdominal pain, dysuria, exertional breathlessness or orthopnea, hemoptysis, rash over the body, joint/muscular pain, melena, seizure, focal neurological deficit. She was not diabetic or hypertensive and had no significant illness in the past.

Examinations on admission showed pulse: 114/min, regular; Blood pressure: 168/98 mm of Hg, pallor-present; Jugular venous pressure was normal; Bilateral pitting edema feet was present; Facial puffiness was present; Cardiovascular system, respiratory system, and per-abdomen examination were normal.

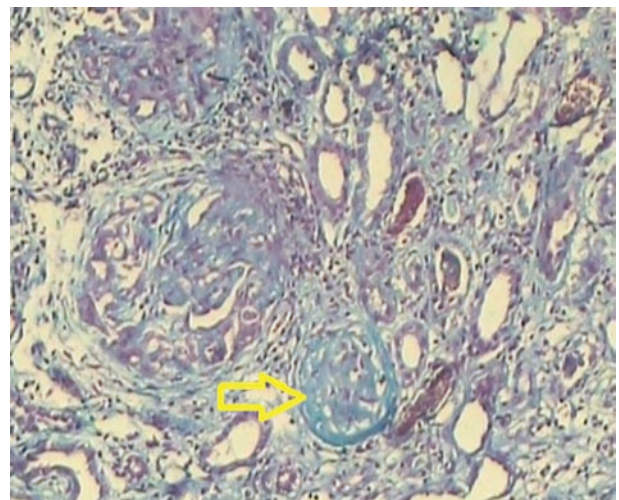
Investigations on complete blood count were conducted. Hemoglobin: 7.1 g% (normal range: 12 to 15.5 g%), normocytic normochromic; Mean corpuscular volume 62 fl (normal range: 80 to 90 fl); White blood cell: 7400/mm<sup>3</sup> (normal range: 4500 to 11000/mm<sup>3</sup>), with normal differential counts. Kidney function test showed urea: 172 mg/dL (normal range: 7 to 20 mg/dL); Creatinine: 7.4 mg/dL (normal range: 0.9 to 1.3 mg/dL); Potassium: 5.9 mEq/L (normal range: 3.5-5.5 mEq/L); Sodium: 134 mEq/L (normal range: 135 to 145 mEq/L); Erythrocyte sedimentation rate: 60 mm in 1st hour (normal range: 0 to 30 mm in 1st hour). Urine routine examinations revealed red blood cells/hpf of 10 to 12 (normal range: less than 3/high power field); 24-hour urinary protein: 2.8 g; Urine for Bence-Jones protein was negative; Serum electrophoresis was normal. Ultrasonography abdomen showed normal sized kidneys with retained corticomedullary differentiation. Arterial blood gas was suggestive of metabolic acidosis. In view, metabolic acidosis and hyperkalemia hemodialysis was done.

A possibility of rapidly progressive glomerulonephritis was proposed, and renal biopsy was planned. Other investigations were shown in Table 1.

Renal biopsy was conducted, and the results were shown in Figure 1 and Figure 2.



**Figure 1.** Section from given renal biopsy stained with H&E stain 40× shows 5 glomeruli (left arrow). Two glomeruli (up arrow) showing global sclerosis with one of the glomerulus showing crescent formation along with two normal-appearing glomeruli (up arrow).



**Figure 2.** Slide stained with Masson's trichrome stain (10×) shows sclerotic changes (right arrow) in the glomeruli suggestive of glomerulosclerosis with crescent formation (right arrow).

**Table 1.** Special investigations of the case.

Test name	Value	Normal range
Anti GBM (ELISA)	>100 AU/mL (positive)	<12 AU/mL
PR3-ANCA (C-ANCA) (ELISA)	9.66 U/mL (positive)	<6 U/mL
MPO-Antinuclear antibody (P-ANCA) (ELISA)	38.5 U/mL (positive)	<12.0 U/mL
Antinuclear antibody	Negative	1:40-1:60
ds-DNA	32.4 IU/mL	30.0-75.0 IU/mL
Sr. Complement C3	79.3 mg/dL	66-185 mg/dL
Sr. Complement C4	24 mg/dL	15-52 mg/dL
Rheumatoid factor	9.2 IU/L	<14 IU/mL
Hepatitis B virus (HBsAg)	Negative	-
Hepatitis C virus (Ig G anti HCV)	Negative	-
Hepatitis A virus (Ig M anti HAV)	Negative	-
Human immunodeficiency virus (ELISA for HIV)	Negative	-

GBM: glomerular basement membrane; PR3-ANCA: proteinase 3-anti-neutrophil cytoplasmic antibody; MPO: myeloperoxidase.

Immunofluorescence showed the absence of IgG, IgA, IgM, C3, C3c, and C1q deposition, which finally suggested pauci-immune crescentic glomerulonephritis. High resolution computed tomography thorax was normal ruling out pulmonary involvement. With the above findings, a final diagnosis of renal limited crescentic GN was made.

Based on the diagnosis, the patient was treated with intravenous high dose cyclophosphamide 500 mg/d (375 mg/m<sup>2</sup>), single injection, repeated every 2 weeks (total 3 doses) then changed to oral azathioprine 50 mg, IV methylprednisolone 500 mg daily for five days then orally 50 mg/d which was tapered, and plasma exchange was given 5 times, as per British Health Professionals in Rheumatology Guidelines. After one month MPO-ANCA levels decreased from 38.5 U/mL to 5.1 U/mL, and anti-GBM antibody levels were also normalized. Twenty four-hour urinary protein was reduced to 600 mg. Oral prednisolone was continued at 20 mg/d and oral azathioprine 50 mg/d. She was asymptomatic in the second follow-up in August. Repeat investigations revealed MPO-ANCA of 4.8 U/L and 24-hour urinary protein of 210 mg/d. The immunosuppression therapy was continued.

### 3. Discussion

Although some rapidly-progressing cases of double-positive glomerulonephritis have been reported previously with either MPO-ANCA/anti-GBM or Proteinase 3 (PR3)-ANCA/anti-GBM, our case of three positive antibodies is rare. A previous study reported patients who were double-positive for ANCA and anti-GBM antibodies and found that 32 percent of anti-GBM antibody-positive patients were ANCA-positive, only 5 percent of ANCA-positive patients were also positive for anti-GBM antibodies[6].

A study showed that patients who are double-positive for ANCA and anti-GBM antibodies are almost 20 years older than those who are positive only for anti-GBM antibodies, suggesting that ANCA but not anti-GBM antibodies may be the root cause of the disease[7]. We assumed that the anti-GBM antibody was not the main cause of renal injury in this patient due to the lack of linear IgG deposition.

ANCA-associated vasculitides include granulomatosis polyangiitis (GPA), microscopic polyangiitis (MPA), renal-limited vasculitis (RLV), and eosinophilic granulomatosis and polyangiitis[8]. Around 82 to 94 percent of GPA or MPA patients have positive ANCA, depending on the disease severity[9]. GPA is mainly associated with PR3-ANCA and partially with MPO-ANCA. However, 20% of GPA or MPA patients have alternate ANCA, and at least 10% of patients have harmful ANCA[10]. Seventy-five to eighty percent of cases of RLV are MPO-ANCA-positive[9].

RLV is considered to be part of the GPA/MPA spectrum as histopathological findings are frequently inseparable from those observed in GPA and MPA. Some patients who have RLV will subsequently develop alien manifestations of GPA or MPA, sometimes during a relapse years after the onset of the disease.

RLV patients in renal biopsy tend to have more glomerulosclerosis than those with GPA, presumably because RLV patients have delayed admission due to the lack of external symptoms[9]. Although a close relationship has been suggested between the production of ANCA and the anti-GBM antibody, the underlying mechanism remains unclear. One of the postulated hypotheses is the unmasking of hidden antigens on GBM by ANCA-activated endogenous oxidants that induce anti-GBM antibody production[9]. The prognosis of double-positive patients remains controversial. The results of studies comparing the outcome of double-positive patients with those positive for anti-GBM antibody alone showed that the prognosis ranged from good to worse in patients who were serologically double-positive for these antibodies. The presence of additional antibodies in patients who are positive for one antibody should be assessed[9].

The likely antibody that caused renal failure in our patient was MPO-ANCA. The present case showed predictable recovery of renal function along with the decrease of proteinuria and MPO-ANCA titer, suggesting a good response to the standard regimen for induction of remission with MPA, glucocorticoid, and cyclophosphamide as per British society for Rheumatology and British Health Professionals in Rheumatology Guidelines along with plasma exchange[10].

This case highlights the natural course and management of a patient with crescentic glomerulonephritis and seropositivity for MPO-ANCA, PR3-ANCA, and anti-GBM antibody (triple-positive) who was successfully treated with methylprednisolone, plasma exchange indicating that RLV patients with triple antibody seropositivity may be treated with the combination therapy. The case emphasizes that early intensive combination immunosuppression and plasma exchange therapy and maintenance of immunosuppression are vital for treatment in triple-positive disease.

### Conflict of interest statement

The authors report no conflict of interest.

### Authors' contributions

A.A. (Amol Andhale) and S.A.: Concept and design of the study, acquisition of data, drafting the article; S.A., A.B. and S.S.: Acquisition of data revising the article critically for important intellectual content; V.H. and A.A. (Akhilesh Annadatha): Revising article critically for important intellectual content.

### References

- [1] Pusey CD. Anti-glomerular basement membrane disease. *Kidney Int* 2003; 64(4): 1535-1550.

- [2] Short AK, Esnault VL, Lockwood CM. Anti-neutrophil cytoplasm antibodies and anti-glomerular basement membrane antibodies: two coexisting distinct autoreactivities detectable in patients with rapidly progressive glomerulonephritis. *Am J Kidney Dis* 1995; **26**(3): 439-445.
- [3] Jayne DR, Marshall PD, Jones SJ, Lockwood CM. Autoantibodies to GBM and neutrophil cytoplasm in rapidly progressive glomerulonephritis. *Kidney Int* 1990; **37**(3): 965-970.
- [4] Rutgers A, Slot M, van Paassen P, et al. Coexistence of anti-glomerular basement membrane antibodies and myeloperoxidase-ANCAs in crescentic glomerulonephritis. *Am J Kidney Dis* 2005; **46**(2): 253-262.
- [5] Olson SW, Arbogast CB, Baker TP, Owshalimpur D, Oliver DK, Abbott KC, et al. Asymptomatic autoantibodies associate with future anti-glomerular basement membrane disease. *J Am Soc Nephrol* 2011; **22**(10): 1946-1952.
- [6] Bosch X, Mirapeix E, Font J, Borrellas X, Rodríguez R, López-Soto A, et al. Prognostic implication of anti-neutrophil cytoplasmic autoantibodies with myeloperoxidase specificity in anti-glomerular basement membrane disease. *Clin Nephrol* 1991; **36**(3): 107-113.
- [7] Jennette JC, Falk RJ, Bacon PA, Basu N, Cid MC, Ferrario F, et al. 2012 revised International Chapel Hill Consensus Conference Nomenclature of Vasculitides. *Arthritis Rheum* 2013; **65**(1): 1-11.
- [8] Jennette JC, Falk RJ, Andrassy K, Bacon PA, Churg J, Gross WL, et al. Nomenclature of systemic vasculitides. Proposal of an international consensus conference. *Arthritis Rheum* 1994; **37**(2): 187.
- [9] Guillevin L, Durand-Gasselín B, Cevallos R, Gayraud M, Lhote F, Callard P, et al. Microscopic polyangiitis: clinical and laboratory findings in eighty-five patients. *Arthritis Rheum* 1999; **42**(3): 421-430.
- [10] Lane SE, Watts RA, Shepstone L, Scott DG. Primary systemic vasculitis: clinical features and mortality. *QJM* 2005; **98**(2): 97-111.