

# Talo-calcaneal smile osteotomy as a treatment of rigid residual equinus deformity

Sameh S Alsafty<sup>1\*</sup>, Hassan Saqlain<sup>2</sup>, Kareem S Khalil<sup>2</sup> and Gamal A Hosny<sup>3</sup>

<sup>1</sup>Shibin Alkom Teaching Hospital, Shibin Alkom, Elmenofya, Egypt.

<sup>2</sup>Alqassimi Hospital, UAE.

<sup>3</sup>Department of Orthopaedic, Faculty of Medicine, Benha University, Egypt.

Accepted 31 March, 2021

---

## ABSTRACT

Foot deformities are usually complex. Equinus deformity can be a residual foot deformity element or isolated. A rigid type is the most difficult for treatment. The aim of work is the treatment of rigid equinus deformity by a minimally invasive technique using Ilizarov fixator to restore plantigrade foot and to prevent further recurrence. 17 feet in 14 patients with stiff ankles and rigid equinus after failed surgical correction of club feet, with mean age 6.6 years (4 to 10 years), all treated by smile talocalcaneal osteotomy and Ilizarov ring fixator with a mean follow up 20.9 months (5 to 30 months). 5 feet (29.9%) had excellent results, 8 (47.1%) had good results, 1(5.9%) had a fair result and 3 feet (17.6%) had poor results and underwent revision surgery. In conclusion, our technique Talo-calcaneal smile osteotomy based on distraction osteogenesis method appears to provide similar or better results compared to other literature results without discrimination of foot size, provide some range of motion and plantigrade foot.

**Keywords:** Clubfoot- equinus- rigid -deformity, Ilizarov- Smile osteotomy.

---

\*Corresponding author. E-mail: [alsaftysameh@yahoo.com](mailto:alsaftysameh@yahoo.com).

---

## INTRODUCTION

Ankle equinus, being congenital or acquired, is one of the commonly faced deformities in the field of pediatric orthopedics. Causes can include trauma, diabetes mellitus, neurological disease or viral infection or some other problems that affect the musculoskeletal system like burn contractures or even simple prolonged immobilization in an improper position. Though congenital equinus deformity is usually an isolated one we often treat it as a part of more complex deformities like congenital talipes equinovarus (DiGiovanni et al., 2001; Guyton and Saltzman, 2001).

Ankle equinus is classified pathologically into: soft tissue type, bony, or combined. Soft tissue type is easily treated, but if it is a part of a more complex deformity like clubfoot, treatment becomes a little bit complicated (Banks et al., 2001).

The consequences of equinus deformity are: altered gait pattern as walking with toe-toe sequence, these results in increased energy expenditure and marked

speed reduction in gait while walking especially in spastic cerebral palsy patients, then can affect knee and hip later (Vanwala et al., 2014)

Ring fixators can be easily used for correction of soft tissue equinus without the need for osteotomy but with a high recurrence rate. In the case of bony equinus, to correct the deformity osteotomy has to be carried out and a circular frame is applied to perform distraction osteogenesis (Spielberg et al., 2010). Gradual distraction of the soft tissues and bones enables reshaping of the foot. The advantages of this method are, being highly minimally invasive although the patient has to comply with having a big instrument fixed to his leg for several months. Second thing is that the patient will be able to bear weight on it, which is not amenable with internal fixation. One more advantage of this method is that it corrects soft tissue contractures at the same time during the gradual distraction (Ilizarov, 1992).

There are three main types of hind-foot osteotomies to

correct the deformity including the U, V, and Y osteotomies. The (U) shaped osteotomy is done from a point behind the lateral malleolus then below the posterior facet of the subtalar joint by about 1.5 cm then through the floor of sinus tarsi towards and through the talar neck dividing the foot into two parts and allowing for correction of rigid equinus cases (Kocaoğlu et al., 2002).

In the (v) shaped osteotomy, the 2 limbs are made by connecting one cut from the anterior talocalcaneal joint running posteroinferiorly and one from the posterior aspect of the calcaneum running anteroinferiorly to meet at an angle of about ~65 degrees. It is indicated for complex cases where the deformity is at 2 levels (hind and midfoot). When combined with an ex-fix, it becomes versatile and gives the ability to preserve foot length while doing tibial corrections at the same time (Gerhardt et al., 2001; Theis et al., 2000).

The (Y) osteotomy is just a (V) osteotomy with one more limb running down like a Mercedes sign with all three limbs 120 degrees apart. It has the same ability to correct complex equinus cases at the hind and forefoot levels. However, it has fewer complications than U osteotomy (Emara et al., 2008)

The choice of osteotomy depends mainly on surgical expertise as well as the complexity and nature of the deformity. The Ilizarov external fixation is usually preferred as it allows deformity correction in all the three planes, minimally invasive, allows the surgeon to control the rate and direction of the correction as it is available in

constrained or unconstrained hinge system (Mendicino et al., 2008; Shalaby and Hefny, 2007).

It worth mentioning that any change in the axis of lower extremity or misalignment of the ankle joint will lead to debilitating functional limitation, hence the Ilizarov technique in gradual correction is superior to other techniques in equinus deformity correction (Morasiewicz et al., 2017).

**MATERIALS AND METHODS**

The necessary ethical approvals and proper consents were taken from the patients or their next of kin.

From March 2013 to August 2018, 17 feet in 14 patients with failed surgical correction. All patients presented by rigid recurrent equinus deformity and were treated by our Talocalcaneal smile osteotomy with Ilizarov external fixator application.

3 Patients had bilateral deformities and 11 had a unilateral type; 8 patients were males (57.1%) and 6 were females (42.9%). The mean age at surgery was 6.6 years ranging from 4 to 10 years. 10 feet were right side and 7 were left side. The causes varied between cerebral palsy, poliomyelitis, CTEV (congenital talipes equinovarus), Arthrogryposis, and burn (Table 1).

Correction of the deformity was achieved through gradual, progressive distraction osteogenesis of talocalcaneal smile osteotomy, augmented by minimal invasive lengthening technique for Achilles tendon and plantar fascia release.

Standard Ilizarov device was used as 2 rings on the leg, half ring on the forefoot, half ring applied on the heel.

Frame application period ranged from 2.5 to 4 months and follow up after removal of Ilizarov ranged from 5 to 30 months.

**Table 1.** Patients' criteria and number of previous surgeries.

No.	Gender	SIDE	Age	Etiology	Number of surgeries before
1	M	Rt	4	C.P	2
2	M	Rt	5	Arthrogryposis	5
3	F	Rt	4.5	CTEV	2
4	F	Lt	5	C.P	3
5	M	Bil	7	C.P	2
6	F	Lt	6	CTEV	1
7	M	Rt	4	C.P	1
8	M	Bil	10	Arthrogryposis	4
9	F	Rt	8	Burn	3
10	M	Lt	9	Poliomyelitis	1
11	F	Rt	7	Poliomyelitis	1
12	F	Lt	7	C.P	2
13	M	Bil	9.5	C.P	4
14	M	Rt	6.5	C.P	3

C.P = cerebralpalsy, CTEV = congenital talipes equinovarus.

**Clinical and radiological examination**

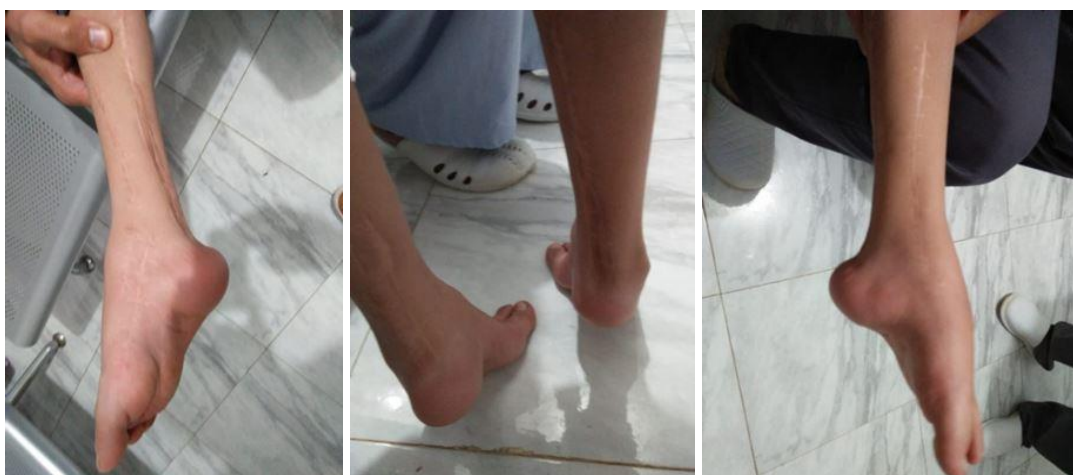Clinical examination of the ankle and foot Showed: restricted range of motion, tiptoeing gait in all patients, degree of equinus was

assessed and documented as shown in Table 2, skin showed scars of previous failed operations and soft tissue contractures, leg-length discrepancies, and other residual foot deformities (Figure 1).

The radiographic assessment included foot and ankle series. In

**Table 2.** Number of feet, pre and post op. correction achieved, duration of Ilizarov fixator application and complications.

No.	Pre-op equinus	Post op dorsiflexion	Duration of ilizarov application	Follow up	Final results	Complications
1	-20	+5	2.5 m	5	Excellent	
2	-35	-5	4 m	30	Poor	Residual equinus
3	-40	-5	2.5 m	24	Excellent	
4	-40	-5	3 m	20	Good	
5	Right-20 Left -30	+5 0	3.5 m	25	Good Good	
6	-29	0	2.5 m	27	Excellent	
7	-30	0	3 m	24	Good	
8	Right-35 Left -30	0 +5	4 m	30	Good Good	Pin tract infection
9	-35	-5	4 m	26	Fair	Skin gangrene posterior aspect of the ankle
10	-20	+10	2 m	8	Good	
11	-20	+10	2.5 m	10	Excellent	
12	-30	0	3 m	18	Good	
13	Right -25 Left -30	-10 -10	3.5	22	Poor Poor	Recurrence of deformity
14	-25	0	3 m	24	Excellent	

**Figure 1.** Pre-operative clinical photos.

the anteroposterior foot view, talocalcaneal, talus-first metatarsal, and calcaneal pitch angles together with the tibiotalar angle in lateral ankle view were useful in confirming the final clinical improvement though we missed documenting them or considering them in our parameters and depended on the clinical angles.

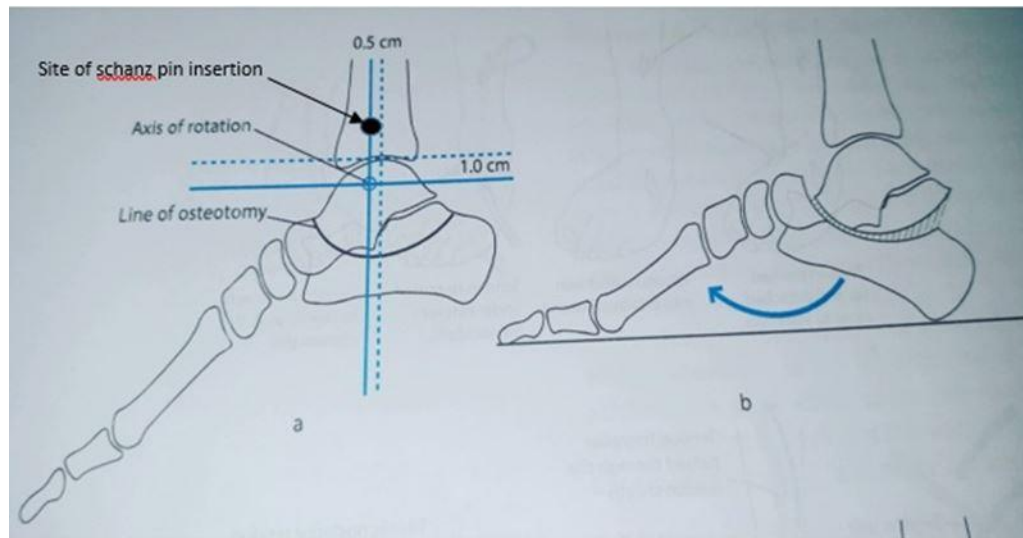
#### Surgical technique

Under G/A with the tourniquet applied and the patient is in the supine position, the limb is painted and draped from foot to thigh.

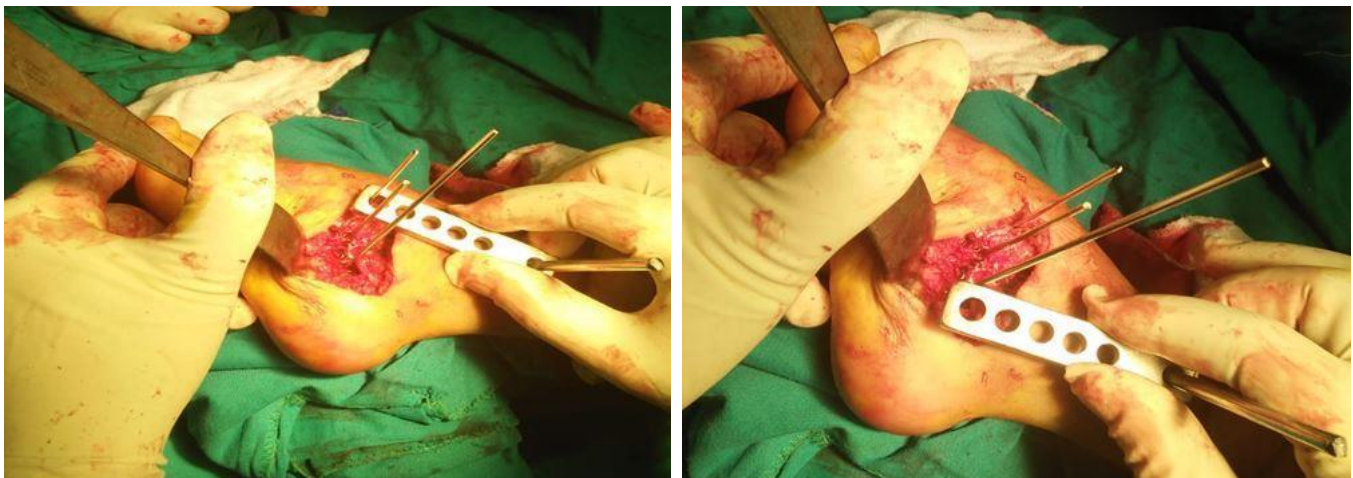
We start by percutaneous tenotomy of the Achilles tendon, then percutaneous plantar fascia release.

About 5 to 6 cm incision is done below the lateral malleolus, then exploration and retraction of the peroneal tendons is carried out and through their bed we make an incision and start subperiosteal dissection to prepare the area for the osteotomy. Under image intensifier, we detect the anatomic axis of the tibia in the sagittal plane, and through small incision we put a supramalleolar half pin. A plate is used to pivot on this pin and help us draw the osteotomy (Figures 2 and 3).

Multiple drill holes are done by moving the plate from side to side



**Figure 2.** Site of pin insertion and how osteotomy is done around it.



**Figure 3.** Intra-operative photos.

starting from the superior edge of the calcaneal body and ending at the superior edge of the talar body to draw the line of osteotomy, then curved osteotome 15 mm is used to connect the dots (Figure 4). It is important to confirm that the osteotomy is complete under C- arm and by being able to move the fragment on either side of the osteotomy. Skin is closed and dressing is done then the tourniquet is deflated.

The frame is constructed as follows: 2 proximal tibial rings and 2-foot half rings. Each proximal ring was fixed by 3 wires, fibular trans fixation is not required for every case. A hindfoot half-ring fixed to the calcaneus by 2 crossing olive wires and one sagittal 5 mm half pin. One last half-ring over the forefoot perpendicular to the axis of metatarsals, fixed by 3 wires, one passed through 1st, 2<sup>nd</sup> and 3rd metatarsal, other one passed through 5th – 4th metatarsals, the last one wire passed through tarsal bones to increase stability. Both half rings are connected by medial and lateral connecting rods acting as motors with universal hinges. Posteriorly, 2 rods connect the tibial

rings with the calcaneal half-ring to push the hindfoot. Anteriorly, 2 rods with bi-planer hinges connect tibial rings with forefoot ring to pull forefoot (Figure 5).

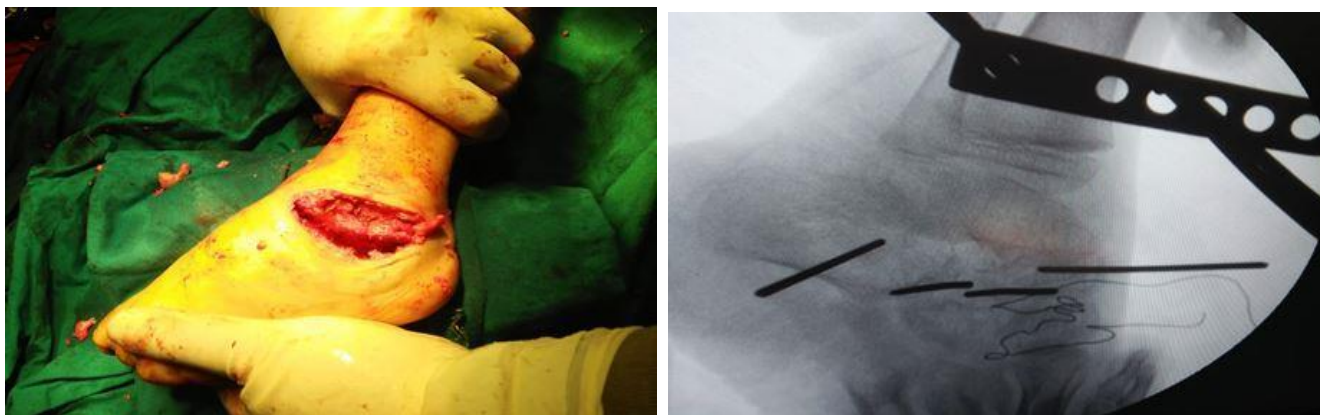
Deformity correction starts on the 5th postoperative day at a rate of 1 mm /day (1/2 mm every 12 hours) on the posterior rods connecting the tibial and calcaneal rings and lateral and medial foot rods. At the same time, anterior rods are shortened at the same rate.

After 7 days, we start to pull and push anterior and posterior rods respectively to correct the equinus. Then rest and distraction to facilitate rotation of foot around osteotomy then pull and push till deformity is fully corrected.

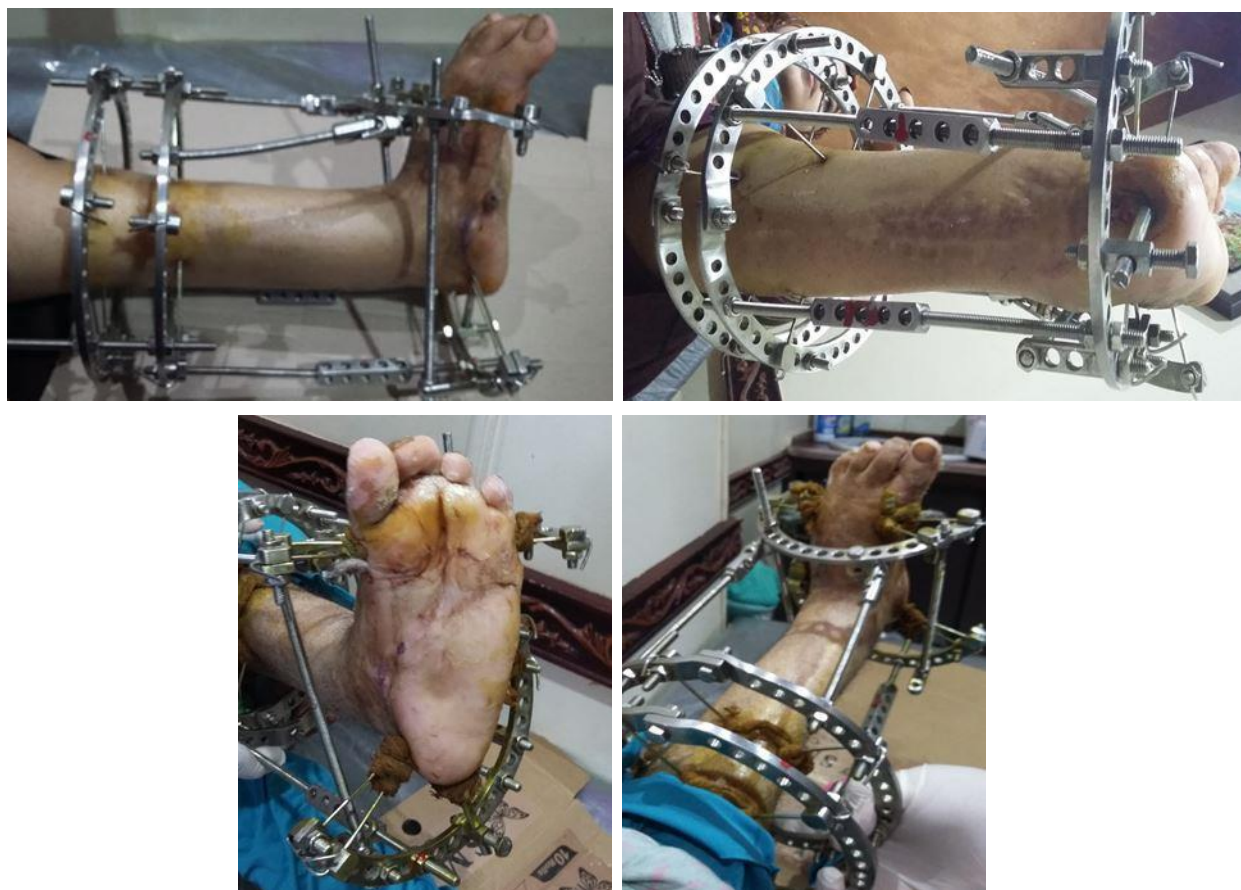Concomitant Varus or valgus can be corrected by unequal distraction on both sides of the foot. The period of frame application depends on the achievement of correction and complete consolidation of the osteotomy site.

Finally, below knee and walking casts were applied for 3 weeks.





**Figure 4.** Intra-operative shape of osteotomy, x.ray.



**Figure 5** Post-operative clinical photos with the frame.

**RESULTS**

The deformity correction and function were evaluated and the results were graded based on the Reinker and carpenter scale as follows:

- Excellent: pain-free, plantigrade foot with full function.
- Good: Plantigrade, mildly painful foot with ability to walk long distances.
- Fair: Mild residual deformity that needed bracing with or without some functional disability however the patient is

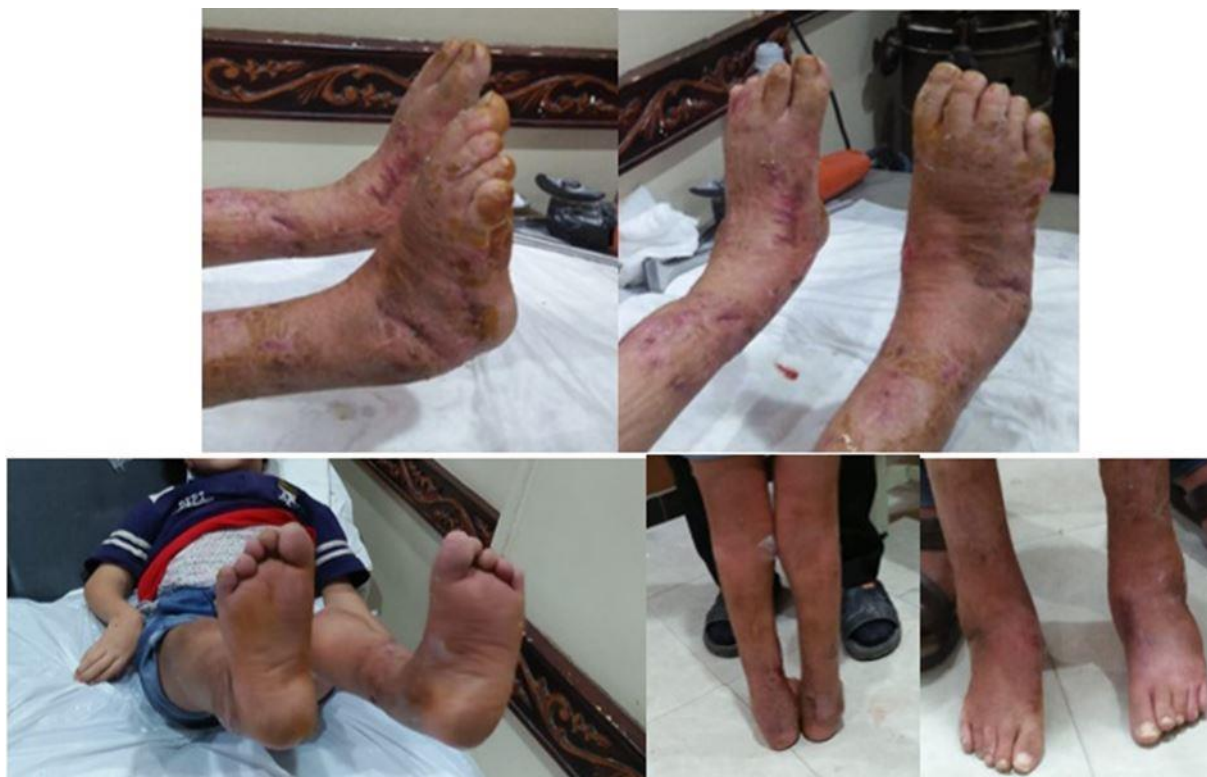self-dependent and active.

Poor: Significant residual deformity, pain, and functional limitation.

Out of 17 feet, 5 (29.9%) were rated as excellent, 8

(47.1%) good, 1 (5.9%) fair and 3 (17.6%) poor (Table 2, Figure 6).

Thus gradual correction with the Ilizarov technique gave satisfactory results in failed post-surgical rigid, recurrent equinus deformity.



**Figure 6.** Clinical photo of one of the bilateral cases immediately after cast removal and on follow up.

### Complications

One case (Arthrogyrosis) had residual equinus and underwent revision surgery after 6 months (right foot).

One case (Arthrogyrosis) had pin tract infection grade 2 and was treated by antibiotics and dressing.

One case (Cerebral palsy) had a complete recurrence of the equinus and was advised for pan-talar arthrodesis, but parents refused.

One case (post-burn) had a small gangrenous skin area on the posterior aspect of the ankle and underwent skin grafting by plastic surgeons.

### DISCUSSION

Complex foot and ankle deformities are truly difficult cases of their kind even in the best hands, and when it comes to a rigid equinus in a foot with previous multiple

operative interventions it becomes even more difficult and not without complications. The complications associated with the use of an external fixator and any type of osteotomy may include at least but not last, tarsal tunnel syndrome and other neurovascular problems, infection, muscle contractures, etc. Many techniques are available to correct these complications. The aim of orthopedic surgeons when dealing with such cases is to give the patient a plantigrade, stable, better looking, painless foot that fits in normal shoes. Among the rear foot corrective procedures are the U, V, and Y osteotomies (Shalaby and Hefny, 2007; Singh et al., 2011).

Shalaby and Hefny (2007) found that V osteotomy is indicated in more complex cases and gives more versatility during manipulation of fore and hindfoot deformities than U osteotomy.

Singh et al. (2011) found that Y is as good as V osteotomy with fewer complications and it is more

superior to the U osteotomy in that it does not cause any skeletal lengthening, hence it offers three advantages; faster healing because of less bone regeneration, cutaneous change is easily contained and no calcaneocuboid diastasis is expected.

Our smile osteotomy is much more like the U-shaped osteotomy (it was very difficult to find much about U osteotomy in literature). It was first described by Ilizarov himself in 1992; he included only one case of U-osteotomy in a study. He applied a one or two-ring tibial construct, which was then connected with hinges to a supporting foot frame. He also inserted one wire through the posterior aspect of the talus and secured it to the tibial portion with posts.

In 1993, out of his 23 patients (25 feet), Paley did only 2 U osteotomies. One of them had a clubfoot and a flat-top talus with equinus, varus and supination deformities. This patient experienced premature consolidation and required a repeat osteotomy. A plantigrade foot was obtained after eight months. The second patient had juvenile rheumatoid arthritis and posttraumatic injuries with an equinus deformity. A U-osteotomy was used to correct the deformity acutely. A plantigrade foot was obtained after 8.3 months, and no complications were observed. Paley stated that hinge placement during the U-osteotomy is crucial to avoid translational deformities (Paley, 1993)

In 2005, Paley presented 2 more cases of U-osteotomy. One patient had a congenital short femur with an equinus foot and a flat-top talus that was corrected acutely with the U-osteotomy by displacement of the neck of the talus and Achilles tendon lengthening. The other patient had fibular hemimelia with a flat-top talus and a limb-length discrepancy; the U-osteotomy was used to correct both angular and length deformities. The author did not state whether complications occurred (Paley, 2005).

Gourdine-Shaw et al. (2012) treated 15 patients with U osteotomy and gradual distraction using Ilizarov external fixator in 4 and tailor spatial frame in 11 cases. 7 deformities were congenital in origin, 3 traumatic, and 5 were developmental. The mean patient age at the time of surgery was 20 years with a wide range from four to sixty-three years. The mean duration of external fixation was 5 months with a range from three to eleven months. The mean duration of follow-up was 5 years with a range from three to nineteen years. Bony healing and a plantigrade foot were obtained in all 15 patients. Seven complications related to the U-osteotomy occurred in four patients, including deep pin-track infection in two, premature osseous consolidation in two, tarsal tunnel syndrome in two, and peroneal nerve entrapment in one. 14 patients became self-dependant walkers using no supports; one used only one crutch to walk. They reported a mean increase in height of 20 mm (Gourdine-Shaw et al., 2012).

So revising all the previously done U osteotomies we can say that all of them did not put a specific age category and it was tried mostly with primary equinus deformity with little or no previous surgeries with few exceptions in Gouridine-Shaw et al. (2012).

In our study, we operated on all complex and residual rigid cases with previous surgical interventions and the mean age of our cases was 6.6 years (4 to 10 years). We were able to correct forefoot relation to the hindfoot in addition to the hindfoot correction and this may be attributed to the soft tissue malleability that distinguishes children from adults and their response to gradual correction, and that's an advantage in our technique over the U osteotomy which corrects only hindfoot deformity.

Legaspi et al. (2001) reviewed 24 feet in 15 patients (mean age 5.5 years) who underwent talectomy for recurrent equinovarus deformity due to congenital idiopathic, syndromic and neuromuscular causes. He followed them up for 20 years. He got good results in 8 feet (33%) and no further surgery was required for them. Fair results were achieved in 10 feet (42%). In these cases, he was obliged to reoperate on their feet for recurrence of a hindfoot deformity and at last, he was able to let them walk without pain. The remaining 6 feet (25%) were poor, with painful ambulation (Legaspi et al., 2001).

So despite the similarity in indications between our study and this one, our results are much better yet with shorter follow up however still at least not last having the advantage of keeping ankle range of motion.

At last, we cannot leave without mentioning the Lambirradi triple arthrodesis procedure which was the commonest procedure for severe rigid equinus. In their long-term follow-up study, they concluded that the procedure is indicated mainly in polio patients with fair to good subjective and objective outcomes. However, in their study, most of the cases were poliomyelitis sequelae and not mentioned whether they had previous surgical intervention. Added to that 2ry arthritis of nearby joints was documented in most of the cases (Noah et al., 2018).

There is some similarity between our procedure and Lambrinudi's in term of rotating the lower part of the hindfoot under the talus but the major differences are the age group, the indications, and the gradual correction of the multiplanar deformity including the forefoot relation to the hindfoot plus the advantage of neither fusing the talonavicular nor the calcaneocuboid joints.

## CONCLUSION

Rigid equinus deformities especially relapsed ones and those after multiple corrections are a major disabling problem to the patients and challenging cases to solve for the surgeons. Lots of surgical osteotomies and fusions

are used to treat these cases. We say that our technique (the smile osteotomy, including bone and soft tissue procedures) when done to the proper age and for whatever reason even after failed previous surgical interventions can give equal or superior outcome to most of the present solutions even with multiplanar deformities including not only the hindfoot but the forefoot as well.

However, a prospective long-term follow-up study is still needed to confirm so.

## REFERENCES

- Banks AS, Downey MS, Martin DE, Miller SE, 2001.** Comprehensive Textbook of Foot and Ankle Surgery. Philadelphia, Lippincott Williams & Wilkins.
- Digiovanni CW, Holt S, Czerniecki JM, Ledoux WR, Sangeorzan BJ, 2001.** Can the presence of equinus contracture be established by physical exam alone? *J Rehabil Res Dev*, 38(3): 335–340.
- Emara KM, Allam MF, Elsayed MNMA, Ghafar KAEL, 2008.** Recurrence after correction of acquired ankle equinus deformity in children using Ilizarov technique. *Strategies Trauma Limb Reconstr*, 3: 105-108.
- Gerhardt S, Vinay S, Bernhard ZE, Uitz C, Wolfgang L, 2001.** Complex foot deformities associated with soft-tissue scarring in children. *J Foot Ankle Surg*, 40: 42-49.
- Gourdine-Shaw MC, Lamm BM, Paley D, Herzenberg JE, 2012.** Distraction Osteogenesis for Complex Foot Deformities: U-Osteotomy with External Fixation. *J Bone Joint Surg Am*, 94:1420-7.
- Guyton G, Saltzman C, 2001.** The diabetic foot. *JBJS*, 83A: 1083-1096.
- Ilizarov GA, 1992.** Operative correction of foot deformities. Transosseous osteosynthesis. Berlin: Springer-Verlag: 583-634.
- Kocaoğlu M, Eralp L, Atalar AC, Bilen FE, 2002.** Correction of complex foot deformities using the Ilizarov external fixator. *J Foot Ankle Surg*, 41: 30-39.
- Legaspi J, Li YH, Chow W, Leong JCY, 2001.** Talcotomy in patients with recurrent deformity in club foot: A long-term follow-up study. *J Bone Joint Surg*, 83-B: 384-387.
- Mendicino RW, Murphy LJ, Maskill MP, Catanzariti AR, Harry P, 2008.** Application of a constrained external fixator frame for treatment of a fixed equinus contracture. *J Foot Ankle Surg*, 47: 468-475.
- Morasiewicz P, Dejneke M, Urbanski W, Dragan SL, Kulej M, Dragan SF, 2017.** Radiological evaluation of ankle arthrodesis with Ilizarov fixation compared to internal fixation. *Injury*, 48: 1678–1683.
- Noah LW, Kuong EE, To KM, Leong JCY, Chow W, 2018.** Long-term outcome after Lambrinudi arthrodesis: How they're doing after three decades. *J Orthopaedic Surg*, 27(1):1-7.
- Paley D, 1993.** The correction of complex foot deformities using Ilizarov's distraction osteotomies. *Clin Orthop Relat Res*, 293: 97-111.
- Paley D, 2005.** Principles of deformity correction. (1st ed) 3rd printing. Berlin: Springer-Verlag.
- Shalaby H, Hefny H, 2007.** Correction of complex foot deformities using the V-osteotomy and the Ilizarov technique. *Strat Traum Limb Recon* 1: 21-30.
- Singh S, Kim A, Dailey T, Truong L, Mejia M, 2011.** Talar and Calcaneal Y-Osteotomy with Distraction Osteogenesis for the Correction of Rigid Equinus. *Foot Ankle Online J*, 4(4): 3.
- Spielberg B, Parratt T, Dheerendra SK, Khan WS, Jennings R, Marsh DR, 2010.** Ilizarov principles of deformity correction. *Ann R Coll Surg Engl*, 92: 101–105.
- Theis JC, Simpson H, Kenwright J, 2000.** Correction of complex lower limb deformities by the Ilizarov technique: An audit of complications. *J Orthopaedic Surg*, 8: 1448-1552.
- Vanwala JJ, Diwan S, Shah S, Vyas N, 2014.** Effect of ankle foot orthosis on energy expenditure index and gait speed in spastic cerebral palsy children: An observational study. *Int J Contemporary Pediatric*, 1(1): 17.

---

**Citation:** Alsafty SS, Saqlain H, Khalil KS, Hosny GA, 2021. Talo-calcaneal smile osteotomy as a treatment of rigid residual equinus deformity. *Int Res J Med Med Sci*, 9(2): 52-59.

---