

Utility of a Bedside Pocket-Sized Ultrasound Device to Promptly Manage Abdominal Pain in the Emergency Department

Bongiovanni Cristina¹, Gori Chiara¹, De Berardinis Benedetta¹, Marino Rossella¹, Laghi Andrea², Di Somma Salvatore^{1,3*}

¹Department of Medical-Surgery Sciences and Translational Medicine, “Sapienza” University Sant’Andrea Hospital, Via di Grottarossa, Rome, Italy

²Department of Radiological, Oncological and Pathological Sciences, “Sapienza” University, Viale del Policlinico, Rome, Italy

³Great Network Italy

Abstract

Introduction: Abdominal pain is a frequent reason for Emergency Department (ED) admission; it amounts for around 5–10% of all ED visits. Early assessment should focus on immediately distinguishing cases of acute abdomen that require urgent surgical intervention. The clinical localization of pain is crucial, suggesting an initial evaluation of the origin of the abdominal pain; however, imaging is often required for final diagnosis. Ultrasound (US) represents a rapid imaging modality that is readily available in the ED and does not involve radiation or contrast agent administration. A new generation of portable, battery-powered, low-cost, hand-carried ultrasound devices have become available recently; these devices can provide immediate diagnostic information in patients presenting with abdominal pain in ED.

The aim of the study was to demonstrate the diagnostic usefulness of a bedside pocket-sized ultrasound (BPU) device (Vscan from General Electrics) in non-traumatic patients complaining of acute abdominal pain in a tertiary care university hospital in Italy.

Methods: Patients with acute non-traumatic abdominal pain presenting in ED were prospectively enrolled and underwent physical examination, traditional imaging and BPU.

Results: A total number of 230 patients with acute non-traumatic abdominal pain were enrolled. Overall agreement between routine standard imaging and BPU turned out to be equal for computed tomography (K=0.3) and traditional ultrasound (K=0.29). Receiver operating characteristics curve (ROC) analysis for diagnostic power of the BPU in comparison with traditional US showed an area under the curve of 0.65, sensitivity and specificity of 87.2% and 42.31% respectively.

Conclusions: Emergency use of BPU in patients with non-traumatic abdominal pain demonstrated good diagnostic performance when compared to traditional imaging, with the potential advantage of reducing costs and delay in patient final disposition.

Keywords: abdominal pain, computed tomography, diagnosis, emergency department, ultrasound

Correspondence to:

Salvatore Di Somma
Department of Medical-Surgery Sciences and
Translational Medicine “Sapienza” University
Sant’Andrea Hospital, Via di Grottarossa, 1035/39 -
00189 Rome, Italy and Great Network Italy
Email: salvatore.disomma@uniroma1.it

INTRODUCTION

Abdominal pain is a frequent complaint in the emergency department (ED), and it amounts for 5–10% of all ED visits.¹

It encompasses a wide differential diagnosis that includes medical, surgical and non-surgical diseases that can involve all organs within the torso, abdomen, back and pelvis. Almost 10% of patients

complaining abdominal pain in the ED have a life-threatening cause and/or require surgery.²

Immediate assessment should focus on distinguishing those cases of true acute abdomen that require urgent surgical intervention from those that do not, which can initially be managed conservatively.³⁻⁵

Patient's outcome is directly related to early accurate diagnosis for providing immediate treatment; however, the final etiology could remain unknown in about 25% of patients discharged from ED and for 35% of patients admitted to hospital.³⁻⁶

Patient history, physical examination, and laboratory testing may not identify an underlying cause of pain but could narrow the differential diagnosis.^{6,7}

The location of pain should drive the evaluation of the patient with abdominal pain; however, imaging is often required for definitive diagnosis and treatment.^{1,3}

Computed tomography (CT) scan provides the highest sensitivity and specificity of all imaging modalities for patients with abdominal pain.^{7,8} In particular, in case of discriminating urgent from non-urgent conditions, the sensitivity for CT is 89% and the specificity is 77%.⁷

However, CT has major downsides such as the risk of contrast-induced nephropathy and exposure to ionizing radiation (a great concern in children and pregnant patients).⁹

Moreover, CT is expensive and may not be available at certain times and locations, which leads to delay in diagnosis and may compromise management and outcome.^{7,8}

On the other hand, ultrasound (US) is a rapid and safe modality, which is widely available, and does not involve radiation exposure and contrast media administration.^{7,8}

When compared with computed tomography, the sensitivity and specificity of ultrasound are lower. However, US has clearly demonstrated it is effective in identifying an accurate diagnosis in 53–83% of patients when coupled with good clinical assessment.^{7,10}

Additionally, performing US study and/or CT scan in the radiology department could be time-consuming and/or not always possible, especially in patients with hemodynamic instability and cannot leave the ED.¹¹⁻¹³

In the last few years, a new generation of portable, battery-powered, inexpensive, hand-carried ultrasound devices has become available; these devices can provide immediate diagnostic information not assessable by physical examination alone and may be useful in diagnosis of some fatal pathologies especially in overcrowded shifts.^{11,13}

The aim of the present study was to demonstrate the diagnostic usefulness of Vscan (Vscan™, c, USA) in non-traumatic patients complaining from acute abdominal pain in our ED by comparing results of Vscan exams have been compared with standard radiological methods such as US, CT and plain films.

MATERIAL AND METHODS

Study design

We conducted this prospective observational study in a 400-bed tertiary care university hospital located in a large metropolitan city in Italy with fifty thousand ED visits per year. The study was conformed to the Helsinki declaration and approved by the local ethical committee.

Written informed consent for the study was obtained from each patient.

Study population

Patients with acute non-traumatic abdominal pain, age >18 years old and able to give a written informed consent were considered eligible for the present study (Figure 1).

We excluded patients unable to give written consent, with hemodynamic instability or any other indication for immediate care or surgery, or if they had a previously diagnosed abdominal pathology.

Patients were triaged according to the presenting symptoms.

The medical history, the physical examination and the vital parameters were recorded in the

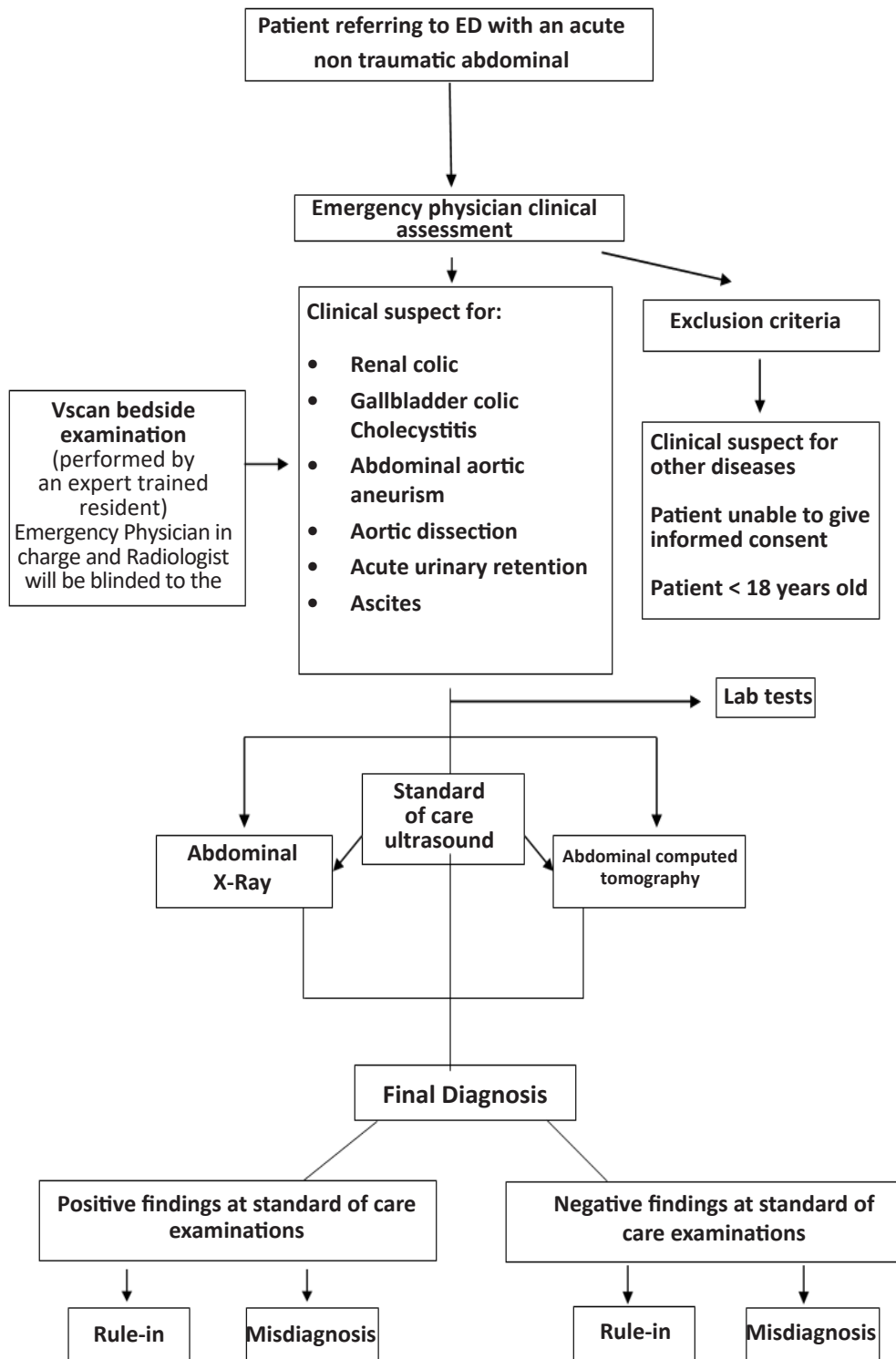


Figure 1 Study design.

computerized system. Laboratory tests and diagnostic imaging (X-rays, computed tomography, traditional ultrasound) were performed in a normal goal-directed manner.

A Vscan was performed at the bedside, in the emergency department by ED residents who had completed basic training in ultrasound. This training included two weeks of didactic and hands-on experience under the supervision of experienced faculty certified in ED ultrasonography. The trainees had to successfully perform and complete no less than 50 cases that required them to view image torso, abdomen and pelvis and view kidneys, bladder, liver, gallbladder, spleen and abdominal aorta. Immediately after the bedside US, patients underwent standard imaging provided by a specialist radiologist blinded to the Vscan results.

Different diagnosis was made on the basis of clinical findings as well as diagnostic and laboratory studies. The actual patient management and disposition were never based on the bedside US results alone.

Patients' diagnoses were encoded in four codes:

- Code 1: for kidney diseases (renal colic, acute urinary retention)
- Code 2: for gallbladder diseases (biliary colic, cholecystitis)
- Code 3: for abdominal aorta diseases and ascites (abdominal aortic aneurysm, aortic dissection, ascites)
- Code 4: for other abdominal diseases.

Data collection

Clinical data, demographic characteristics, comorbidity, length of stay, presenting symptoms and discharge diagnosis, time in the ED, time to perform each diagnostic test, laboratory tests, and time of admission to the hospital were recorded for each patient.

The duration for any "Standard imaging study" was considered as the period, in minutes, between the time of the computerized entry for the study request by the emergency physician (EP) in the centralized electronic health care system and the radiologist's official written reading for that study.

Vscan acquisition time was also measured. It was considered as the period, in minutes, between the time the probe was placed till the moment the exam was completed.

Pocket-sized ultrasound device

Vscan (Vscan™, GE Healthcare, USA) is a new generation pocket-sized ultrasound instrument, miniaturized (unit size: 135x73x28 mm; transducer size: 120 x 33 x 26 mm; weight: 390 g; display resolution: 240 x 320 pixels), battery-operated (total scan time: one hour) with a broad bandwidth (1.7 to 3.8 MHz). Its dimensions fit into a pocket. The device has a unique sectorial probe. The device provides black and white mode to display the anatomy in real-time, uses a color-coded overlay for real-time blood flow imaging and is capable of switching from cardiologic to abdominal settings. Vscan can store digital still-frames or image loops in a memory card downloaded on computerized system, allowing distance measurements using integrated electronic calipers.

Statistical analysis

Data points are expressed as mean \pm SD. Chi square exact test was used for the comparison of non-continuous variables expressed as proportions. $P < 0.05$ indicates statistical significance. All p values are 2-sided.

The diagnostic performance of bedside abdominal US and of abdominal CT and standard US was assessed by calculating sensitivity, specificity, positive predictive value, negative predictive value and likelihood ratios.

The k statistic was calculated to assess inter-observer agreement of abdominal bedside US and abdominal CT and abdominal standard US.

For the statistical analyses, SPSS software (version 17.0, SPSS Inc., Chicago, IL, USA) was used.

RESULTS

We included 230 patients (M/F= 50/50%; 51.81 \pm 17.82 years) with acute non-traumatic abdominal pain in the study. Patients' characteristics are shown in Table 1.

Table 1 Patients' characteristics.

Gender (M/F)	115/115
Age (years)(mean ± SD)	51.81 ± 17.82
ED LOS (hours)(mean ± SD)	15.58 ± 18.21

M: male; F: female; SD: standard deviation; LOS: length of stay

In 76.9% of patients bedside abdominal US showed significant pathological findings, of those 55.6% had hydronephrosis and/or ureteronephrosis, 14.7% gallbladder-biliary tract diseases, 3.9% free fluid in abdomen, 3.04% abdominal aorta aneurism, 1.7% acute urinary retention (Table 3).

Table 2 Comparison between Vscan and traditional imaging.

Vscan visualization (poor/good)(%)	7.4/92.6
Traditional imaging visualization (poor/good)(%)	3%/97%
Traditional imaging acquisition time (minutes) (mean ± SD)	94.8 ± 73.8
Vscan acquisition time (minutes) (mean ± SD)	4 ± 1

SD: standard deviation

In our population, pathological findings were recorded in standard imaging as follows: 76.09% with traditional ultrasound, 28.26% computed tomography, and 5.91% X-ray.

The global agreement between routine standard imaging and bedside ultrasound was higher for computed tomography (K=0.55) than for traditional ultrasound (K=0.44) (Figure 2); no concordance was found between abdominal X-ray and Vscan.

Patients were triaged as red code (1.74%), yellow code (51.30%), green code (46.96%). Traditional imaging report acquisition time was 94.8 ± 73.8 minutes while Vscan execution time was 4 ± 1 minutes (Table 2). ED final diagnosis is shown in Figure 3 and final patient's disposition is shown in Figure 4.

Vscan ROC curve analysis showed high diagnostic value for diagnosis codes 4 (all other causes) and 1 (kidney disease) in comparison to conventional radiology (Table 4).

In particular, for diagnosis code 4 (all other causes), results showed a sensitivity (CI95%) of 89.47% (66.86-98.70) and a specificity (CI95%) of 80.00% (28.36-99.49) with an AUC=0.85 for abdominal CT in comparison with Vscan; abdominal US had sensitivity (CI95%) of 91.30% (71.96-98.93) and a specificity (CI95%) of 72.22% (46.52-90.31) with an AUC=0.82.

Table 3 Vscan findings

Hydroureteronephrosis	55.6%
Gallbladder-biliary Tract Disease	14.7%
Free Fluid In Abdomen	3.9%
Abdominal Aorta Aneurism	3.04%
Acute Urinary Retention	1.07%

In code 1 patients (kidney diagnosis), abdominal CT showed a sensitivity (CI95%) of 91.18% (76.32-98.14) and a specificity (CI95%) of 50.00% (1.26-98.74) with an AUC=0.71; abdominal US showed a sensitivity (CI95%) of 86.11% (78.13-92.01) and a specificity (CI95%) of 45.83% (25.55-67.18) with an AUC=0.66.

A subgroup analysis was performed dividing patients as follows: hepatic/gallbladder diseases (including diagnosis code 2 + 4), urinary disease (diagnosis code 1) and abdominal aorta disease (diagnosis code 3).

The higher concordance between bedside US and traditional imaging (K=0.64) was found in the first subgroup (diagnosis code 2 + 4).

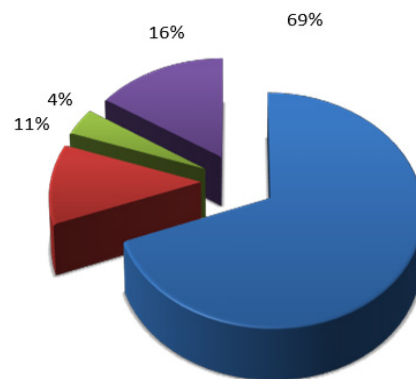


Figure 3 Final diagnosis. (Blue: kidney disease; red: gallbladder disease; green: abdominal aorta disease/free fluid in abdomen).

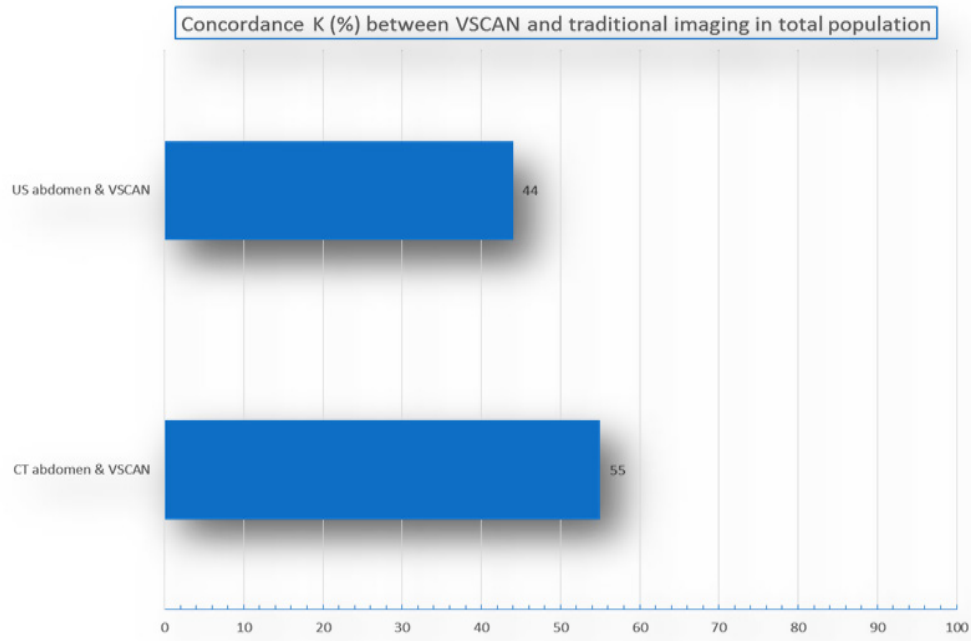


Figure 2 Concordance between Vscan and traditional imaging.

Table 4 Comparison between Vscan and traditional imaging.

Vscan	Sensitivity	Specificity	NPV	PPV	+LR	-LR	AUC
Diagnosis 1 (standard abdominal CT)	89.47% (66.86-98.70)	80.00% (28.36-99.49)	66.67% (22.28-95.67)	94.44% (72.71-99.86)	4.47 (0.77-26.00)	0.13 (0.03-0.52)	0.85
Diagnosis 1 (standard abdominal US)	91.30% (71.96-98.93)	72.22% (46.52-90.31)	86.67% (59.54-98.34)	80.77% (60.65-93.45)	3.29 (1.54-7.00)	0.12 (0.03-0.47)	0.82
Diagnosis 4 (standard CT)	91.18% (76.32-98.14)	50.00% (1.26-98.74)	25.00% (0.63-80.59)	96.87% (83.78-99.92)	1.82 (0.45-7.32)	0.18 (0.03-1.02)	0.71
Diagnosis 4 (standard US)	86.11% (78.13-92.01)	45.83% (25.55-67.18)	42.31% (23.35-63.08)	87.74% (79.94-93.31)	1.59 (1.09-2.31)	0.30 (0.16-0.57)	0.66

Diagnosis codes: code 1: kidney disease; code 2: gallbladder disease; code 3: abdominal aorta disease and ascites; code 4: others abdominal diseases. All parameters are present at 95% confidence interval; NPV: negative predictive value; PPV: positive predictive value; +LR: positive likelihood ratio; -LR: negative likelihood ratio; AUC: area under the curve.

In the urinary disease subgroup (code 1), concordance between traditional US and Vscan ($K=0.31$ was better than abdominal CT and Vscan ($K=0.28$).

No concordance was found in the vascular disease subgroup.

Furthermore, a high statistically significant correlation between bedside ultrasound and both computed tomography ($r=0.65$; $p=0.0006$) and traditional ultrasound ($r=0.65$; $p=0.0001$) were shown in the first subgroup.

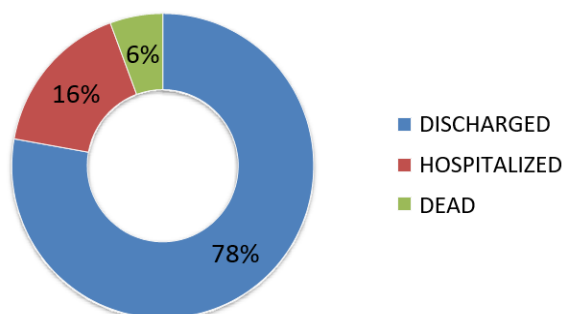


Figure 4 Final disposition from the emergency department.

DISCUSSION

Acute abdominal pain is a common presenting symptom in ED visits for conditions ranging from benign to life threatening.¹⁻⁶ Accurate early diagnosis and treatment are essential to optimize patient outcomes and prevent adverse events.⁴ In 70% of patients, an urgent diagnosis was correctly identified based on clinical assessment and US.¹⁴

The utility and accuracy of bedside US have been established with several studies and it has been incorporated into the training of EPs, however it has not yet included in the international guideline on acute abdominal pain.¹¹⁻¹⁶ The present study demonstrated that bedside abdominal US with Vscan had a good diagnostic performance compared to standard CT and US for patients with abdominal non-traumatic pain due to kidney diseases and other causes of abdominal pain except to vascular and gallbladder related diseases.¹⁴⁻¹⁹

This result was totally unexpected at the beginning of our study. The findings are different than those

reported in other prior studies that showed excellent diagnostic performance for emergency bedside US to detect the presence of the aortic and gallbladder related diseases in symptomatic patients;^{11-13,15} this could be related to the small sample, to the level of training and experience of the EP performing the Vscan and/or to the small number of positive findings among the examinations performed.

Moreover, we found a high concordance and correlation between Vscan and traditional imaging in a larger subgroup including hepatogastrointestinal-pancreatic diseases and gallbladder diseases (code 2 + 4). This result must be taken in consideration with standard imaging evaluation patients with abdominal non-traumatic pain.

Furthermore, we demonstrated how bedside US with Vscan could be very quickly used in an acute emergency scenario giving important information that could not be depicted with the clinical assessment alone. In our series bedside US can be performed in 4 ± 1 minutes contemporary with clinical care and complementary to the physical examination. This could lead to significant timesaving for the assessment of an adequate management of patients arriving in ED with acute non-traumatic abdominal pain. In fact, our results demonstrated how an overcrowded ED can lead to a delay in the acquisition time of standard imaging reports, that in our experience was 94.8 ± 73.8 minutes with a subsequent delay in patient disposition (in our study we recorded an ED length of stay of 15.58 ± 18.21 hours).

In our opinion, bedside US with Vscan should be used as part of the initial evaluation of all patients presenting to ED with acute non-traumatic abdominal pain, and that its complementation with clinical assessment will provide improved diagnostic value.

The use of US with Vscan as a complement to routine clinical assessment may avoid misdiagnoses, improve patient satisfaction, and may also reduce costs associated with return visits, additional unnecessary exams or potential adverse events caused by a delayed diagnosis.

Last but not least, bedside ultrasonography may

be particularly valuable in rural and underserved regions where healthcare providers have no access or limited access to CT scans, radiologists or formal ultrasonography. This is of special relevance to developing nations where such access is invariably absent or compromised.

LIMITATIONS

This study has some limitations. First, the analysed sample is small. Second, the majority of patients had kidney disease (69% of our sample) with a consequent underrepresentation of other relevant abdominal diseases such as gallbladder and abdominal aorta diseases that could represent an important spectrum bias in this study.

Finally, this was an observational study; therefore, EPs did not have the possibility to use the results of the Vscan examination to change their decision-making process. This prevented investigators from quantifying the effective timesaving and cost reduction in such a patient population.

CONCLUSION

Emergency bedside US with Vscan in patients with non-traumatic abdominal pain had demonstrated good diagnostic performance, when compared to traditional radiology imaging.

Bedside US can be performed and interpreted by EPs and it could represent an important tool to reduce time in clinical decision-making, improve patient outcome and reduce time and costs to patients when compared with traditional radiological exams.^{20,21}

Conflict of Interest: The author declared receiving a fund from General Electrics to conduct this study.

REFERENCES

- American College of Emergency Physicians. Clinical policy: Critical issues for the initial evaluation and management of patients presenting with a chief complaint of nontraumatic acute abdominal pain. *Ann Emerg Med.* 2000 Oct;36(4):406–15.
- Kamin RA, Nowicki TA, Courtney DS, Powers RD. Pearls and pitfalls in the emergency department evaluation of abdominal pain. *Emerg Med Clin North Am.* 2003;21:61–72.
- Jung PJ, Merrell RC. Acute abdomen. *Gastroenterol Clin North Am.* 1988 Jun;17(2):227–44.
- Macaluso C, McNamara. Evaluation and management of acute abdominal pain in the emergency department. *Int J Gen Med.* 2012 Sep;5:789–97.
- Kelso LA, Kugelmas M. Nontraumatic abdominal pain. *AACN Clin Issues.* 1997 Aug;8(3):437–48.
- Powers RD, Guertler AT. Abdominal pain in the ED: Stability and change over 20 years. *Am J Emerg Med.* 1995 May;13(3):301–3.
- Hastings RS, Powers RD. Abdominal pain in the ED: a 35 year retrospective. *Am J Emerg Med.* 2011 Sep;29(7):711–6.
- Marston WA, Ahlquist R, Johnson G, Meyer AA. Misdiagnosis of ruptured abdominal aortic aneurysms. *J Vasc Surg.* 1992 Jul;16(1):17–22.
- Kachalia A, Gandhi TK, Puopolo AL, Yoon C, Thomas EJ, Griffey R, et al. Missed and Delayed Diagnoses in the Emergency Department: A Study of Closed Malpractice Claims From 4 Liability Insurers. *Ann Emerg Med.* 2007 Feb;49(2):196–205.
- Lukens TW, Emerman C, Efron D. The natural history and clinical findings in undifferentiated abdominal pain. *Ann Emerg Med.* 1993 Apr;22(4):690–6.
- Jess P, Bjerregaard B, Brynitz S, Holst-Christensen J, Kalaja E, Lund-Kristensen J, et al. Prognosis of acute nonspecific abdominal pain. *Am J Surg.* 1982 Sep;144(3):338–40.
- Ramoska EA, Sacchetti AD, Nepp M. Reliability of patient history in determining the possibility of pregnancy. *Ann Emerg Med.* 1989 Jan;18(1):48–50.
- Silver BE, Patterson JW, Kulick M, Schadt ME, Heller MB. Effect of CBC results on ED management of women with lower abdominal pain. *Am J Emerg Med.* 1995 May;13(3):304–6.
- Kizer KW, Vassar MJ. Emergency department diagnosis of abdominal disorders in the elderly. *Am J Emerg Med.* 1998 Jul;16(4):357–62.
- Lewis LM, Banet GA, Blanda M, Hustey FM, Meldon SW, Gerson LW. Etiology and clinical course of abdominal pain in senior patients: a prospective, multicenter study. *J Gerontol A Biol Sci Med Sci.* 2005 Aug;60(8):1071–6.
- Sanson TG, O'Keefe KP. EVALUATION OF ABDOMINAL PAIN IN THE ELDERLY. *Emerg Med Clin North Am.* 1996 Aug;14(3):615–27.
- Graff LG, Robinson D. Abdominal Pain and Emergency Department Evaluation. *Emerg Med Clin North Am.* 2001 Feb;19(1):123–36.
- Van Randen A, Laméris W, van Es HW, van Heesewijk HPM, van Ramshorst B, ten Hove W, et al. A comparison of the Accuracy of Ultrasound and Computed Tomography in common diagnoses causing acute abdominal pain. *Eur Radiol.* 2011 Jul 2;21(7):1535–45.

19. Hustey FM, Meldon SW, Banet GA, Gerson LW, Blanda M, Lewis LM. The use of abdominal computed tomography in older ED patients with acute abdominal pain. *Am J Emerg Med.* 2005 May;23(3):259–65.
20. Shuman WP, Ralls PW, Balfe DM, Bree RL, DiSantis DJ, Glick SN, et al. Imaging evaluation of patients with acute abdominal pain and fever. American College of Radiology. ACR Appropriateness Criteria. *Radiology.* 2000 Jun;215 Suppl:209–12.
21. Puylaert JBCM. Ultrasonography of the acute abdomen. *Radiol Clin North Am.* 2003 Nov;41(6):1227–42.