

## On Yıldan Uzun Süre Üreteral J Stentle Yaşamının Sonuçları

Results Of Living With An Encrusted Double J Stent For More Than 10 Years

Ekrem Akdeniz<sup>1</sup>, Kenan Öztoran<sup>2</sup>

1 Samsun Gazi State Hospital, Department of Urology, Samsun, Turkey

2 Omer Halisdemir University, Training and Research Hospital, Department of Urology, Nigde, Turkey



Geliş tarihi (Submitted): 16.11.2019  
Kabul tarihi (Accepted): 03.03.2020

### Yazışma / Correspondence

**Ekrem Akdeniz**  
Barış Bulvarı, Kadıköy Mahallesi,  
No:199, İlkadım, 55090  
Samsun / Türkiye  
E mail: ekrem.akdeniz@saglik.gov.tr  
Tel: +90 362 311 1500

### ORCID

E.A. 0000-0002-0666-9579  
K.O. 0000-0003-1466-2125



Bu eser Creative Commons Atf-  
Gayriticari 4.0 Uluslararası Lisansı ile  
lisanslanmıştır.

### Özet

**Amaç:** Unutulmuş üreteral stentlerin enfeksiyon, enkrustasyon, taşlaşma ve böbrek yetmezliği gibi majör komplikasyonları vardır. Bu komplikasyonlar stentin kalış süresi ile artar. Bu çalışmada 10 yıldan uzun süre üreteral stentle yaşayan hastaların tedavi yönetimi ve stentlerin hastalara verdiği zararlar tartışılmıştır.

**Gereç ve Yöntemler:** 10 yıldan uzun süredir enkruste üreteral stentle yaşayan üç hastanın klinik verileri retrospektif olarak değerlendirildi.

**Bulgular:** Her üç hastada tipik stent semptomları (hematüri, yan ağrısı, acil idrar hissi, vs) olmadığı için doktora başvurmadıklarını belirtti. İki hasta sepsis ile bir hasta komplike üriner sistem enfeksiyonu ile tarafımıza başvurdu. Uzun süreli stente bağlı olarak 2 hasta ileri derecede böbrek fonksiyon kaybı gelişirken, 1 hasta böbreğini kaybetti. Nonfonksiyonel böbrekli hastaya laparoskopik nefroureterektomi yapılırken, diğer iki hastaya tek seans multi-modal nefron koruyucu cerrahi uygulandı.

**Sonuç:** Teknolojideki gelişmelere rağmen unutulmuş stentler sepsise ve böbrek fonksiyon kaybına neden olmaya devam etmektedir. Enkruste stente bağlı komplikasyonlardan korunmanın en güzel yolunun unutmamak olduğunu düşünüyoruz.

**Anahtar Kelimeler:** Double-J stent, Enkrustasyon, Tedavi

### Abstract

**Objective:** Forgotten ureteral stents (FUS) may entail major complications such as infection, migration, encrustation, stone formation, and kidney failure. These complications increase with duration of stent indwelling. We discuss our experience of therapeutic approaches to treatment management of patients living with double J (DJ) stents for more than 10 years.

**Material and Methods:** Data for three patients living encrusted DJ stents for more than 10 years were evaluated retrospectively.

**Results:** All three subjects stated that they did not present to physicians due to absence of typical stent symptoms (such as hematuria, flank pain, and urgency). All three patients presented to us with urinary tract symptoms. Advanced renal function loss was present in two patients, and non-functional kidney in one. Laparoscopic nephroureterectomy was performed on the patient with a non-functional kidney, and multi-modal nephron-sparing surgery on the other two.

**Conclusions:** Despite all the many advances in technology, long-term encrusted stents lead to sepsis and loss of kidney function. We think that not forgetting is the best means of protection against encrusted stent-related complications.

**Keywords:** Double-J stent; Encrustation; Forgotten; Treatment

## INTRODUCTION

The double J (DJ) stent provides upper urinary tract drainage and is widely used in urological practice. It must remain in the body for a limited period and must be removed at the appropriate time. The ideal DJ stent removal time is unknown since this will depend on the stent indication (stone, ureteral stricture, oncological operations, iatrogenic causes, etc.). However, the majority of urologists remove DJ stents 1-2 weeks after ureterorenoscopic lithotripsy (URSL) (1).

Although DJ stents are reliable and practical in terms of patient health, they may become encrusted and retained if indwelling is prolonged. Major complications may develop as a result, including infection, impaired renal function, migration, encrustation, stone formation, multiple fragmentation of stent and even death (2). Encrustation rates increase in line with stent indwelling time. Encrustation is observed in 9.2% of stents removed within six weeks, but in 76.3% of those removed within 12 weeks (3). Stents remaining in the body for more than one year are known as forgotten ureteral stents. Forgotten DJ stents are difficult to treat due to intense encrustation. The level of encrustation will increase in line with stent indwelling time, and more complicated interventions are required for treatment. Multimodal treatment, including shock wave lithotomy, cystolithotripsy, ureteroscopy, percutaneous nephrolithotomy, or open surgery, either individually or in combination, are required for the successful removal of such stents (4, 5).

Even minor encrusted stents represent a stressful situation for urologists, while major encrusted stents are difficult, time-consuming, complex, high-risk, and costly (6). Forgotten DJ stents associated with increased DJ stent use have appeared in the literature, but DJ stents forgotten for longer than 10 years are a rare phenomenon.

## MATERIAL AND METHODS

Three patients with 10-year encrusted stents were treated between January 2017 and December 2018. During this period, we retrospectively reviewed the medical charts of all patients. Stent indwelling time was calculated from the time of insertion.

Stent encrustation and presence of stone were

evaluated using the kidney ureter and bladder (KUB) grading system and non-contrast computed tomography (CT). Dietilen triamine penta-acetic acid (DTPA) renal scans were performed to assess kidney functions. The type of treatment administered was based on radiological and clinical findings. Negative bacterial blood and urine cultures were obtained before surgery. Three patients underwent surgery together with concurrent antibiotic therapy.

Combined multimodal endourological procedures involving cystoscopy, cystolithotripsy (CLT), retrograde ureterorenoscopic lithotripsy (URSL), percutaneous nephrolithotomy (PCNL), and transperitoneal laparoscopic nephroureterectomy (LNU) were performed as applicable under conditions of general anesthesia in the same session.

PCNL was performed with the help of a rigid 24F nephroscope, ureterorenoscopy (URS) using a 8F semi-rigid ureteroscope, and flexible-URS with a fluoroscopy-guided 7.5F flexible ureteroscope. Holmium laser or pneumatic lithotripters were employed as intracorporeal lithotripters. Procedures were carried out in the dorsal lithotomy position under general anesthesia. Pneumatic lithotripters were also employed for intravesical lithotripsy. Retrograde URSL was performed subsequently. The ureteroscope was inserted with a guidewire into the ureteral orifice under fluoroscopic guidance next to the encrusted stent. At intracorporeal lithotripsy, a holmium laser was used to break down the encrustation and stone covering the stent. Subjects were next placed in the prone position for PCNL procedures or in the 70° lateral decubitus position for LNU. Percutaneous access was achieved with a middle calyceal puncture. Holmium laser lithotripsy was then applied along the proximal coil of the stent to disintegrate the stone. LNU was performed using the transperitoneal laparoscopic method. Appropriate imaging was performed in the postoperative period in order to verify that patients were stone- and stent-free.

## RESULT

One woman and two men aged 64, 84 and 54 years, respectively, were included in our study. Demographics, and clinical and operative data are summarized in tables 1-2. All had one-side DJ stents. Indwelling times

were 12, 10, and 10 years, retrospectively. The female patient had received a DJ stent during gynecological surgery, and the other two patients after URSL. The female patient stated that she had been operated overseas in 2006, but that since she did not speak the same language as the surgical team she knew nothing about the DJ stent. The other two patients stated they had been

told nothing about their DJ stents by the surgical teams. Two patients presented to us with septic manifestations (body temperature >38 °C, white blood cell count >14,000, heart rate >90/min heart rate), and the youngest patient presented due to complicated urinary tract infection (UTI). Escherichia coli growth was determined in the urine cultures of the patients with sepsis.

**Table 1.** Patients' characteristics (E.Coli: Escherichia Coli, URSL: Ureterorenoscopic lithotripsy, UTI: Urinary tract infection)

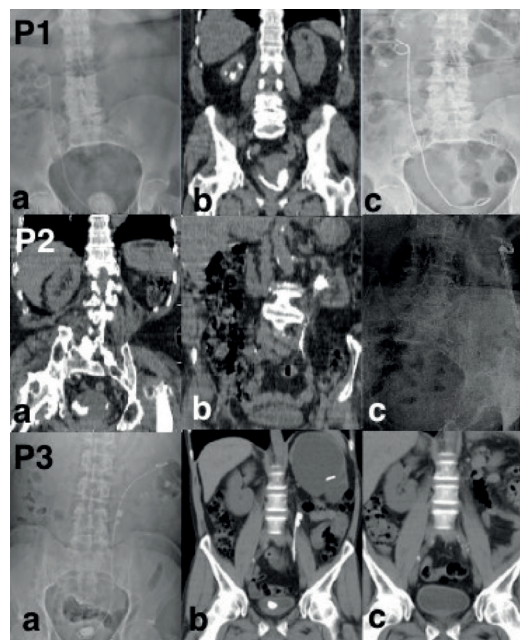
N	Age (year)/sex	BMI (kg/m <sup>2</sup> )	Admission	Stent indications	Indwelling time (years)	Split renal function in renogram	Preoperative urine culture
1	64/F	32.9	Septic	Gynecologic	12	18%	E.Coli
2	82/M	24.2	Septic	URSL	10	24%	E.Coli
3	54/M	27.1	UTI	URSL	10	6%	No growth

**Table 2.** Degree of encrustation and patients' operative data (CLT: Cystolithotripsy; f-URSL: Flexible ureterorenoscopic lithotripsy; LNU: Laparoscopic nephroureterectomy; PCNL: Percutaneous nephrolithotomy lithotripsy; URSL: Ureterorenoscopic lithotripsy)

N	Location of Encrustation			Procedures	Postoperative diversion	Operation time (min)	Hospital stay (days)
	Kidney	Ureter	Bladder				
1	++	++	+++	CLT + URSL + f-URSL	Double J stent	290	33
2	+++	++	+++	CLT + URSL + PCNL	Nephrostomy	220	11
3	+	++	+++	CLT + URSL + LNU	-	190	12

The female patient, who condition was more serious, was given iv imipenem, and the other patients iv ceftriaxone. The patients' general conditions improved, and (DTPA) renograms were performed. Split renal functions were 18%, 24% and 6%, respectively. Patients' serum creatinine levels were 0.63, 0.72 and 0.82 mg/dL, respectively, and no kidney failure was observed in any case.

The proximal pigtail exhibited areas of calcification 57 mm<sup>2</sup> (at URSL), 245 mm<sup>2</sup> (at PCNL) and 38 mm<sup>2</sup> (at LNU) in the renal pelvis, while significant encrustation was observed in the distal pigtail in bladder stone areas of 451 mm<sup>2</sup>, 412 mm<sup>2</sup> and 432 mm<sup>2</sup>, respectively. The entire length of the stent exhibited mild encrustation, and DJ stent was partially adhered to the ureteral mucosa (Figure 1). Lithotripsy in all three cases was performed with pneumatic lithotripters in the intravesical region and with laser lithotripters in the intraureteric and intrarenal regions. In the case of the



**Figure 1.** Radiologic images of patients (P1: Patient 1, P2: Patient 2, P3: Patient 3; a and b, preoperative; c, postoperative images)

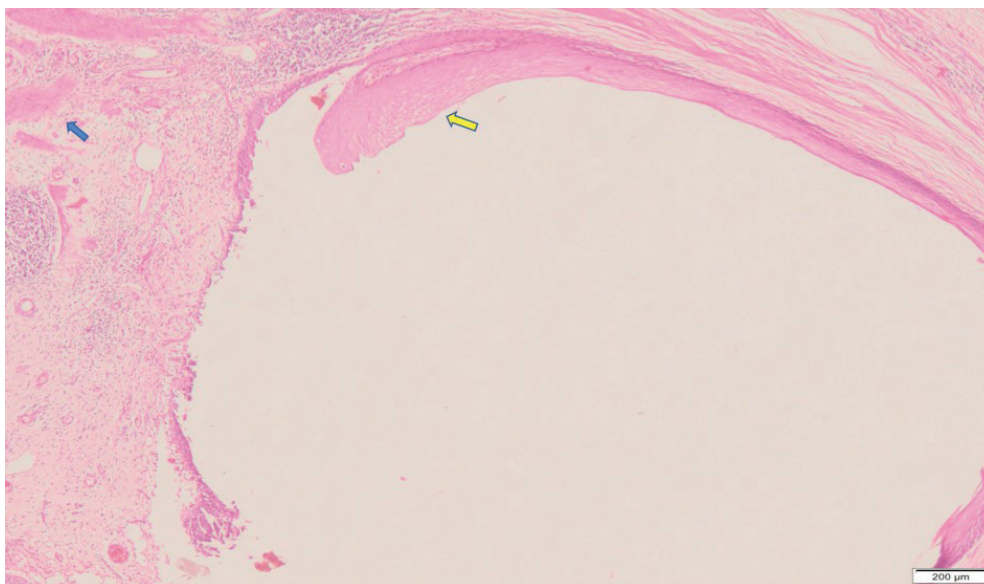
patient undergoing f-URSL, the stent was removed in a retrograde manner as a single part, in the patient undergoing PCNL it was removed in a retrograde and antegrade manner in two parts, and in the patient undergoing LNU the stent was removed in two parts (Figure 2).

The presence or absence of extravasation was observed using antegrade pyelography in the patient undergoing PCNL and with retrograde pyelography in the f-URSL case. A nephrostomy tube and DJ stent, respectively, were installed as diversions. The nephrostomy tube was removed after two days, and the DJ stent after 15 days. At follow-up, the patient undergoing PCNL was stone-free, while residual stone was observed in the patient receiving f-URS. No elevation in creati-

nine values was observed in any of the three patients.

A 1.2-J energy holmium laser at a frequency of 15 Hz was used for intraureteric lithotripsy in the case involving nephroureterectomy. However, lithotripsy was concluded before arriving at the middle ureter due to development of perforation in the ureter. A significant quantity of irrigation fluid was extravasated in the retroperitoneum during LNU. Accordingly, intraureteric laser lithotripsy was performed at a frequency of 6 Hz and 0.6-J energy in the other two cases.

Histopathological examination of the ureter revealed squamous metaplasia in the urothelial epithelium, intense inflammation in the mucosa, edema and degeneration in the muscularis mucosa, and fragmentation in the muscularis mucosa (Figure 2).



**Figure 2.** Pathological findings of the patient (Squamous metaplasia in the urothelial epithelium (yellow arrow), and fragmentation in the muscularis mucosa (blue arrow) in addition to mixed type inflammatory cell infiltration in the subepithelial mucosal area)

## DISCUSSION

Double J stents are frequently employed in urological practice. However, these stents also have various side-effects, and as technology has advanced, new tools and stents have been developed in order to reduce stent morbidity (7). One of the most important complications of DJ stents is that they may be forgotten. Stents indwelling for more than one year are known

as forgotten ureteral stents (FUS). There have been numerous publications concerning FUS in the literature (4-6, 8-10). However, it is rare for DJ stents to be forgotten for longer than 10 years. Only two patients in Adanur and Ozkaya's study of FUS in a 54-patient series had indwelling DJ stents for more than 10 years. Polat et al. reported a figure of one out of 59 patients, and Bostancı et al. none out of 19 patients (8-10).



Three patients with DJ stents forgotten for more than 10 years were included in our study, together with a discussion of their clinical management. Despite improvements in technology, stent-related morbidities still occur. Problems associated with stents generally involve typical symptoms affecting day-to-day activities, such as hematuria, flank pain, urgency, urge incontinence and bacteriuria (11, 12). However, major complications such as impaired renal function, migration, encrustation, stone formation, multiple fragmentation of stent and even death may occur as the duration of stent indwelling increases (2). The patients in our study were not sufficiently disturbed by typical stent symptoms (hematuria, flank pain, and urgency) to seek medical attention. This may be attributed to irritative symptoms being reduced to a minimum due to improvements in stent technology. Stent encrustation results from uric acid or calcium oxalate adhering to the stent surface. While calcium phosphate and ammonium-magnesium-phosphate are also capable of precipitating, these require a higher pH level, which may be observed in various specific urinary tract infections (13). Although it is still unclear how encrustation in sterile urine occurs, the phenomenon may depend on pH, ionic strength and the hydrophobic characteristics of the biomaterial involved (14). Severe encrustation accompanied by stone formation can result in urinary tract obstruction, urinary sepsis, and possible compromise of renal function (15). Two of our patients presented to us with intensive encrustation and calcification due to sepsis, and one due to complicated urinary system infection. Severe kidney damage developed in two patients due to FUS, and one patient unfortunately lost the kidney.

Calcification was most common in the lower tip, and was disintegrated by pneumatic lithotripsy. The intravesical DJ remained stable in the bladder due to intraureteric and intrarenal extension, and easy, effective, and rapid lithotripsy was thus carried out despite intensive calcification.

Due to chronic FUS, macroscopically the ureteral mucosa were pale and the ureteral tissue was fragile, while histopathologically, we observed chronic inflammation and impaired integrity of the muscularis pro-

pria. The ureteral mucosa had become disposed to perforation because of these anatomical weaknesses. An aggressive approach was adopted for lithotripsy in the case undergoing LNU, and holmium laser was applied with 365 µm bare fibers at a frequency of 15 Hz and energy of 1.2 J. However, lithotripsy was concluded without arriving at the middle ureter due to development of multiple damage in the mucosa. A large quantity of irrigation fluid was extravasated in the retroperitoneum during LNU. This extravasation was attributed to weakness of the ureteral tissue. Greater caution was employed in the other cases, and lithotripsy was performed with low frequency (6 Hz) and energy (0.6 J) levels. No extravasation was observed in these other two cases. We recommend the use of low frequency and low energy for intraureteric lithotripsy in order to avoid disturbing or alarming complications such as ureter perforation or ureteral avulsion that may occur in weak tissue in association with FUS.

Another major complication of forgotten stents is fragmentation. This results from loss of tensile strength caused by increasing rigidity and degeneration of the polymer materials employed. The risk of encrustation and fragmentation depends on the material employed in the stent manufacture (16). Bostancı et al. reported a ureteral stent fragmentation rate of 15.7%, and Adanur and Ozkaya of 7.4% (8, 10). In the present study, too, the DJ stent was observed to be adhered to the ureteral mucosa in some regions during intraureteric lithotripsy. Although the encrustations in this region were disintegrated using laser lithotripsy in close proximity to the stent and the stents had been indwelling for 10 years or more, no fragmentation was observed in the stents themselves. This was attributed to improvements in stent technology.

DJ stent indwelling exceeding 10 years is a rare condition, and is generally described in the form of case reports. Restaino et al. reported a patient with 15-year bilateral DJ stent, describing removal with cystoscopy and, interestingly, no stone formation in the stents inserted 15 years previously (17). Bidnur et al. achieved stone-free status in a patient with 12-year DJ stent using PCNL+URSL+CLT (18). Our single-session multimodal treatment was similar to that described by Bidnur et al.

Various strategies have been developed to avoid the forgetting of ureteral stents, such as computer tracking systems, automatic billing systems, and smartphone applications. However, despite all these technological measures, it has still not been possible to ensure that stents are always removed on time. One study of the use of computerized tracking reported a missed stent rate of 1.2% (19). Rates of 1.2% with the billing record system and 0.5% with smartphone apps have been reported (20, 21). We think that, no matter what measures are taken, the problem of missed stents cannot be eradicated so long as the human factor (patient or doctor) remains, and that new types of ureteral stents capable of self-absorption need to be developed in order to protect against missed stents.

### CONCLUSION

Forgetting is a human weakness and an inevitable part of life. In our study, advances in technology were seen to prevent minor complications such as FUS-related hematuria, flank pain, urgency, and urge incontinence, but not major complications such as impaired renal function, loss of kidney, urinary tract infection and sepsis. Patients and physicians have a responsibility to be more careful if FUS is to be prevented, while the role of technology must be to eliminate the human factor entirely and to create a new DJ stent (such as stent that is spontaneously absorbed after a specific period of time).

### REFERENCES

1. Türk C, Petřík A, Sarica K, Seitz C, Skolarikos A, Straub M, et al. EAU Guidelines on Interventional Treatment for Urolithiasis. *Eur Urol* 2016;69:475-82.
2. Arenas JL, Shen JK, Keheila M, Abourbih SR, Lee A, Stokes PK, et al. Kidney, Ureter, and Bladder (KUB): A Novel Grading System for Encrusted Ureteral Stents. *Urology* 2016;97:51-55.
3. el-Faqih SR, Shamsuddin AB, Chakrabarti A, Atassi R, Kardar AH, Osman MK, et al. Polyurethane internal ureteral stents in treatment of Stone patients: morbidity related to indwelling times. *J Urol* 1991;146:1487-1491.
4. Acosta-Miranda AM, Milner J, Turk TM. The FECal Double-J: a simplified approach in the management of encrusted and retained ureteral stents. *J Endourol* 2009;23:409-415.
5. Rana AM, Sabooh A. Management strategies and results for severely encrusted retained ureteral stents. *J Endourol* 2007;21:628632.
6. Sancaktutar AA, Soylemez H, Bozkurt Y, Penbegul N, Atar Y. Treatment of forgotten ureteral stents: How much does it really cost? A cost-effectiveness study in 27 patients. *Urol Res* 2012;40:317-325.
7. Beiko DT, Knudsen BE, Denstedt JD. Advances in ureteral stent design. *J Endourol* 2003;17:195-199.
8. Adanur S, Ozkaya F. Challenges in treatment and diagnosis of forgotten/encrusted double-J ureteral stents: the largest single-center experience. *Ren Fail* 2016;38:920-6.
9. Polat H, Yücel MÖ, Utangaç MM, Benlioğlu C, Gök A, Çift A, et al. Management of Forgotten Ureteral Stents: Relationship Between Indwelling Time and Required Treatment Approaches. *Balkan Med J* 2017;34:301-307.
10. Bostanci Y, Ozden E, Atac E, Yakupoglu YK, Yilmaz AF, Sarikaya S. Single session removal of forgotten encrusted ureteral stents: Combined endourological approach. *Urol Res* 2012;40:523-529.
11. Chambade D, Thibault F, Niang L, Lakmichi MA, Gattegno B, Thibault P, et al. Study of the safety of double-J ureteric stents. *Prog Urol* 2006;16:445-449.
12. Halebian G, Kijvikai K, de la Rosette J, Preminger G. Ureteral stenting and urinary stone management: a systematic review. *J Urol* 2008;179:424-430.
13. Chew BH, Duvdevani M, Denstedt JD. New developments in ureteral stent design, materials and coatings. *Expert Rev Med Devices* 2006;3:395-403.
14. Keane PF, Bonner MC, Johnston SR, Zafar A, Gorman SP. Characterization of biofilm and encrustation on ureteric stents in vivo. *Br J Urol* 1994;73:687-91.
15. Singh V, Srinivastava A, Kapoor R, Kumar A. Can the complicated forgotten indwelling ureteric stents be lethal? *Int Urol Nephrol* 2005;37:541-546.
16. Zisman A, Siegel YI, Siegmann A, Lindner A. Spontaneous ureteral stent fragmentation. *J Urol* 1995;153:718-721.
17. Restaino S, Fanfani F, Vittori M, D'Addressi A, Scambia G, Costantini B. Bilateral Ureteral Stent Removal after 15 Years: A Case Report. *J Minim Invasive Gynecol* 2018;25:920-922.

18. Bidnur S, Huynh M, Hoag N, Chew B. An Indwelling Ureteral Stent Forgotten for Over 12 Years. *J Endourol Case Rep* 2016;2:135-7.
19. Ather MH, Talati J, Biyabani R. Physician responsibility for removal of implants: the case for a computerized program for tracking overdue double-J stents. *Tech Urol* 2000;6:189-192.
20. Macneil JWH, Michail P, Patel MI, Ashbourne J, Bariol SV, Ende DA, et al. Semi-Automatic Electronic Stent Register: a novel approach to preventing ureteric stents lost to follow up. *ANZ J Surg* 2017;87:837-841.
21. Molina WR, Pessoa R, Donalisio da Silva R, Kenny MC, Gustafson D, Nogueira L, et al. A new patient safety smartphone application for prevention of “forgotten” ureteral stents: results from a clinical pilot study in 194 patients. *Patient Saf Surg* 2017;11:10.