

Impact Factor:

ISRA (India) = 4.971
ISI (Dubai, UAE) = 0.829
GIF (Australia) = 0.564
JIF = 1.500

SIS (USA) = 0.912
PIHHI (Russia) = 0.126
ESJI (KZ) = 8.716
SJIF (Morocco) = 5.667

ICV (Poland) = 6.630
PIF (India) = 1.940
IBI (India) = 4.260
OAJI (USA) = 0.350

SOI: [1.1/TAS](#) DOI: [10.15863/TAS](#)

International Scientific Journal Theoretical & Applied Science

p-ISSN: 2308-4944 (print) e-ISSN: 2409-0085 (online)

Year: 2020 Issue: 05 Volume: 85

Published: 28.05.2020 <http://T-Science.org>

QR – Issue



QR – Article



Yuldoshali Sulaymanovich Egamov
Andijan State Medical Institute
Researcher

Akhtam Ergashovich Ruziev
Bukhara State Medical Institute
Researcher

SUBSTANTIATION OF LYMPHOTROPIC THERAPY ON THE MODEL OF ULCER COLITIS IN EXPERIMENT

Abstract: The purpose of the study - study the state of the lymphatic system of the mesentery of the large intestine in experimental ulcerative colitis to substantiate lymphotropic therapy. For the experiment, we used 10-12 month-old dogs (24pcs), in which experimental ulcerative colitis was reproduced by rectal administration of an acetic acid solution. To study the state of activity of the lymphatic system of the large intestine, we used a method for studying the resorption of Evans blue solution after intraperitoneal and submucosal administration of the large intestine.

Key words: lymphatic system, submucosal administration, intestine, morphological changes, generally accepted methods, experimental ulcerative colitis, modeling, lymphotropic therapy.

Language: English

Citation: Egamov, Y. S., & Ruziev, A. E. (2020). Substantiation of lymphotropic therapy on the model of ulcer colitis in experiment. *ISJ Theoretical & Applied Science*, 05 (85), 361-366.

Soi: <http://s-o-i.org/1.1/TAS-05-85-70> **Doi:**  <https://dx.doi.org/10.15863/TAS.2020.05.85.70>

Scopus ASCC: 2700.

Introduction

The study of morphological changes in the large intestine during the modeling of ulcerative colitis was carried out using generally accepted methods.

It has been established that impaired lymphatic circulation in the large intestine with experimental ulcerative colitis contributes to complications of the intestine in the postoperative period, which can be reduced by the use of lymphotropic therapy in the complex treatment of ulcerative colitis in patients. Inflammatory bowel diseases, including ulcerative colitis (UC), are currently one of the urgent problems of gastroenterology, which are caused by the prevalence of severe complicated forms of the course, with high mortality and difficulty in diagnosing and monitoring the effectiveness of therapy [8; thirteen]. As you know, UC develops as a result of a pathological immune response to antigens of the intestinal microflora in the presence of a hereditary predisposition, has a chronic relapsing course [8; 14].

Of great importance in the pathogenesis of UC is given to antigens of normal microflora, to which the tolerance of the immune system is lost, as well as opportunistic microorganisms that continuously stimulate the intestinal immune system, which underlies the triggering and maintenance of the autoimmune process [1; 3; 7; 9; eleven; 14; fifteen].

Despite the fact that many questions of the pathogenesis of nonspecific UC are still insufficiently studied, the theory that the intestinal flora triggers an aberrant intestinal immune response and subsequent inflammation in genetically predisposed people is described in more detail [10]. According to lymphatic theory, primary changes develop in the lymph nodes of the mesentery and lymphoid follicles of the intestinal wall, which leads to lymphatic edema of the submucosal layer, resulting in destruction and granulomatosis of the intestinal wall [2]. It is important to note that the peak incidence of UC is in the age group of 20 to 40 years, which is the most active socially [6; 12].

II. Literature review

Impact Factor:

ISRA (India)	= 4.971	SIS (USA)	= 0.912	ICV (Poland)	= 6.630
ISI (Dubai, UAE)	= 0.829	PIHHI (Russia)	= 0.126	PIF (India)	= 1.940
GIF (Australia)	= 0.564	ESJI (KZ)	= 8.716	IBI (India)	= 4.260
JIF	= 1.500	SJIF (Morocco)	= 5.667	OAJI (USA)	= 0.350

III. Analysis

However, the morphological criteria of UC, reliable from the standpoint of evidence-based medicine, are still not sufficiently developed [4]. Unresolved issues make ulcerative colitis relevant in relation to its treatment.

In this regard, it is important to further study the pathogenesis of UC, as well as the development and preclinical testing of new approaches to diagnosis and treatment. This is possible under the conditions of experimental modeling of UC in animals [5]. However, the morphological criteria of UC, reliable from the standpoint of evidence-based medicine, are still not sufficiently developed [4]. Unresolved issues make ulcerative colitis relevant in relation to its treatment.

In this regard, it is important to further study the pathogenesis of UC, as well as the development and preclinical testing of new approaches to diagnosis and treatment. This is possible under the conditions of experimental modeling of UC in animals [5].

The main part of the work was the modeling of experimental ulcerative colitis. To conduct the experiments, we used 10-12 month old dogs (24 pieces) on which we conducted serial experiments. The animals were divided into 3 groups: 1) a control group (8 pieces) for studying the activity of the lymphatic system of the large intestine and its mesentery in normal; 2) a group of animals to create a model of ulcerative colitis, which consisted of two series: with rectal use of 4% (4 pieces) and 10% (4 pieces) of acetic acid solution; 3) a group of animals (8pcs) with the obtained model of ulcerative colitis in which the state of activity of the lymphatic system of the large intestine and its mesenteries was studied. The animals of the first - control group were used to study the normal state of the lymphatic system of the intestine and its mesentery. We used the experience of studying the resorption of Evans blue from the mesentery of the intestines of the animal. The experiments were carried out in the operating unit of the Central Scientific Research Laboratory of AGMI. Under general intravenous anesthesia, with a fractional injection of a 2% sodium thiopental solution at a rate of 5 mg / kg, observing the rules of asepsis and antiseptics, a mid-median laparotomy of 15 cm length was performed. Hemostasis. After revision of the abdominal cavity organs, a section of the large intestine and an additional part of the loop of the large intestine with the mesentery were removed from the wound, which were isolated from the wound using sterile tampons. In the mesentery of this part of the

large intestine in three places: the root, the middle part, the marginal part of the intestine, and additionally, 0.1 ml of a 0.1% solution of blue dye were injected subzero into the wall of the intestine. The resorption time of the dye introduced at four points until their color completely disappeared was determined visually and recorded by a stopwatch. After the experiment, the intestine is set back into the abdominal cavity. The surgical wound is sutured in layers, tightly. Dogs after leaving the state of anesthesia were transferred to the vivarium.

The second group of animals was used to create a model of ulcerative colitis. The main requirements for the model were simplicity, the short period necessary for its creation and its low cost. And at the same time it should be as close as possible in clinical, morphological, immunological parameters and hematological picture to ulcerative colitis. When analyzing the literature, in our opinion, the most optimal option for modeling ulcerative colitis that meets the above requirements was a chemically induced model, a method of rectal administration of 4% and 10% acetic acid. In accordance with the methodology, after a cleansing enema, in experimental animals, 2-3 ml of 4% or 10% acetic acid was rectally, fractionally, introduced into the cavity of the large intestine. Dogs were monitored for 3 days. 5 days after the introduction of the acetic acid solution, we performed a repeated mid-median laparotomy, a resection of that part of the large intestine into the cavity of which acetic acid was introduced 5 days ago. After applying the anastomosis end to end, the surgical wound was sutured in layers, tightly. Experimental dogs, after recovering from anesthesia, were transferred to the vivarium.

Since a typical clinical and morphological picture of ulcerative colitis was not established in animals of the second group, we used the third group of animals, where we used a more concentrated solution of acetic acid to create the model. Why, after preparing the animal according to the above method, rectally, fractionally, we injected more concentrated acetic acid in an amount of 2-4 ml into the cavity of the large intestine and observed the condition of the animal for 3 days. Further, all operations and the study of the rate of hemodynamic dynamics using Evans blueness was carried out as described above.

IV. Discussion

In the study of the state of the lymphatic system of the large intestine and its mesentery is normal. The results of the experiment are shown in table № 1.

Impact Factor:

ISRA (India) = 4.971 SIS (USA) = 0.912 ICV (Poland) = 6.630
 ISI (Dubai, UAE) = 0.829 PIIHII (Russia) = 0.126 PIF (India) = 1.940
 GIF (Australia) = 0.564 ESJI (KZ) = 8.716 IBI (India) = 4.260
 JIF = 1.500 SJIF (Morocco) = 5.667 OAJI (USA) = 0.350

Table № 1. The resorption time of Evans blue from the mesentery of the intestines of animals of the control group (intact)

№ experiments	The pressure of Evans blue and the time of its resorption (min. Sec.)			
	The root of the mesentery	The middle part of the mesentery	The marginal part of the mesentery of the intestine	The wall of the intestine is the subserous part
1	3.22.	3. 52.	4.15.	4. 22.
2	3.29.	3. 54.	4.17.	4. 25.
3	3.24.	3. 55.	4.21.	4. 29.
4	3.31.	3 . 57.	4.18.	4 . 34.
5	3.33.	3. 52.	4.15.	4. 36.
6	3.38.	3. 59.	4.24.	4. 39.
7	3.37.	3. 53.	4.26.	4. 19.
8	3.31.	3. 50.	4.19.	4. 34.

From the data given in the table it can be seen that the rate of resorption of the Evans blue in time, at different points of the mesentery and the subserous layer of the large intestine, has differences.

When analyzing the results obtained from the second group of animals, it was shown that within 3 days after the administration of a rectally 4% solution of acetic acid, no clinical and pathological changes in the experimental animals (clinical signs of intoxication, diarrhea with an admixture of mucus and blood, weight loss of the animal) were not was noted. When after 5 days the mid-median laparotomy was performed, we did not reveal any clearly pathologically changed sections of the large intestine.

Histological examination of the resected section of the large intestine revealed no obvious pathological changes. The mucous membrane of the colon had a

characteristic relief due to the presence of folds and crypts. The thickness of the mucous membrane throughout the colon is uneven. Crypts are located parallel to each other, often the bottom of them is somewhat widened, and reaches the muscle plate of the mucous membrane. Between the crypts are thin layers of loose unformed connective tissue (Fig. 1). Prismatic cells of highly cylindrical crypts are arranged in a row on the basement membrane, with a pronounced brush border. The nuclei of epithelial cells located usually in the lower third of the cell are round or oval. In the surface epithelium there are areas where epithelial cells containpyknotic kernels. Goblet cells are found mainly in the middle part of the crypts. On the drug, well-defined submucosal and muscle membranes of the colon are determined.

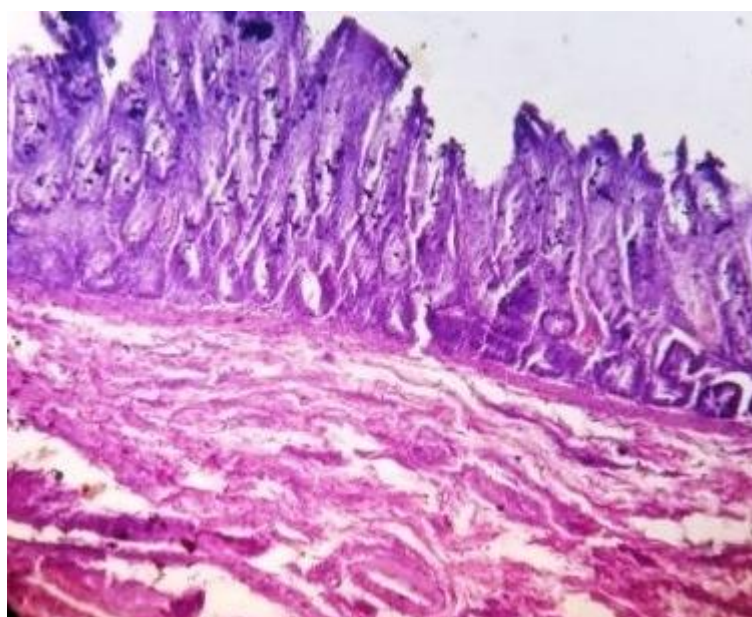


Fig. No. 1. The large intestine without signs of pathological Of changes. Coloring: hematoxylin -eosin. Ok. 10, about. 40.

In the second series of animals of the same group, where a 10% solution of acetic acid was injected to obtain a model of ulcerative colitis,

insignificant clinical signs of intoxication, diarrhea with an admixture of mucus were observed starting from the third day after administration. On the 5th day

Impact Factor:

ISRA (India) = 4.971
ISI (Dubai, UAE) = 0.829
GIF (Australia) = 0.564
JIF = 1.500

SIS (USA) = 0.912
PIHHI (Russia) = 0.126
ESJI (KZ) = 8.716
SJIF (Morocco) = 5.667

ICV (Poland) = 6.630
PIF (India) = 1.940
IBI (India) = 4.260
OAJI (USA) = 0.350

after the introduction of 10% acetic acid after laparotomy during revision of the abdominal cavity and in the projection of the large intestine, where acid was previously introduced rectally, the walls of the large intestine were slightly swollen, however, there were no obvious signs of inflammatory changes.

Histological examination of the wall of the resected section of the large intestine, microcopy showed that in some places minor point necrotic

sections of the mucous membrane were determined (Fig. 2). Where a mucosal defect was detected, the absence of damage to the basement membrane at the site, and slight local edema. That is, according to our data, in experimental dogs, we did not find pronounced clinical symptoms, as well as histological changes characteristic of ulcerative colitis, even in an experiment with the introduction of a 10% solution of acetic acid into the rectum.

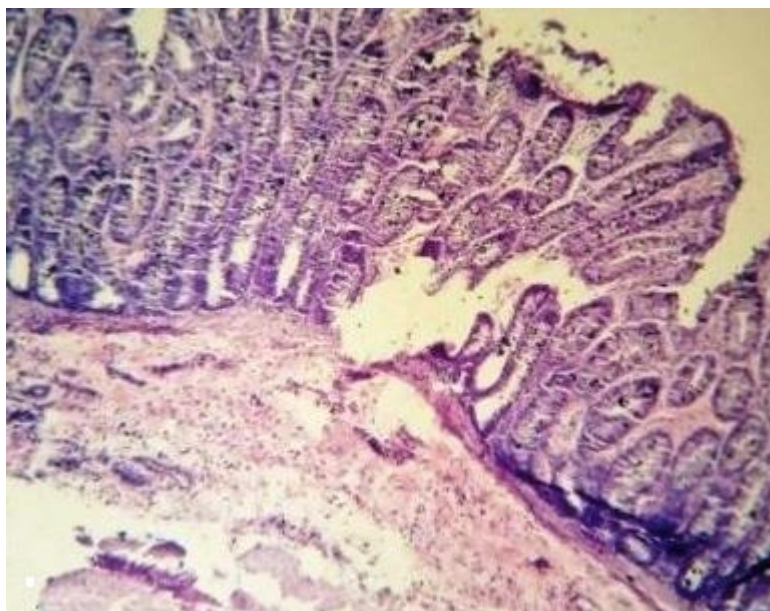


Fig. No. 2. Acute ulcer, slight necrosis of the thick mucous layer intestines. Coloring: hematoxylin -eosin. Ok. 10, about. 40.

In this regard, to create a model of ulcerative colitis, we used the third group of animals, where we used a more concentrated solution of acetic acid to create the model. Starting from the second day, the dog showed significantly more pronounced clinical signs: intoxication, diarrhea mixed with mucus and blood; experimental animals - stopped eating. On the 5th day after the introduction, an audit of the abdominal organs after laparotomy was performed in

the projection of the large intestine into the cavity of which acetic acid had previously been introduced rectally, the walls were significantly swollen, the vessels were hyperemic, and obvious signs of inflammation were visually determined. Here, before resection of the inflamed part of the large intestine, a study of the time of resorption of Evans blue was conducted. The results of the experiment are shown in table №. 2.

Table № 2. Resorption time of Evans blue from the mesentery of the animal's intestines after the creation of ulcerative colitis model

№ experiment	Points of introduction of Evans blue and the time of its resorption (min. Sec.)			
	Root of the mesentery	The middle part of the mesentery	The marginal part of the mesentery of the intestine	The wall of the intestine – subserous part.
1	6.39.	7. 21.	8.35.	8. 57.
2	6.44.	7. 19.	8.37.	8. 55.
3	6.49.	7. 43.	8.41.	8. 59.
4	6.35.	7. 37.	8.48.	9. 04.
5	6.51.	7. 39.	8.35.	8. 56.
6	6.38.	7. 29.	8.34.	8. 59.
7	6. 47.	7. 38.	8.46.	8. 59.
8	6.43.	7. 41.	8.39.	9. 05.

Impact Factor:

ISRA (India)	= 4.971	SIS (USA)	= 0.912	ICV (Poland)	= 6.630
ISI (Dubai, UAE)	= 0.829	PIHHI (Russia)	= 0.126	PIF (India)	= 1.940
GIF (Australia)	= 0.564	ESJI (KZ)	= 8.716	IBI (India)	= 4.260
JIF	= 1.500	SJIF (Morocco)	= 5.667	OAJI (USA)	= 0.350

The table shows that after modeling ulcerative colitis in dogs, there is a pronounced slowdown in lymph circulation in the mesentery and intestines 2 times or more in relation to the control group of animals.

After examining the resorption time of Evans blue, a resection of the altered part of the large intestine was performed. Macroscopically, in an isolated area of the large intestine, a wet and shiny mucous membrane was detected, covered with clots of blood and mucus, with numerous point hemorrhages mainly in the mucous membrane. On which round or irregular shapes are noted, usually small, superficial ulcers of various sizes and shapes, sometimes merging ulcerations caused exposure of

the entire colon wall. On the part of the mucous membrane, severe hyperemia was observed.

During histological examination of the wall of the resected area of the colon, under the microscope, significant necrotic areas were determined in the mucous membrane (Figs. 3 and 4). A large number of desquamated integumentary epithelial cells were determined. Deformation of crypts was detected, which are characterized by polymorphic changes, many of their sites became epithelial, lymphoid infiltration, accumulation of eosinophils, granulation tissue, or even slit-like ulcers were found in them. The muscle plate became edematous, muscle cell disintegration was observed, leukocyte infiltration occurred between myocytes, that is, all the histological signs of ulcerative colitis were evident.

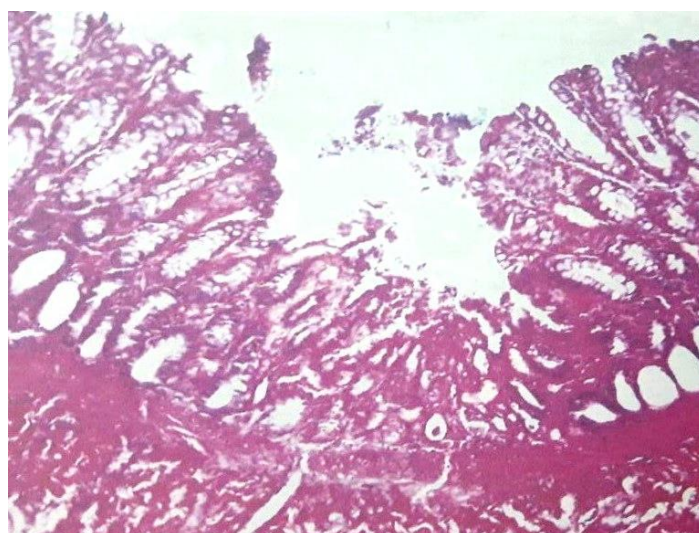


Fig. Number 3. Acute ulcer, necrotic process of the thick mucous layer intestines. Coloring: hematoxylin -eosin. Ok. 10, about. 40.

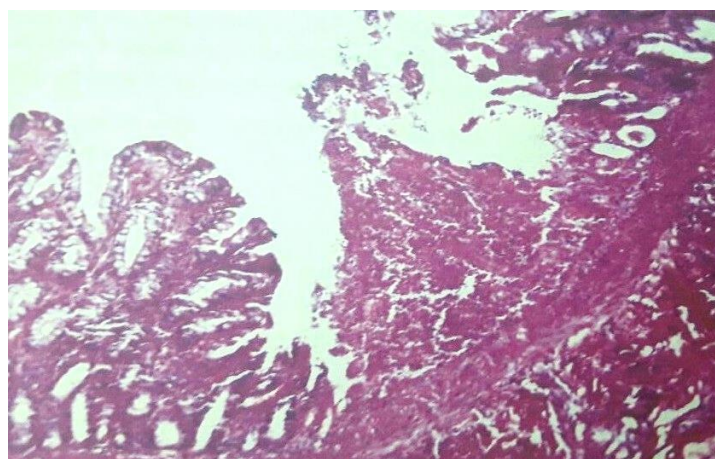


Fig. Number 4. Acute ulcer, necrotic process passes submucosal layer large intestine. Coloring: hematoxylin -eosin. Ok. 10, about. 40.

Analyzing the results of the study presented above, we can conclude that with the experimental model of ulcerative colitis in the mesentery of the intestine, a significant, two or more, slowdown of

lymphocyte circulation is observed, relative to intact animals. This, in turn, can lead to stagnation in the circulatory system of the large intestine, then local violations of the rheological properties of the blood,

Impact Factor:

ISRA (India)	= 4.971	SIS (USA)	= 0.912	ICV (Poland)	= 6.630
ISI (Dubai, UAE)	= 0.829	PIHHI (Russia)	= 0.126	PIF (India)	= 1.940
GIF (Australia)	= 0.564	ESJI (KZ)	= 8.716	IBI (India)	= 4.260
JIF	= 1.500	SJIF (Morocco)	= 5.667	OAJI (USA)	= 0.350

that is, contribute to the activation of inflammatory processes. Apparently, this is the cause of intestinal complications in the postoperative period with UCV.

Lymphotropic therapy improves the rheological properties of blood and lymph, enhances lymph outflow, normalizes microhemolymphocirculation, completely removes edematous fluid and toxic metabolites from tissues, and activates the neutralizing and immunological activity of the lymph nodes of the abdominal cavity. Thus, this method prevents unwanted complications that occur in the postoperative period from the intestine. In addition, it should be noted that with the lymphotropic administration of antibiotics, the occurrence of allergic reactions is not observed.

V. Conclusion

1. On the experimental model of ulcerative colitis, a violation of the processes of lymphatic circulation in the intestinal wall and its mesentery was established.

2. Impaired lymph circulation in the walls of the intestine and its mesentery contributes to the occurrence of complications from the intestine, especially in the postoperative period.

3. The use of lymphotropic therapy in the complex treatment of UC in patients helps eliminate impaired lymphatic circulation processes, due to which intestinal complications in the postoperative period are significantly reduced.

References:

1. Akhrieva, H.M., Tertychny, A.S., Maev, I.V., & Zairatyants, O.V. (2017). Classification and morphological diagnosis of ulcerative colitis and Crohn's disease. *Clinical and experimental morphology*, Number 3, pp. 4-15.
2. Grigoriev, G.A., & Meshalkina, N.Yu. (2007). *Crohn's disease*. (p.84). Moscow: Medicine.
3. Denisov, N.L., Ivanov, A.V., Ivanova, N.V. (2013). Clinical, immunological, genetic and microbiological aspects of the pathogenesis of irritable bowel syndrome and ulcerative colitis. *Bulletin of the National Medical and Surgical Center. N.I. Pirogov.*, V.8, No. 3, pp. 94-98.
4. (2004). Maseevich Index: A new approach to assessing the clinical and endoscopic activity of ulcerative colitis. AsaninYu.Yu. et al. *Gastroenterology*. S. Petersburg., No. 1, pp. 14-16.
5. Osikov, M.V. (2016). Experimental modeling of Crohn's disease and ulcerative colitis. *Journal Modern problems of science and education*, No. 4.
6. Sekacheva, M.I. (2003). Modern aspects of the treatment of ulcerative colitis: evidence-based medicine. *ConsiliumMedicum* [Electronic resource], V. 5, No. 10, Access mode Retrieved from http://www.consiliummedicum.com/media/consilium/03_10c/18shtmi.
7. Stavtsev, D.S., Astrelina, T.A., Knyazev, O.V., & Pukhlikova, T.V. (2014). The value of immunogenetic HLA markers in the development of ulcerative colitis. *Clinical laboratory diagnostics*, No 6, pp. 22-26.
8. Suvorova, G.N., et al. (2018). Histological picture and microbial landscape with ulcerative colitis. *Bulletin of new medical technology*, No4, pp. 170-175.
9. Tkachev, A.V., Mkrtychyan, L.S., Nikitina, K.E., & Volynskaya, E.I. (2012). Inflammatory bowel disease: at the crossroads of problems. *Practical medicine*, No. 3, pp. 17-22.
10. Caliph, I.L. (n.d.). Surgical treatment and biological therapy for ulcerative colitis.
11. Zimmerman, Ya.S., Zimmerman, I.Ya., & Tretyakova, Yu.I. (2013). Ulcerative colitis and Crohn's disease: current views. Part 1. Definition, terminology, prevalence, etiology and pathogenesis, clinic, complications, classification. *Clinical Medicine*, No. 11, pp. 27-33.
12. Egamov, Yu.S., Ruziev, A.E., Khaidarov, S.A. (2019). Endomesentericlymphotropic therapy as a method of preventing complications in the complex treatment of ulcerative colitis in the postoperative period. *Journal New day in medicine*, No. 3, pp. 299-303.
13. Fenoglio-Preiser, C.M., Noffsinger, A.E., & Stemmermann, G.N. (2008). *Gastrointestinal Pathology: An Atlas and Text*. 3rd ed. Lippincott Williams & Wilkins, p.1312.
14. Marinov, V. (2015). Investigation of two models of trinitrobenzenesulfonicacidnduced colitis in rats. *Trakia Journal of Sciences*, Vol. 13, Suppl. 2, pp. 49-54.
15. Szalai, Z. (2014). Novel features of the rat model of inflammatory bowel disease based on 2,4,6-trinitrobenzenesulfonic acid-induced acute colitis. *ActaBiologicaSzegediensis*, Vol. 58, pp. 127-132.