



doi:10.4103/2221-6189.276080

jadweb.org

## Extensively drug-resistant *Klebsiella pneumoniae* pneumonia: A case report

Saurabh Karmakar<sup>1</sup>, Somnath Bhattacharya<sup>1</sup>, Shilpi Karmakar<sup>2</sup>, Deependra Kumar Rai<sup>1</sup>

<sup>1</sup>Department of Pulmonary Medicine, All India Institute of Medical Sciences, Patna, India

<sup>2</sup>Department of Plastic Surgery, King George's Medical University, Lucknow, India

### ABSTRACT

**Rationale:** Extensively drug resistant *Klebsiella pneumoniae* is defined as resistant to least one antimicrobial agent in all but two or lesser antimicrobial categories.

**Patient concerns:** A 58-year-old diabetic male was admitted with bilateral pneumonia. Sputum culture grew *Klebsiella pneumoniae* which was sensitive to only colistin on culture.

**Diagnosis:** Acute hypoxemic respiratory failure causes bilateral pneumonia (community acquired).

**Intervention:** The combination therapy of oral faropenem and intravenous colistin for treatment.

**Outcome:** The patient recovered fully and is doing well on follow-up.

**Lesson:** Emerging antibiotic-resistant and hypervirulent strains of *Klebsiella pneumoniae* should drive further studies on novel antibiotic combinations for extensively drug-resistant *Klebsiella pneumoniae*.

**KEYWORDS:** *Klebsiella pneumoniae*; XDR; Faropenem; Pneumonia

### 1. Introduction

Pneumonia is a serious public health concern and a major cause of mortality and morbidity worldwide. Pneumonia can be caused by a myriad of microorganisms like bacteria (Gram-positive, Gram-negative and atypical), viruses and fungi. Gram-negative bacteria that cause pneumonia include Enterobacteriaceae family, *Pseudomonas aeruginosa*, *Acinetobacter* species and *Hemophilus influenzae*. *Klebsiella pneumoniae* (*K. pneumoniae*) is a Gram-negative, encapsulated, non-motile bacterium of Enterobacteriaceae family. Although *K. pneumoniae* can cause both community-acquired and hospital-acquired pneumonia, community-acquired pneumonia is very uncommon[1].

Extensively drug-resistant strains of *K. pneumoniae* gravely threaten patients' health and poses tremendous challenges to the

clinician regarding therapeutic options. Although combination of antibiotic regimens exists as the last resort treatment for extensively drug-resistant *Klebsiella pneumoniae* (XDR-KP) infections, we had to use a novel antibiotic combination due to prohibitive costs of the existing combinations. Our combination still needs to go through clinical trials and additional research before it can become a commonly used treatment.

### 2. Case report

Informed consent was obtained from the patient's relatives and the Institutional Ethics Committee prior to reporting this case. A 58-year-old male patient was admitted to the Emergency Department with complaints of high fever; cough, initially dry, then associated with mucopurulent expectoration of thick consistency; chest pain and dyspnea (increased to grade IV modified Medical Research Council on the day of admission) lasting for 8 d.

The patient was an old case of allergic rhinitis with bronchial asthma since adolescence. The symptoms were well controlled by metered-dose inhalers (taken daily) and intranasal corticosteroids (taken intermittently). The patient also had a 10-years-history type II diabetes mellitus with the treatment of insulin glargine until admission.

<sup>✉</sup>To whom correspondence may be addressed. E-mail: doc\_next\_door@yahoo.com

This is an open access journal, and articles are distributed under the terms of the Creative Commons Attribution-NonCommercial-ShareAlike 4.0 License, which allows others to remix, tweak, and build upon the work non-commercially, as long as appropriate credit is given and the new creations are licensed under the identical terms.

**For reprints contact:** reprints@medknow.com

©2020 Journal of Acute Disease Produced by Wolters Kluwer- Medknow. All rights reserved.

**How to cite this article:** Karmakar S, Bhattacharya S, Karmakar S, Rai DK. Extensively drug-resistant *Klebsiella pneumoniae* pneumonia: A case report. J Acute Dis 2020; 9(1): 40-42.

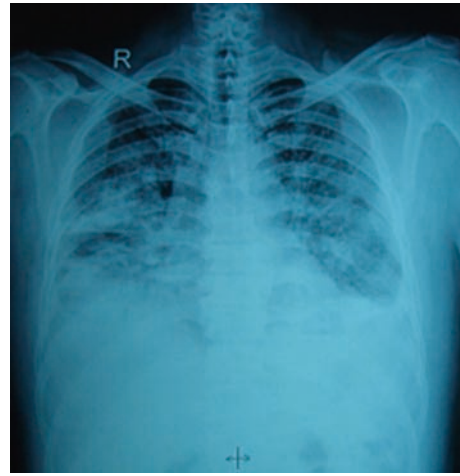
Article history: Received 13 October 2019; Revision 31 December 2019; Accepted 11 January 2020; Available online 24 January 2020

He had attended a local practitioner for his illness and was prescribed tab amoxicillin clavulanate 625 mg thrice daily, expectorant bronchodilator syrup and anti-allergic (montelukast levocetrizine). The sputum sample was sent for gram smear and culture sensitivity analysis for bacterial organisms. The patient was referred to our center when sputum culture sensitivity report arrived and with worsening symptoms.

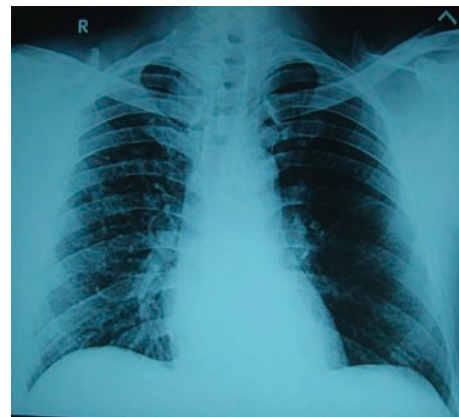
On general examination, the body temperature was 102°F, blood pressure was 148/90 mm Hg, pulse rate was 108 beats/min, respiratory rate was 28/min and oxygen saturation was 96% on 5 liters oxygen by face mask. Systemic examination revealed bilateral crepts, air entry was diminished and bronchial breath sounds were heard. The rest systems were within normal limits. Laboratory values showed a total leucocytes count of 19 600 cells/cu mm (normal range: 4 500-11 000) and differential leukocyte count of 88% polymorphs, 6% lymphocytes, 2% monocytes and 4% eosinophils (normal range: polymorphs 40%-80%, lymphocytes 20%-40%, monocytes 2%-10%, eosinophils 1%-6%). The patient had random blood sugar of 330 mg/dL (normal range: 79-140 mg/dL) and HbA1C: 8.5% (4%-5.6%). His liver function test and kidney function test were within normal limits. ECG revealed sinus tachycardia. Arterial blood gas on 5 L O<sub>2</sub> was 7.42/68/34/22/94% (normal range: 7.35-7.45/75-100/35-45/22-26/95%-100%). Serum procalcitonin was 6 µg/L (<0.15).

Sputum smear and culture for pyogenic organisms showed significant growth of *K. pneumonia* that is sensitive to colistin and resistant to cefepime, cefoperazone sulbactam, cefotaxime, ceftazidime, ciprofloxacin, cotrimoxazole, gentamicin, imipenam, meropenem and piperacillin tazobactam. A chest radiograph at admission was suggestive of bilateral consolidation, more on the right with blunting of costophrenic angles (Figure 1). We made a diagnosis of acute hypoxemic respiratory failure cause due to community-acquired pneumonia caused by XDR-KP.

The patient was admitted to the intensive care unit since p/F ratio was 165. We initiated the treatment with injection colistin 5 mg/kg body weight given in 4 divided doses intravenously. We had advised the injection of ertapenem with doripenem, but the patient refused due to the high cost. So we were compelled to start tablet faropenem 300 mg t.i.d. with mucolytics, bronchodilators, expectorants and other supportive treatment. Oxygen was given through face mask at 4-5 L/min, and was titrated to saturation more than 95%. High blood sugars were controlled with multiple subcutaneous insulins. The patient's fever spikes and hypoxia was reduced 3 d later. The patient was discharged after day 7 in an afebrile state with stable hemodynamics and a room air oxygen saturation of 95%. On follow-up visit after 10 d of oral faropenem, the patient was symptomatically better and antibiotic was stopped. A chest radiograph after 21 d showed significant resolution of pneumonia (Figure 2). The patient remains healthy and asymptomatic and is on regular follow-up with physician for diabetes.



**Figure 1.** Posteroanterior chest ray PA shows bilateral pneumonia.



**Figure 2.** Posteroanterior chest ray PA after three weeks shows complete resolution of pneumonia.

### 3. Discussion

Pneumonia is the leading infectious cause of death and the fourth overall cause of mortality in the elderly worldwide[2]. India is a country that is experiencing rapid socioeconomic progress, cultural transition and urbanization and also carries a considerable share of the global diabetes burden also. Diabetes is associated with a higher risk of death following community-acquired pneumonia[3].

*Klebsiella* colonizes human skin, oropharynx and gastrointestinal tract and causes urinary tract infection, intraabdominal infections and pneumonia. *Klebsiella* species were the third most common cause of central line-associated bloodstream infection, catheter-associated urinary tract infection, ventilator-associated pneumonia, and surgical site infection reported to the National Healthcare Safety Network of the Centers for Disease Control and Prevention between 2011 and 2014. *Klebsiella* as a causative agent for community-acquired pneumonia, has a varied prevalence across the world, which can be attributed to the differences in virulence of strains, host defenses and pattern of self-medication and antibiotic consumption in community[4].

The Centers for Disease Control and Prevention defines

multidrug-resistant as acquired non-susceptibility to at least one agent in three or more antimicrobial categories and XDR as non-susceptibility to at least one agent in all but two or lesser antimicrobial categories (*i.e.* bacterial isolates remain susceptible to only one or two categories).

*K. pneumoniae* can produce extended beta-lactamase rendering third-generation cephalosporins ineffective and making carbapenems the only viable option. However, the first case of *K. pneumoniae* expressing carbapenemase was in North Carolina in 1996, and this type of carbapenemase is called *K. pneumoniae* carbapenemase. Additional, other types, such as MBL, NDM-1, IMP, and VIM were discovered later[5]. *K. pneumoniae* comprised 80% of carbapenem-resistant Enterobacteriaceae of the 9 000 infections reported to the National Healthcare Safety Network of the Centers for Disease Control and Prevention in 2013[6]. The rates of carbapenem resistance among *K. pneumoniae* escalated from 0.7% in 2006 to 10% in 2013[7]. In India, carbapenem resistance is mostly due to the NDM and OXA enzymes while in Europe *K. pneumoniae* carbapenemase is the major carbapenemase encoded by the bacterial[8].

The availability of alternative, effective antimicrobial agents is limited. Therapeutic options for carbapenem-resistant Enterobacteriaceae include antibiotics from the polymyxin class, tigecycline, fosfomycin, aminoglycosides or dual carbapenem therapy (ertapenem and doripenem). *In vitro* studies have shown the synergy of colistin with sulbactam, fosfomycin, tigecycline, aminoglycosides or a carbapenem[9].

Faropenem has broad antimicrobial activity. It is active against aerobic Gram-positive, Gram-negative, and anaerobic bacteria, and is also resistant to TEM-, SHV- and CTX-M-type extended beta-lactamases[10]. Faropenem is extremely stable against a number of beta-lactamases *in vitro* and it has good clinical and antimicrobial efficacies against respiratory tract infections, urinary tract infections and skin infections for which it is approved indication in Japan.

*K. pneumoniae* isolated in our patient was non-susceptible to all antimicrobial categories except colistin, thus rendering it as XDR. In our clinical setting, due to patient unwillingness for dual carbapenem therapy, we tested the efficacy of faropenem with colistin as antibiotic salvage therapy. Faropenem provided an oral, cheaper alternative option as well as follow-up antibiotic for treatment. The combination proved to be effective. Further *in vivo* and *in vitro* studies to test the efficacy of this antibiotic combination need to be conducted to validate this approach.

*K. pneumoniae* carries a grim prognosis and mortality of 30%-50% even with the optimal antibiotic therapy. The prognosis is worse in diabetics, the elderly and those who are immunocompromised. For those who survive, they often have residual impaired lung function, and recovery took months.

XDR-KP infection leading to pneumonia, urinary tract infections and bloodstream infections have been closely related to increased morbidity, mortality, long hospital stay, and high healthcare costs. Antimicrobial drug resistance in *K. pneumoniae* raises

serious therapeutic challenges. The economic burden of treating pneumonia and its complications is considerable. The challenge posed by the recent emergence of XDR-KP can be possibly addressed by novel therapeutic approaches along with enforcement of strict infection control practices and prudent and optimal use of antibiotics that are still effective.

## Conflict of interest statement

The authors report no conflict of interest.

## Authors' contribution

S.K. is responsible for the concept, designing, intellectual content and manuscript preparation. S.B., S.K. and D.K.R. are responsible for manuscript editing and review.

## References

- [1] Prince SE, Dominguez KA, Cunha BA, Klein NC. *Klebsiella pneumoniae* pneumonia. *Heart Lung* 1997; **26**: 413-417.
- [2] El-Solh AA, Sikka P, Ramadan F, Davies J. Etiology of severe pneumonia in the very elderly. *Am J Respir Crit Care Med* 2001; **163**: 645-651.
- [3] Yende S, van der Poll T, Lee M, Huang DT, Newman AB, Kong L, and et al. The influence of pre-existing diabetes mellitus on the host immune response and outcome of pneumonia: analysis of two multicentre cohort studies. *Thorax* 2010; **65**: 870-877.
- [4] Rammaert B, Goyet S, Beaute J, Hem S, Te V, Try PL, et al. *Klebsiella pneumoniae* related community-acquired acute lower respiratory infections in Cambodia: clinical characteristics and treatment. *BMC Infect Dis* 2012; **12**: 3.
- [5] Yigit H, Queenan AM, Anderson GJ, Domenech-Sanchez A, Biddle JW, Steward CD, et al. Novel carbapenem-hydrolyzing beta-lactamase, KPC-1, from a carbapenem-resistant strain of *Klebsiella pneumoniae*. *Antimicrob Agents Chemother* 2001; **45**: 1151-1161.
- [6] Martin RM, Bachman MA. Colonization, infection, and the accessory genome of *Klebsiella pneumoniae*. *Front Cell Infect Microbiol* 2018; **8**: 4.
- [7] Hu Y, Ping Y, Li L, Xu H, Yan X, Dai H. A retrospective study of risk factors for carbapenem-resistant *Klebsiella pneumoniae* acquisition among ICU patients. *J Infect Dev Countries* 2016; **10**: 208-213.
- [8] Shankar C, Nabarro LE, Anandan S, Ravi R, Babu P, Munusamy E. Extremely high mortality rates in patients with carbapenem-resistant, hypermucoviscous *Klebsiella pneumoniae* blood stream infections. *J Assoc Physicians India* 2018; **66**: 13-16.
- [9] Cheng IL, Chen YH, Lai CC, Tang HJ. Intravenous Colistin monotherapy versus combination therapy against carbapenem-resistant Gram-negative bacteria infections: Meta-analysis of randomized controlled trials. *J Clin Med* 2018; **7**: 208.
- [10] Gettig JP, Crank CW, Philbrick AH. Faropenem medoxomil. *Ann Pharmacother* 2008; **42**: 80-90.