

Impact Factor:

ISRA (India) = 1.344	SIS (USA) = 0.912	ICV (Poland) = 6.630
ISI (Dubai, UAE) = 0.829	PIHHI (Russia) = 0.156	PIF (India) = 1.940
GIF (Australia) = 0.564	ESJI (KZ) = 4.102	IBI (India) = 4.260
JIF = 1.500	SJIF (Morocco) = 2.031	

SOI: [1.1/TAS](#) DOI: [10.15863/TAS](#)

International Scientific Journal Theoretical & Applied Science

p-ISSN: 2308-4944 (print) e-ISSN: 2409-0085 (online)

Year: 2018 Issue: 09 Volume: 65

Published: 24.09.2018 <http://T-Science.org>

Hafiz Muhammad Ayyaz Afzal
Post graduate Resident in Nishter Hospital Multan,
Pakistan.
doctorayyaz9@gmail.com

Verda Zulfiqar
Doctor in Jinnah Hospital Lahore, Pakistan
shahryar095@gmail.com

Sidra Kayani
Doctor in Holy Family Hospital Rawalpindi,
Pakistan.
sidkayani1@gmail.com

SECTION 20. Medicine

INCIDENCE AND PRESENTATION OF TUBERCULOUS MENINGITIS

Abstract: Objective: This study was conducted to determine incidence and presentation of tuberculous meningitis in male vs female populations.

Design and Duration: This is a cross sectional study of descriptive type. This comprises on 7 months duration from January 2018 to July 2018.

Setting: This study was conducted in Nishter Hospital Multan Pakistan.

Patients and Methods: All patients presented in emergency department or outpatient door of study institution with signs and symptoms of meningitis were evaluated and out of them patients with tuberculous meningitis were selected for study. These cases were belonging to both male and female populations and having different age groups. Proper history was taken, thorough physical examination was done, CT scan was done in all cases and where CT scan was not conclusive, MRI was done. Lumbar Puncture was done and 5 ml CSF taken from all cases and sent for examination to the hospital laboratory. All necessary investigations were done such as CBC with ESR, RFTs, LFTs. A performa was designed containing relevant questions such as age, presenting complaints, durations of disease, family history of tuberculosis or in the patient himself and any associated disease etc. Those cases having any other chronic disease with TBM were not included in the study. Data collected was analyzed using statistical software and Microsoft office version 2017. Results were calculated as frequencies and percentages. Tables and graphs were used to express the results.

Results: There were total 116 cases diagnosed with tuberculous meningitis presenting during study duration. 55.2% were female and 44.8% were male patients. Range of their ages was 15-73 years with mean age of 45 ± 17.8 years. There were 17.2% female and 26.9% male cases between 15-25 years, 20.3% female and 30.8% male cases between 26-35 years, 23.4% female and 17.3% male between 36-45 years, 15.6% female and 11.5% male between 46-55 years and 10.9% female and 5.8% male cases were above 65 years. Presenting complaints were fever in 92.2% females and 88.5% male cases, headache was present in 96.8% female and 92.3% male cases, signs of meningism were present in 79.7% female and 71.2% male cases and 18.7% female and 9.6% male cases presented in coma. Findings on CT scan were hydrocephalus in 67.2% cases, edema in 36.2% and infarction in 11.2% cases. On MRI brain hydrocephalus was seen in 81(69.8%) cases, tuberculomas in 86(74%) and infarcts in 14(12.1%) were seen. Solitary tuberculomas were present in 22% cases and multiple in 64% cases.

Conclusion: Tuberculous meningitis is a common form of meningitis occurring in both genders but frequently occurs in females. CT scan and MRI are very helpful in diagnosing TBM. Most common presenting symptoms were fever, headache and meningism while coma may be present in few cases.

Key words: Tuberculous meningitis, Meningism, presentation of meningitis.

Language: English

Citation: Ayyaz Afzal HM, Zulfiqar V, Kayani S (2018) INCIDENCE AND PRESENTATION OF TUBERCULOUS MENINGITIS. ISJ Theoretical & Applied Science, 09 (65): 134-138.

Soi: <http://s-o-i.org/1.1/TAS-09-65-21> **Doi:**  <https://dx.doi.org/10.15863/TAS.2018.09.65.21>

INTRODUCTION

Meningitis is a very common neurological disease in which inflammation of leptomeningis occur.¹ This leads to hydrocephalus of non obstructing type. Intracranial pressure is raised causing headache and cranial nerves palsy, decreased in vision etc. Meningitis may be due to viral or

bacterial infection and trauma.^{2,3} Mycobacterium tuberculosis is a common cause of meningitis. It is common in people having previously tuberculous infection or positive family history of pulmonary tuberculosis. There are various investigations for diagnosing TBM such as CT scan brain, MRI brain and CSF culture and examination. In most of the



Impact Factor:

ISRA (India) = 1.344	SIS (USA) = 0.912	ICV (Poland) = 6.630
ISI (Dubai, UAE) = 0.829	PIHII (Russia) = 0.156	PIF (India) = 1.940
GIF (Australia) = 0.564	ESJI (KZ) = 4.102	IBI (India) = 4.260
JIF = 1.500	SJIF (Morocco) = 2.031	

cases mycobacterium is isolated on CSF culture. Suitable antibiotic treatment is very effective against it. Initial management includes airway management, maintaining circulation, assessing GCS and management of fever and broad spectrum antibiotic therapy until unless culture sensitivity is obtained.⁴⁻⁶ All patients presented in emergency department or outpatient door of study institution with signs and symptoms of meningitis were evaluated and out of them patients with tuberculous meningitis were selected for study. These cases were belonging to both male and female populations and having different age groups. Proper history was taken, thorough physical examination was done, CT scan was done in all cases and where CT scan was not conclusive, MRI was done. Lumbar Puncture was done and 5 ml CSF taken from all cases and sent for examination to the hospital laboratory. In CT scan features of TBM reveal clearly such as hydrocephalus, presence of tuberculomas solitary or multiple in number, location of tubercles either above tentorium or below it and brain edema etc.^{7,8} That cases in which CT scan is not conclusive, MRI brain is done more superior to CT scan showing fine details and findings in brain. Normal examination of CSF shows glucose less than 60 mg/dl and protein content more than 45 mg/dl. CSF examination takes much time and in it may be negative in more than 50% cases so it is not much sensitive for TBM. MRI is investigation of choice showing calcifications, inflammation of meningis, tuberculomas and basal meningitis.

Patients and Methods

This is a cross sectional study done in a teaching hospital Nishtar Hospital located in Multan, a city of Pakistan. This study was completed in seven months duration. All patients presented in emergency department or outpatient door of study institution with signs and symptoms of meningitis were evaluated and out of them patients with tuberculous meningitis were selected for study. These cases were belonging to both male and female populations and having different age groups. Proper history was taken, thorough physical examination was done, CT scan was done in all cases and where CT scan was not conclusive, MRI was done. Lumbar Puncture was done and 5 ml CSF taken from all cases and sent for examination to the hospital laboratory. All necessary investigations were done such as CBC with ESR, RFTs, LFTs. A performa was designed containing relevant questions such as age, presenting complaints, durations of disease, family history of tuberculosis or in the patient himself and any

associated disease etc. Those cases having any other chronic disease with TBM were not included in the study. Data collected was analyzed using statistical software and Microsoft office version 2017. Results were calculated as frequencies and percentages. Tables and graphs were used to express the results. An inclusion and exclusion criteria was formed according to which patients having meningitis due to infection with mycobacterium tuberculosis either isolated on CSF examination or findings confirmed on CT scan and MRI. Patients with chronic diseases like CLD, IHD, or other pathologies of brain tumors, hydrocephalus due to other diseases or brain abscess were not included in this study. Proper written consent was taken from all the patients in study group and privacy of patients was maintained. Consent was also taken from the ethical committee of the hospital for conducting study.

Results

All patients presented in emergency department or outpatient door of study institution with signs and symptoms of meningitis were evaluated and out of them patients with tuberculous meningitis were selected for study. These cases were belonging to both male and female populations and having different age groups. Proper history was taken, thorough physical examination was done, CT scan was done in all cases and where CT scan was not conclusive, MRI was done. There were total 116 cases diagnosed with tuberculous meningitis presenting during study duration. 64(55.2%) were female and 52(44.8%) were male patients. Range of their ages was 15-73 years with mean age of 45±17.8 years. There were 11(17.2%) female and 14(26.9%) male cases between 15-25 years, 13(20.3%) female and 16(30.8%) male cases between 26-35 years, 15(23.4%) female and 9(17.3%) male between 36-45 years, 10(15.6%) female and 6(11.5%) male between 46-55 years and 7(10.9%) female and 3(5.8%) male cases were above 65 years. Presenting complaints were fever in 59(92.2%) females and 46(88.5%) male cases, headache was present in 62(96.8%) female and 48(92.3%) male cases, signs of meningism were present in 51(79.7%) female and 37(71.2%) male cases and 12(18.7%) female and 5(9.6%) male cases presented in coma. Findings on CT scan were hydrocephalus in 78(67.2%) cases, edema in 42(36.2%) and infarction in 13(11.2%) cases. On MRI brain hydrocephalus was seen in 81(69.8%) cases, tuberculomas in 86(74%) and infarcts in 14(12.1%) were seen. Solitary tuberculomas were present in 22% cases and multiple in 64% cases.



Impact Factor:

ISRA (India) = 1.344	SIS (USA) = 0.912	ICV (Poland) = 6.630
ISI (Dubai, UAE) = 0.829	PIHHI (Russia) = 0.156	PIF (India) = 1.940
GIF (Australia) = 0.564	ESJI (KZ) = 4.102	IBI (India) = 4.260
JIF = 1.500	SJIF (Morocco) = 2.031	

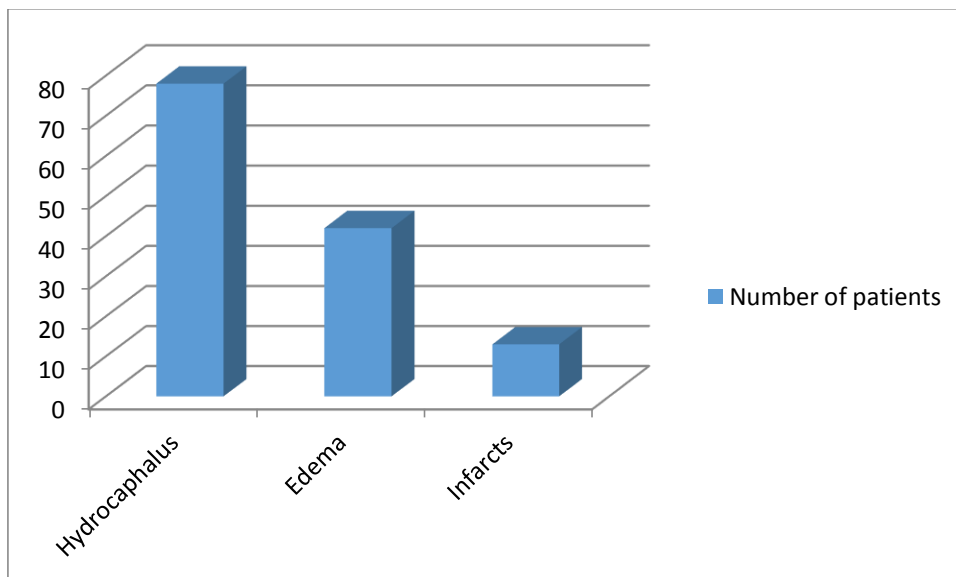


Figure-1 CT scan brain findings in TBM patients (n=116)

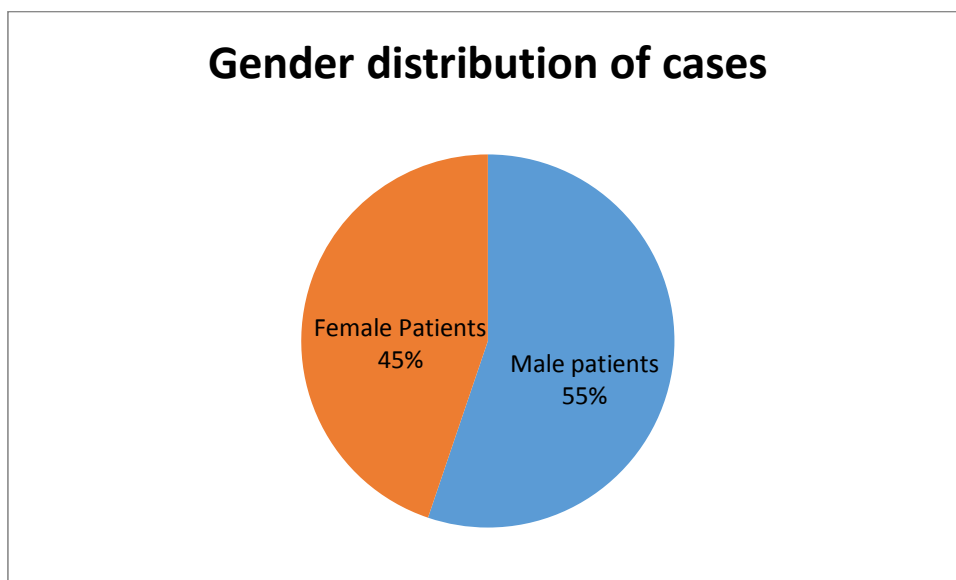


Table-1

Age distribution of cases among male and female patients

Age groups (years)	Female patients		Male Patients	
	N	%	N	%
15-25	11	17.2	14	26.9
26-35	13	20.3	16	30.8
36-45	15	23.4	9	17.3
46-55	10	15.6	6	11.5
56-65	8	12.5	4	7.7
Above 65	7	10.9	3	5.8
Total	64		52	

Impact Factor:

ISRA (India) = 1.344	SIS (USA) = 0.912	ICV (Poland) = 6.630
ISI (Dubai, UAE) = 0.829	PIHHI (Russia) = 0.156	PIF (India) = 1.940
GIF (Australia) = 0.564	ESJI (KZ) = 4.102	IBI (India) = 4.260
JIF = 1.500	SJIF (Morocco) = 2.031	

Table-2**Frequency of presenting complaints in male and female cases with TBM**

Presenting complaints	Female Patients		Male Patients	
	N	%	N	%
Fever	59	92.2	46	88.5
Headache	62	96.8	48	92.3
Meningism	51	79.7	37	71.2
Coma	12	18.7	5	9.6

DISCUSSION

Meningitis is inflammation of meningism mostly due to infection by virus or bacteria but may also be caused by trauma.^{9,10} In bacterial causes mycobacterium tuberculosis is very common causing tuberculous meningitis. In this disease cranial nerve palsy occurs frequently and involving facial nerve and oculomotor nerve commonly.¹¹ These cases present with signs and symptoms related to CNS. Meningitis is a very common neurological disease in which inflammation of leptomeningis occur. This leads to hydrocephalus of non obstructing type. Intracranial pressure is raised causing headache and cranial nerves palsy, decreased in vision etc.¹² Meningitis may be due to viral or bacterial infection and trauma. Mycobacterium tuberculosis is a common cause of meningitis. It is common in people having previously tuberculous infection or positive family history of pulmonary tuberculosis.¹³ In our study findings on CT scan were hydrocephalus in 78(67.2%) cases, edema in 42(36.2%) and infarction in 13(11.2%) cases. On MRI brain hydrocephalus was seen in 81(69.8%) cases, tuberculomas in 86(74%) and infarcts in 14(12.1%) were seen. Solitary tuberculomas were present in 22% cases and multiple in 64% cases. There are various investigations for diagnosing TBM such as CT scan brain, MRI brain and CSF culture and examination.¹⁴ In most of the cases mycobacterium is isolated on CSF culture. Suitable antibiotic treatment is very effective against it. Initial management includes airway management, maintaining circulation assessing GCS and management of fever and broad spectrum antibiotic therapy until unless culture sensitivity is obtained. According to different studies frequency of hydrocephalus was 11-75% in patients with tuberculous meningitis.¹⁵ This is a cross sectional study done in a teaching hospital Nishtar Hospital located in Multan, a city of Pakistan. This study was completed in seven months duration. All patients presented in emergency department or

outpatient door of study institution with signs and symptoms of meningitis were evaluated and out of them patients with tuberculous meningitis were selected for study.¹⁶ These cases were belonging to both male and female populations and having different age groups. Proper history was taken, thorough physical examination was done, CT scan was done in all cases and where CT scan was not conclusive, MRI was done. Lumber Puncture was done and 5 ml CSF taken from all cases and sent for examination to the hospital laboratory. There were total 116 cases diagnosed with tuberculous meningitis presenting during study duration. 64(55.2%) were female and 52(44.8%) were male patients. Range of their ages was 15-73 years with mean age of 45±17.8 years. In CT scan features of TBM reveal clearly such as hydrocephalus, presence of tuberculomas solitary or multiple in number, location of tubercles either above tentorium or below it and brain edema etc. That cases in which CT scan is not conclusive, MRI brain is done more superior to CT scan showing fine details and findings in brain. Early diagnosis of patients and prompt treatment can reduce morbidity and mortality associated with this disease.¹⁷ Definite treatment is to reduce intracranial pressure and complete course of ATT drugs.

Conclusion

Among various causes of meningitis bacterial cause was found common in this study. Tuberculous meningitis is a common form of meningitis occurring in both genders but frequently occurs in females. CT scan and MRI are very helpful in diagnosing TBM. Lumber puncture is not much sensitive for this disease as it is negative in most of cases having disease. Most common presenting symptoms were fever, headache and meningism while coma may be present in few cases. Main line of treatment is to manage vitals and to decrease intracranial pressure.

Impact Factor:

ISRA (India) = 1.344	SIS (USA) = 0.912	ICV (Poland) = 6.630
ISI (Dubai, UAE) = 0.829	PIHHI (Russia) = 0.156	PIF (India) = 1.940
GIF (Australia) = 0.564	ESJI (KZ) = 4.102	IBI (India) = 4.260
JIF = 1.500	SJIF (Morocco) = 2.031	

References:

1. Leonard JM, Des Prez RM. (1990) Tuberculous meningitis. *Infect Dis Clin North Am* 1990; 4: 769-87.
2. Andronikou S, Wieselthaler N, Smith B, Douis H, Fieggen AG, van Toorn R, et al. (2005) Value of early follow-up CT in paediatric tuberculous meningitis. *Pediatr Radiol* 2005; 35: 1092-9.
3. Sobri M, Merican JS, Nordiyana M, Valarmathi S, Al-Edrus SA. (2006) Neuroimaging features of tuberculous meningitis. *Med J Malaysia* 2006; 61: 36-40.
4. Sirajus S, Khalid M, Naqvi IH, Akhter ST, Abbasi A. (2013) Clinical course, complications and predictors of mortality in patients with tuberculous meningitis an experience of fifty two cases at Civil Hospital Karachi, Pakistan *J Pak Med Assoc* 63, may 2013.
5. Etlik Ö, Evirgen Ö, Bay A, Yilmaz N, Temizöz O, Irmak H, et al. (2004) Radiologic and clinical findings in tuberculous meningitis. *Eur J Gen Med* 2004.
6. Cherian A, Thomas SV. (2011) Central nervous system tuberculosis. *Afr Health Sci* 2011; 11: 116-27.
7. George EL, Iype T, Cherian A, Chandy S, Kumar A, Balakrishnan A, Vijayakumar K. (2012) Predictors of mortality in patients with meningeal tuberculosis. *Neurol India* 2012; 60: 18-22.
8. Bernaerts A, Vanhoenacker FM, Parizel PM, et al. (2003) Tuberculosis of the central nervous system: overview of neuroradiological findings. *Eur. Radiol.* 13(8), 1876–1890 (2003).
9. Wasay M, Kheleani BA, Moolani MK, Zaheer J, Pui M, Hasan S, et al. (2003) Brain CT and MRI findings in 100 consecutive patients with intracranial tuberculoma. *J Neuroimaging* 2003; 13: 240-7.
10. Sonmez G, Ozturk E, Sildiroglu HO, Mutlu H, Cuce F, Senol MG, et al. (2008) MRI findings of intracranial tuberculomas. *Clin Imaging* 2008; 32: 88-92.
11. Offenbacher H, Fazekas F, Schmidt R, Kleinert R, Payer P, Kleinert G, et al. (1991) MRI in tuberculous meningoencephalitis: report of four cases and review of the neuroimaging literature. *J Neurol* 1991; 238: 340-4.
12. Tarakad S, Ramachandran, Frederick M Vincent Sr, Tuberculous meningitis [online] (2011) [cited 10th April 2014]. Available from (<http://emedicine.medscape.com/article/1166190-overview>).
13. Kent SJ, Crowe SM, Yung A, Lucas CR, Mijch AM. (1993) Tuberculous meningitis: a 30-year review. *Clin Infect Dis* 1993; 17: 987-94.
14. Qureshi HU, Merwat SN, Nawaz SA, Rana AA, Malik A, Mahmud MK, et al. (2002) Predictors of inpatient mortality in 190 adult patients with tuberculous meningitis. *J Pak Med Assoc* 2002; 52: 159-63.
15. Thwaites GE, Tran TH. (2005) Tuberculous meningitis: many questions, too few answers. *Lancet Neurol.* 4(3), 160–170 (2005).
16. Rich AR, McCordock HA. (1933) The pathogenesis of tuberculous meningitis. *Bull. John Hopkins Hosp.* 52, 2–37 (1933).
17. Fazel P A, Makki KU, Haroon H, Soomro I B, Afzal U. (2006) Clinical spectrum and outcome of patients with tuberculous meningitis. *Med Channel* 2006; 12: 21-3.

