



doi: 10.4103/2221-6189.259115

jadweb.org

# Necrotizing fasciitis of lower extremity due to diverticulitis perforation: a case report

Halil Dogan<sup>✉</sup>, Bilginar Kovanci

Department of Emergency Medicine, University of Health Sciences Bakirkoy Dr. Sadi Konuk Training and Research Hospital, Istanbul, Turkey

## ARTICLE INFO

## Article history:

Received 26 December 2018

Revision 3 April 2019

Accepted 15 May 2019

Available online 27 May 2019

## Keywords:

Necrotizing fasciitis

Diverticulitis

Perforation

Thigh infection

Steroid use

## ABSTRACT

**Rationale:** Necrotizing fasciitis is an aggressive infection of subcutaneous tissues, which tends to spread rapidly through the fascial planes. Colonic diverticulosis is a common disease in advanced age, although it rarely causes a lethal necrotizing soft-tissue infection.

**Patient concerns:** A 58-year-old woman complained of left leg pain for 15 d without abdominal pain.

**Diagnosis:** Diverticulitis perforation presented as necrotizing fasciitis of the left thigh.

**Interventions:** Extensive debridement.

**Outcomes:** The patient died due to sepsis-induced multiple organ failure and severe metabolic acidosis.

**Lessons:** Clinicians should be aware of presentations of diverticulitis in patients who have a soft-tissue infection in lower extremity even though patients may not have had a history of diverticulosis or abdominal pain.

## 1. Introduction

Necrotizing fasciitis (NF) is an aggressive infection of subcutaneous tissues that spread rapidly through the fascial planes. The incidence of NF is 0.40 cases per 100 000 people[1]. NF has a mortality rate of 34%[2]. The causes of necrotizing soft tissue infections in the lower extremities are animal or insect bites, blunt or penetrating traumas, ulcerated skin infections, drug injection, postoperative complications. Risk factors, such as being over 50 years old, diabetes mellitus, peripheral vascular disease, and other systemic diseases and poor nutrition, increase the mortality rate.

Colonic diverticulosis is a common disease prevalent among advanced age population. Diverticulitis can develop in 10%-25% of

all patients with diverticulosis[3]. The main complications related to diverticulitis are abscess formation, free peritoneal perforation, intestinal obstruction, and internal fistulization.

The presentation of diverticular disease with extraperitoneal findings (<2%) and the development of NF as a complication (<1%) are rare[4].

In this article, we aimed to present a rare case of NF in the left thigh after retroperitoneal abscess fistulization due to diverticulum perforation without acute abdominal symptoms but the complaint of leg pain.

This is an open access journal, and articles are distributed under the terms of the Creative Commons Attribution-NonCommercial-ShareAlike 4.0 License, which allows others to remix, tweak, and build upon the work non-commercially, as long as appropriate credit is given and the new creations are licensed under the identical terms.

**For reprints contact:** reprints@medknow.com

©2019 Journal of Acute Disease Produced by Wolters Kluwer- Medknow. All rights reserved.

**How to cite this article:** Dogan H, Kovanci B. Necrotizing fasciitis of lower extremity due to diverticulitis perforation: a case report. J Acute Dis 2019; 8(3): 130-132.

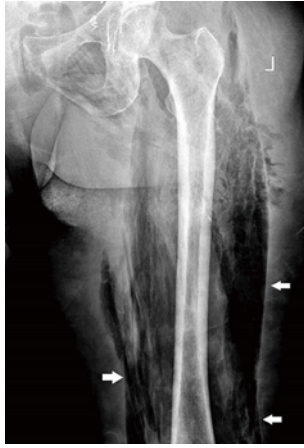<sup>✉</sup>Corresponding author: Halil Dogan, Department of Emergency Medicine, University of Health Sciences Bakirkoy Dr. Sadi Konuk Training and Research Hospital, Istanbul, Turkey.  
Tel: +90 5057067282  
Fax: +902125424491  
E-mail: drhalildogan@gmail.com

## 2. Case report

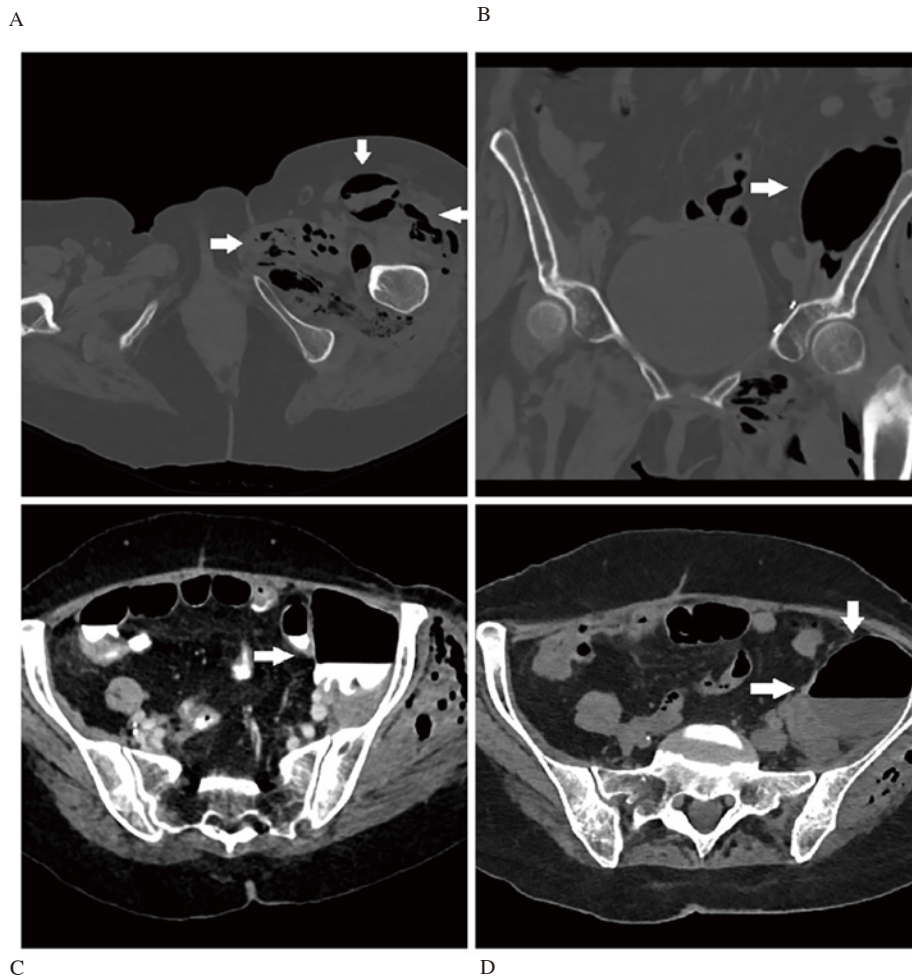
A 58-year-old female patient was admitted to the hospital with the complaint of left leg pain for 15 d. She had hypertension and underwent cervical cancer surgery seven years ago, therefore, she had a history of radiotherapy and chemotherapy.

During the physical examination, the patient was conscious, oriented, and cooperative. The results of the examination were as follows: Blood pressure 100/60 mmHg; heart rate 110 beats/min; respiratory rate 16/min; body temperature: 36.7 °C; SpO<sub>2</sub>: 96%.

Abdomen examination did not reveal abdominal tenderness, defense or rebound. Laboratory test results on admission showed white blood cell (WBC) 12 000/ $\mu$ L (3 700/ $\mu$ L-10 000/ $\mu$ L), hemoglobin 7 g/dL (10.8 g/dL-14.2 g/dL), C reactive protein (CRP) 34 mg/dL (<0.5 mg/dL), creatinine 1.44 mg/dL (0.50 mg/dL-0.90 mg/dL), glucose 65 mg/dL (74 mg/dL-106 mg/dL), sodium 142 mEq/L (136 mEq/L-145 mEq/L), albumin: 2.2 g/dL (3.5 g/dL-5.2 g/dL), lactate: 1.2 mmol/L (0.5 mmol/L-2.0 mmol/L). X-ray of the left



**Figure 1.** X-ray examination of the soft tissue of the left thigh with necrotizing fasciitis reveals the presence of gas (white arrows).



**Figure 2.** Computed tomography (CT) scan reveals the presence of gas in the iliopsoas muscles and abscess formation in the abdominal cavity (white arrows). A: Gas in the iliopsoas muscles; B: Gas in the soft tissues and abscess cavity on coronal view of CT scan; C: Abscess formation in the abdominal cavity on contrast CT scan; D: Abscess formation on non-contrast CT scan.

thigh revealed extensive gas within the soft tissue (Figure 1).

LRINEC score were 6 points, as followings: CRP: 34 mg/dL (CRP>15 mg/dL; 4 points); WBC count: 12 (WBC<15; 0 point); Hemoglobin: 7 g/dL (Hgb<11 g/dL; 2 points); Sodium: 142 mmol/L (Na>135 mmol/L ; 0 point); Creatinine: 1.44 mg/dL (Cr<1.6 mg/dL; 0 point); Glucose: 65 mg/dL (Glucose <180 mg/dL; 0 point).

Abdominal computed tomography showed a pouch filled with extra-lumination of the oral contrast agent extending to the retroperitoneum at the descending colon level.

Abdominal computed tomography scan showed a collection area extending from the paravertebral space to the left inguinal canal in the iliac fossa adjacent to the iliopsoas muscles with accumulation of gas (Figure 2).

The patient, who had a systemic inflammatory response and was thought to have sepsis due to perforation and NF, was treated with operation.

During operation, the perforated area of the sigmoid colon and the abscess in the retroperitoneum where fistulation towards the thigh were seen. Extensive debridement was performed after 22 h when the patient was referred to the emergency department. The patient was thought to have a polymicrobial infection and was given teicoplanin *i.v.* 2 g/d, and meropenem *i.v.* 2 g/d.

The patient was followed-up in the postoperative intensive care unit, and intermittent dressing and debridement were performed. Methicillin-sensitive and coagulase-negative *Staphylococcus* and *Escherichia coli* were isolated in abscess culture.

On the 9th day of postoperative follow-up, the patient died due to sepsis-induced multiple organ failure and severe metabolic acidosis.

### 3. Discussion

NF cases which develop in the thigh due to diverticulitis perforation are rare, and we found only 13 cases in the literature.

Kumar *et al.* reported that 94% of the cases presented with extremity pain[5]; while Angoules *et al.* reported that 73% of patients presented with erythema and 63% with pain[6]. In all of the 13 cases in our literature search, the complaint was limb pain as in our patient. Only 46% of these cases had erythema[7-12]. Otherwise, 8% of them had abdominal pain[8,12]. Therefore, patients with NF of the lower extremity due to diverticulitis perforation may present with only limb pain without abdominal pain or skin signs.

Twenty-three percent of the cases we found in the literature had a history of chronic steroid use due to rheumatoid arthritis[7,9,10]. Kumar *et al.* reported 10% of cases used chronic steroid, but Angoules *et al.* reported only 3% of patients had a history of steroids[5,6]. Although it was not presented in our case, it was seen that the history of chronic steroid use was more frequent in patients with NF due to intestinal perforation. This inference may indicate that steroid use may cause a potential delay in diagnosis by suppressing inflammation and may play a role in the development of NF in the lower extremity after intestinal perforation.

Same with our case, in 53% of the other 13 cases, air images were seen in the soft tissue through extremity X-rays[7-11,13,14]. The extremity X-rays is frequently used in trauma patients, and is

quickly and easily accessible. X-rays may be ordered primarily in non-traumatic extremity pains and may direct the physician to the accurate diagnosis in the presence of a positive finding.

Clinicians should pay more attention to NF which has a high mortality rate in patients with leg pain and sepsis symptoms. Also, diverticulitis perforation should be kept in mind in the etiology of NF in the lower extremity, even if there is no abdominal pain or other common causes.

### Conflict of interest statement

The authors report no conflict of interest.

### References

- [1] File TM Jr, Tan JS, DiPersio JR. Group A streptococcal necrotizing fasciitis. Diagnosing and treating the "flesh-eating bacteria syndrome". *Cleve Clin J Med* 1998; **65**(5): 241-249.
- [2] Wong CH, Khin LW, Heng KS, Tan KC, Low CO. The LRINEC (Laboratory risk indicator for necrotizing fasciitis) score: a tool for distinguishing necrotizing fasciitis from other soft tissue infections. *Crit Care Med* 2004; **32**(7): 1535-1541.
- [3] Khalil HA, Yoo J. Colorectal emergencies: perforated diverticulitis (operative and nonoperative management). *J Gastrointest Surg* 2014; **18**(4): 865-868.
- [4] Gallegos-Sierra C, Gutiérrez-Alfaro C, Evaristo-Méndez G. Enfermedad diverticular complicada iniciada como fasciitis necrosante de miembro pélvico. Reporte de caso. *Cirugía y Cirujanos* 2017; **85**(3): 240-244.
- [5] Kumar D, Cortés-Penfield NW, El-Haddad H, Musher DM. Bowel perforation resulting in necrotizing soft-tissue infection of the abdomen, flank, and lower extremities. *Surg Infect (Larchmt)* 2018; **19**(5): 467-472.
- [6] Angoules AG, Kontakis G, Drakoulakis E, Vrentzos G, Granick MS, Giannoudis PV. Necrotising fasciitis of upper and lower limb: a systematic review. *Injury* 2007; **38**(Suppl 5): S19-S26.
- [7] Braeunling FM, Mackey PM, Wright C, Klimach OE, Ramanaden DN. Cellulitis of the right thigh, with gas. *J R Soc Med* 2003; **96**(11): 553-554.
- [8] Tandon T, Moss MC, Shaik M, Jadhav A, Goyal S. Perforated colonic diverticulum presenting as necrotizing fasciitis of the thigh. *J Orthop Sci* 2005; **10**(5): 534-536.
- [9] Piedra T, Martín-Cuesta L, Arnáiz J, de Lucas EM, Pellón R, García-Bolado A, et al. Necrotizing fasciitis secondary to diverticulitis. *Emerg Radiol* 2007; **13**(6): 345-348.
- [10] Khwaja HA, Zakaria R, Wilde JM. Necrotising fasciitis of the lower limb due to diverticular disease of the sigmoid colon. *Int J Colorectal Dis* 2010; **25**(9): 1145-1146.
- [11] Murphy PB, Belliveau P. Left-sided sigmoid diverticulitis presenting as right-sided thigh abscess. *Int Surg* 2012; **97**(4): 285-287.
- [12] Toro A, Mannino M, Di Carlo I. Thigh emphysema as a first sign of abdominal disease. *Chirurgia (Bucur)* 2013; **108**(2): 277-279.
- [13] Connor MJ, Thomson AR, Grange S, Agarwal T. Necrotizing fasciitis of the thigh and calf: A reminder to exclude a perforated intra-abdominal viscus: A case report. *JBJS Case Connect* 2016; **6**(2): e44. DOI:10.2106/JBJS.CC.15.00217.
- [14] Campbell WJ, Humphries WG. Thigh infection: a rare complication of colonic perforation. *Ulster Med J* 1991; **60**(1): 96-100.