

# Conjunctival infiltration as a relapse of lymphoma

**Zahra Mozaheb**

Hematologist-Oncologist, Mashhad University of Medical Sciences, Mashhad, Iran.

Accepted 11 September, 2018

---

## ABSTRACT

Ocular involvement in patients with hematologic malignancies especially Non-Hodgkin Lymphoma (NHL) remains frequently unrecognized and in consequence not adequately treated. Ocular involvement in different subtypes of Non-Hodgkin's lymphoma is more common than Hodgkin's lymphoma, including predominantly diffuse large B-cell lymphoma (DLBCL), mucosa-associated lymphoid tissue (MALT) lymphoma and T-cell lymphoma. In this report, we present a patient with marginal zone B cell lymphoma that was diagnosed and treated with R-CHOP. He had relapse after three years and treated with R-Bendamustine and again achieved complete remission. He presented with redness of eyes about 2 years later, on July 2017. At first he was treated for conjunctivitis, but subsequently orbital mass was reported in MRI which biopsy from his conjunctive showed low grade lymphoma infiltration in conjunctiva. He did not have response with chemotherapy R-Bendamustin, but he achieved complete response with radiotherapy. Hematologic malignancies with eye involvement may cause permanent damage of visual acuity and its timely recognition and treatment can prevent unnecessary visual loss.

**Keywords:** Ocular lymphoma, immune-privileged, extra-nodal relapse.

E-mail: mozahebz@mums.ac.ir.

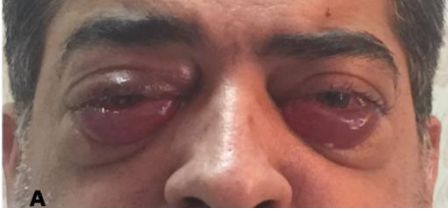---

## INTRODUCTION

Ocular involvement in patients with Non-Hodgkin Lymphoma (NHL) remains frequently unrecognized and in consequence not adequately treated. In these patients, ocular involvement might be overshadowed by more severe and acute local or systemic problems. The eye, likewise the CNS and testis, is an immune privileged site, which makes the pathogenesis of primary vitreo-retinal lymphoma (PVRL) intriguing because the immune system behaves in a different way than in sites that are not immunoprivileged. The eye can be involved in different subtypes of Non-Hodgkin's Lymphoma, and includes predominantly diffuse large B-cell lymphoma (DLBCL), mucosa-associated lymphoid tissue (MALT) lymphoma and T-cell lymphoma. The eye is most frequently involved in DLBCL and its involvement might represent either a primary localisation or metastasis. Ocular involvement in NHL may cause permanent damage of visual acuity and the delay in diagnosis and treatment can prevent unnecessary visual loss. Based on our searching, this is the first report of isolated extra-nodal relapse of NHL with bilateral conjunctival infiltration.

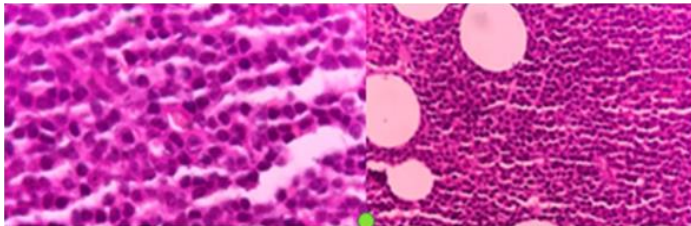
## CASE PRESENTATION

A 54-years old patient with generalized lymphadenopathy, splenomegaly, anemia and B symptom was admitted on July 2012. His lymph node biopsy showed low grade lymphoma with CD20 positivity in immunohistochemistry. He was treated with R-CHOP and achieved complete remission by clinical and imaging, CT scan assessment. He presented again by generalized lymphadenopathy, splenomegaly and mild lymphocytosis after three years. Bone marrow biopsy showed the relapse of lymphoma. He was treated with R-Bendamustine and again achieves good remission in bone marrow and in imaging study (lymphadenopathy less than one centimeter). He presented with red eyes about 2 years later, on April 2017, and at first he treated as an infectious conjunctivitis by ophthalmologist but he did not have any response and had progression (Figure 1). According to ophthalmologic consult pseudo-tumor cerebry was diagnosed and he was treated with systemic corticosteroid, but did not have response. Brain and orbit

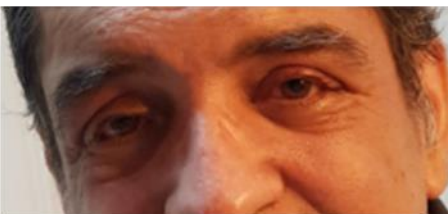

**Figure 1.** Bilateral conjunctival infiltration.

MRI was done and showed diffuse intraconal and extraconal bilateral orbital mass which can be due to lymphoma. Biopsy was taken from the conjunctive of right orbit and pathologist reports showed diffuse infiltration of small and intermediate lymphocyte (Figure 2). In IHC study CD5, CD20, BCL2 was positive and CD10, cyclin D1 was negative, KI67 also was 10%. Based on morphology and IHC finding low grade marginal zone B cell lymphoma was diagnosed. In this time he did not have significant lymphadenopathy and B symptom and also he had normal CBC, ESR=25 and LDH=570. He did not have response with chemotherapy (R-Bendamustin) but he achieved complete response with radiotherapy. Figure 2 shows the feature of his eyes 3 month after radiation (Figure 3).



**Figure 2.** Patologic feature of conjunctival infiltratin, diffuse infiltration of small and intermediate lymphocyte with round and hyperchrom nucleus and scant cytoplasm.



**Figure 3.** Patient eyes after radiation.

## DISCUSSION

At first we thought that the orbital lesion in my patient should be a local lesion, because the patient did not have any other symptom of lymphoma, but in our investigation

we found that it is a lymphoma relapse.

Although the orbit is a small anatomical space, the wide ranges of structures present within it are the original site of different tumors and tumor-like conditions. Cross-sectional imaging is mandatory for the detection, characterization, and mapping of these lesions. Tumor arising from extraconal compartment includes dermoid/epidermoid, lachrymal gland tumors, lymphoma, rhabdomyosarcoma and pseudotumorcerebri was considered (Purohit et al., 2016).

Lymphoma may present with bilateral or unilateral disease, and manifest as the primary extranodal lymphoma or as part of systemic disease. It may present in any compartment, including isolated extraocular muscle enlargement, which a palpable mass is most common (Goh et al., 2008). Sometimes it may mimic orbital inflammation with diffuse infiltration of the intraconal and extraconal space and effacement of normal tissue planes may occur (Aviv and Casselman, 2005).

Extranodal presentation of lymphoma account for between 24 and 35% of new lymphoma cases in different studies and also ocular involvement in different subtypes of Non-Hodgkin's lymphoma including predominantly diffuse large B-cell lymphoma (DLBCL), mucosa-associated lymphoid tissue (MALT) lymphoma and T-cell lymphoma is rarely seen (Newton et al., 1997; Mozaheb et al., 2011).

CT and/or MRI are essential in the evaluation and distinguishing between benign and malignant lymphoid proliferations and between inflammatory and lymphoproliferative lesions in orbit. In most cases, we were unable to distinguish reactive lesions from true lymphoma (Polito et al., 1996), like our patient, which led to delays in diagnosis. PET have an important role in assessment of ocular adnexal lymphoproliferative disease with real impact on patient management (Sullivan and Valenzuela, 2006).

Conjunctival infiltration in patients with a history of previous hematologic malignancies should raise the suspicion for local recurrent disease that warrants urgent biopsy and systemic treatment. The eye symptoms and red eye may be the first sign of relapse after remission such as our patient (Mozaheb and Khooei, 2018).

Certain sites of the human body are able to tolerate the introduction of antigens without eliciting an inflammatory immune response, meaning they have immune privilege (Zhou and Caspi, 2010). The inhibitory ocular microenvironment, composed of cell-bound and soluble immunosuppressive factors within the eye, inhibits the activity of immune-competent cells (Taylor, 2009).

## Conclusion

In conclusion, we suggest that eye lymphoma relapse occurred because it may be an immune-privileged site like brain, testis, for lymphoma and other hematologic

malignancies relapse and will further highlight the importance of this site for cancer relapse. Hematologic malignancies with eye involvement may cause permanent damage of visual acuity, therefore; rapid diagnosis and treatment can prevent unnecessary visual loss.

## ACKNOWLEDGEMENTS

We would like to forward our appreciation to the Department Ophthalmology, Mashhad University of Medical Science for being handy in the diagnosis of this case. We would like also to thank the family of this patient for allowing us to publish the case and our colleagues in radiology and pathology for their help in the realization of this case.

## REFERENCES

- Aviv R, Casselman J, 2005.** Orbital imaging: part 1. Normal anatomy. *Clinical Radiol*, 60(3): 279-287.
- Goh P, Gi MT, Charlton A, Tan C, Gangadhara Sundar JK, Amrith S, 2008.** Review of orbital imaging. *Eur J Radiol*, 66(3): 387-395.
- Mozaheb Z, Aledavood A, Farzad F, 2011.** Distributions of major subtypes of lymphoid malignancies among adults in Mashhad, Iran. *Cancer Epidemiol*, 35(1): 26-29.
- Mozaheb Z, Khooei A, 2018.** Bilateral conjunctival infiltration as an extramedullary relapse of AML. *Case Rep Hematol*, vol. 2018.
- Newton R, Ferlay J, Beral V, Devesa SS, 1997.** The epidemiology of non-Hodgkin's lymphoma: Comparison of nodal and extra-nodal sites. *Int J Cancer* 72(6): 923-930.
- Polito E, Galieni P, Leccisotti A, 1996.** Clinical and radiological presentation of 95 orbital lymphoid tumors. *Graefes Arch Clin Exp Ophthalmol*, 234(8): 504-509.
- Purohit BS, Vargas MI, Ailianou A, Merlini L, Poletti PA, Platon A, Delattre BM, Rager O, Burkhardt K, Becker M, 2016.** Orbital tumours and tumour-like lesions: exploring the armamentarium of multiparametric imaging. *Insights Imaging*, 7(1): 43-68.
- Sullivan TJ, Valenzuela AA, 2006.** Imaging features of ocular adnexal lymphoproliferative disease. *Eye*, 20: 1189-1195.
- Taylor A, 2009.** Ocular immune privilege. *Eye*, 23(10): 1885-1889.
- Zhou R, Caspi RR, 2010.** Ocular immune privilege. *F1000 biology reports* 2.

---

**Citation:** Mozaheb Z, 2018. Conjunctival infiltration as a relapse of lymphoma. *Int Res J Med Med Sci*, 6(x): xx-xx.

---