

## Comparative study for evaluation of ErCr:YSGG laser gingivectomy over conventional scalpel gingivectomy

Amit Kumar Srivastava<sup>1,\*</sup>, Prasanta Bandyopadhyay<sup>2</sup>, Manoj Kumar<sup>3</sup>, Neha Bhutani<sup>4</sup>, Deepak Sangoliker<sup>5</sup>

<sup>1,3-5</sup>Reader, <sup>2</sup>Professor and HOD, Dept. of Periodontics <sup>1,4,5</sup>Purvanchal Institute of Dental Sciences, Gorakhpur, Uttar Pradesh,

**\*Corresponding Author: Amit Kumar Srivastava**

Email: amit.radc@gmail.com

### Abstract

**Introduction:** Laser is one of the most important latest addition in the existing list of advanced equipments. However exaggerated marketing claims by clinician and manufacturers initiated falsely elevated expectations with regard to performance of laser in dentistry.

**Aims and Objectives:** The aims and objectives of present study was to evaluate the efficacy of ErCR:YSGG laser gingivectomy over conventional scalpel gingivectomy.

**Materials and Methods:** Twenty patients (20) with a total of Forty (40) quadrants of gingival enlargements were selected for external bevel gingivectomy. Patients divided into following groups: Group-A (Test Group) after phase1 therapy remaining suprabony pocket/enlarged gingiva removed by laser gingivectomy using Er,Cr:YSGG laser in 20 patients. Group-B (Control Group): After phase1 therapy remaining suprabony pocket/enlarged gingiva removed by conventional scalpel gingivectomy in 20 patients. The clinical evaluations were done under the following parameters: 1) Per & Post -operative bleeding 2) Postoperative pain 3) Postoperative swelling. Patients were evaluated at 1st, 2nd, 3rd, 7th, 14th, 28th day after gingivectomy.

**Results and Conclusion:** All peroperative and postoperative records were compared between test & control groups. Following conclusions are drawn from the present study: Laser gingivectomy is superior to scalpel gingivectomy in terms of controlling per and post operative bleeding, postoperative pain and postoperative swelling as compared to scalpel gingivectomy.

**Keywords:** Er,Cr:YSGG laser, Gingival enlargement, Gingivectomy, Acetaminophen, Visual analog scale.

### Introduction

Lasers have emerged as one of the most important addition in the advances made in the field of dentistry. Laser stands for '*Light Amplification by Stimulated Emission of Radiation*'. The first laser device, Ruby laser was invented by Maiman in 1960, based on theories advocated by Einstein in the early 1900s.<sup>1</sup> Laser treatment is expected to serve as an alternative or adjunctive to conventional mechanical periodontal treatment. Currently, among the different types of lasers available, Er:YAG and Er,Cr:YSGG lasers possess characteristics suitable for dental treatment due to its dual ability to ablate soft and hard tissues with minimal damage. However exaggerated marketing claimed by the clinicians and manufacturers initiated falsely elevated expectations with regard to performance of lasers in dentistry. Hence it was important to evaluate the advantages and disadvantages of laser surgery over traditional scalpel surgery.

### Materials and Methods

For carrying out the present study, the subjects were selected from the outpatient department of Periodontics, Dr. R. Ahmed Dental College and Hospital, 114, A. J.C Bose Road Kolkata-14. All patients were explained about the study and informed consent was obtained from them. Ethical committee clearance was obtained before starting the study.

**Subject Selection:** Patients of both sexes, age group ranging between 18-45 years with good general health and oral hygiene habit, not taken any systemic antibiotic since last six months were included in the study. Patients with moderate to advanced periodontal destruction with

suprabony pocket  $\geq 5$ mm in depth or gingival enlargement in which bottom of pockets not apical to mucogingival junction were included in the study.

**Study Design:** Primarily the present study was designed as prospective controlled clinical trial. Twenty patients with a total of forty quadrants of gingival enlargement were selected for external bevel gingivectomy. The surgical areas covering not less than three teeth were included in the study. The selected sites were randomly divided into test group and control group and were treated according to split mouth design technique as follows: **Group-A (Test Group):** After phase-1 therapy remaining suprabony pocket / enlarged gingiva removed by laser gingivectomy using Er,Cr:YSGG laser in twenty (20) patients. **Group-B (Control Group):** After phase-1 therapy remaining suprabony pocket / enlarged gingiva removed by conventional scalpel gingivectomy in twenty (20) patients.

**Armamentarium:** In control group conventional gingivectomy performed by using Bard Parker Handles with No. 11 and 15 blades, Crane Kaplan Pocket Marker, Kirkland Knife, Blake's Handle, Orban Knife, Tissue Forceps and Curettes. In test group Laser gingivectomy was performed by using Er,Cr:YSGG Laser (Waterlase)(2780nm) with Tips (T4,G6).

**Pre-surgical Consideration:** All patients were subjected to a thorough initial mouth preparation, oral hygiene instructions, scaling, root planing and polishing etc. at least one week before surgery to minimize gingival inflammation so that identical clinical pictures existing in all surgical areas in the same mouth.

## Surgical Procedures

**a) Scalpel Gingivectomy:** Following administration of local anaesthetic agent (Lignocain HCl 2% with Adrenalin 1:100000), pocket depth marked with the help of pocket marker facially and lingually. External bevel gingivectomy was performed as described by GOLDMAN.<sup>2</sup> (Fig. 1)

**b) Laser Gingivectomy:** Following administration of topical anaesthetic (Lignocaine aerosol 15% w/w) over surgical area, pocket was explored and marked with pocket marker. Proper eye protection was employed. Laser gingivectomy was performed utilizing the Er,Cr:YSGG laser with a T4 & G6 sapphire tip, 0.5 W, 11% Air, 7% water. Excess gingival tissues were reduced in a motion very similar to festooning of gingiva. The calculi and necrotic cementum were removed, the root surfaces were smoothed using scalers and curettes after which the areas were cleaned and washed with normal saline. (Fig. 2) Aluminium foil was placed over the surgical area in both test and control group before ZOE periodontal dressing, isolating the surgical area from direct contact of dressing.

**Post-Surgical Consideration:** Patients were under proper antibiotic coverage and advised to take 1 Tab Acetaminophen (Paracetamol) 500mg only in case of pain. Patients were recalled at 1<sup>st</sup>, 2<sup>nd</sup>, 3<sup>rd</sup>, 7<sup>th</sup>, 14<sup>th</sup> and 28<sup>th</sup> day post-surgery. At each of the recall visits, oral hygiene was assessed and oral hygiene instructions were reinforced. All postoperative recordings were compared with preoperative pictures recorded just before surgical interventions on a carefully prepared history sheet utilizing same parameters.

## Parameters Studied

**1. Per & Postoperative Bleeding:-** During surgery and at every recall visit post-surgery, operated area were assessed for bleeding only by visual inspection.<sup>3</sup>

**Bleeding Scoring-** Score 0-None (No Bleeding), Score 1-Mild, Score 2-Moderate, Score 3-Severe

**2. Postoperative Pain:-a.** The visual analog scale (VAS) was used to evaluate the subjective pain level experienced by each patient. It consists of a 0-10cm scale with 1cm graduations. The level "No Pain" was given position zero, and level "Most Severe Pain" was given position ten.<sup>4</sup> Pain Scoring -Score 0-None (No Pain), Score 1-Mild, Score 2-Moderate, Score 3-Severe

**b.** No. of analgesic (Acetaminophen 500mg) tablets taken on postoperative days: Tab Acetaminophen (500mg) was prescribed as the oral analgesic drug for pain relief in all the patients. They were strictly instructed to take analgesic drugs whenever the subject suffered from pain and could repeat the dose every 4 hour. The pain score and no. of analgesics taken by the patient were recorded at every recall visits.<sup>4</sup>

**Postoperative Swelling:** At every post-surgical recall visit operated area were assessed for swelling by visual scoring system. Swelling Scoring Score 0-None (No Swelling), Score 1-Mild, Score 2-Moderate, Score 3-Severe.

## Statistical Analysis

Statistical analysis was employed to compare the study results using a computer software program (SPSS 11.0 version). To determine the differences in the distribution of various parameters in test and control groups the Contingency Chi-Square Test were utilized. Chi-square and p values were obtained with appropriate level of significance.

## Results and Analysis

**Per and Postoperative Bleeding:** The distribution of bleeding conditions between two groups were significantly varied during surgery ( $p < 0.01$ ) and on 1<sup>st</sup>, 2<sup>nd</sup>, 3<sup>rd</sup> ( $p < 0.05$ ) postoperative days. Laser gingivectomy indicated comparatively better technique in order to reduce bleeding at per and postoperative days. (Diagram 1)

**Pain:** Pain on postoperative days in test and control groups showed significant ( $p < 0.05$ ) distribution on 1<sup>st</sup> postoperative day when using two different techniques (Scalpel & Laser gingivectomy). On 2<sup>nd</sup> & 3<sup>rd</sup> postoperative day pain was comparatively less with laser gingivectomy but the Chi-square value was statistically not significant. Laser gingivectomy appears comparatively more efficient in reducing pain after gingivectomy. (Diagram 2)

**No. of analgesic (Acetaminophen 500mg) tablets:** On day 1 after gingivectomy 40% of test groups were not required any analgesic in contrast to control groups where only 20 % cases were not taken any analgesic tablet. Although no. of analgesic tablets taken by the patients were more with scalpel gingivectomy on 1<sup>st</sup> and 2<sup>nd</sup> postoperative day, the distribution was statistically not significant ( $p > 0.05$ ).

**Swelling:** Postoperative swelling in both test and control groups was significant at ( $p < 0.01$ ) on 1<sup>st</sup> and 2<sup>nd</sup> postoperative day between the two groups. Significantly more swelling was found associated with scalpel gingivectomy compared to laser gingivectomy. (Diagram 3)

## Discussion

In the present study Er,Cr:YSGG laser was used having wavelength of 2780nm emitted in a free running pulse mode through fiberoptic delivery system. These wavelengths are well absorbed by hydroxyapatite and water of the target tissue, making the Er,Cr:YSGG laser suitable for both soft and hard tissues.<sup>5</sup> It was noted that scalpel incision was sharp and smooth. Laser incisions had a characteristic roughness with the whitish border in the some region of gingiva. In terms of qualitative analysis of surgical incision laser surpassed scalpel showing few advantages. Less bleeding with laser provided 'clear' operative field. In addition precision of tissue ablation improved when there was no need for applying pressure to incise tissue in case of laser. This feature could justify the use of laser while giving incision in highly vascular and resilient oral tissues. On the other hand scalpel incision was somewhat swifter and produced sharper incision. In the present study it was observed that bleeding was significantly greater with scalpel gingivectomy on peroperative and 1<sup>st</sup>, 2<sup>nd</sup> and 3<sup>rd</sup> postoperative days compared to laser gingivectomy. Sushma

et al in 2009 suggested that this characteristics of laser might be due to it's ability to seal small blood vessels upto a diameter of 0.5mm.<sup>3</sup> Mild bleeding was also found to be associated with laser gingivectomy. Less susceptibility of Er,Cr:YSGG laser to chromatophores (eg. melanin and hemoglobin) compared to other laser wavelengths may be the reason behind this. The present study indicated Er,Cr:YSGG laser would be superior to scalpel in terms of postoperative pain and wound healing. Less postoperative pain with laser may be explained by the fact that noxious stimulation produced neurogenic inflammation (axon reflex) as suggested by Meyer et al in 1994.<sup>6</sup> Schuller in 1990 proposed reduced pain sensation with laser may be because of heat transfer to the deeper tissue causing thermal necrosis and thermal coagulation of protein over the surface of the tissue. This act as a biological wound dressing and seals the ends of peripheral sensory nerves thereby reducing pain sensation.<sup>7</sup> On 1<sup>st</sup> and 2<sup>nd</sup> postoperative days swelling was significantly more with the scalpel gingivectomy. Camillo et al opined that scalpel wound allows extravasation of blood and lymph, causing more marked inflammatory response with resultant swelling and formation of scar.<sup>8</sup>In contrast to scalpel, Hall in 1971 claimed that laser sealed the lymphatics and blood vessels causing minimal extravasation of fluids, resulting in a minimal inflammatory response around the wound.<sup>9</sup>

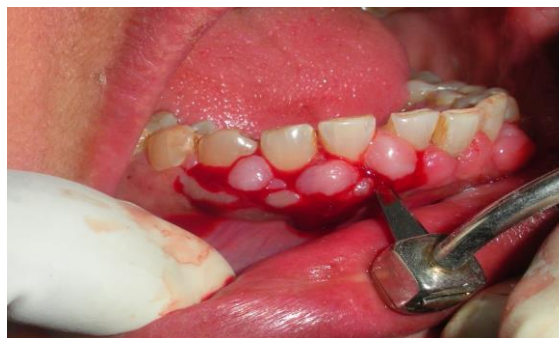

Fig. 1: External bevel gingivectomy using Blake's handle and blade

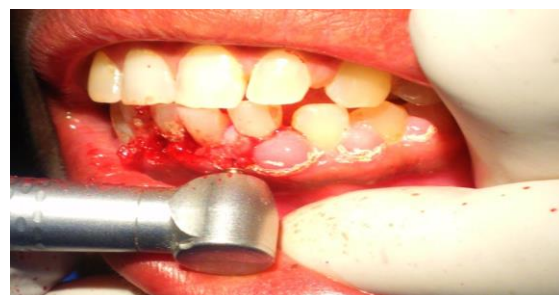

Fig. 2: External bevel gingivectomy by ErCr:,YSGG laser

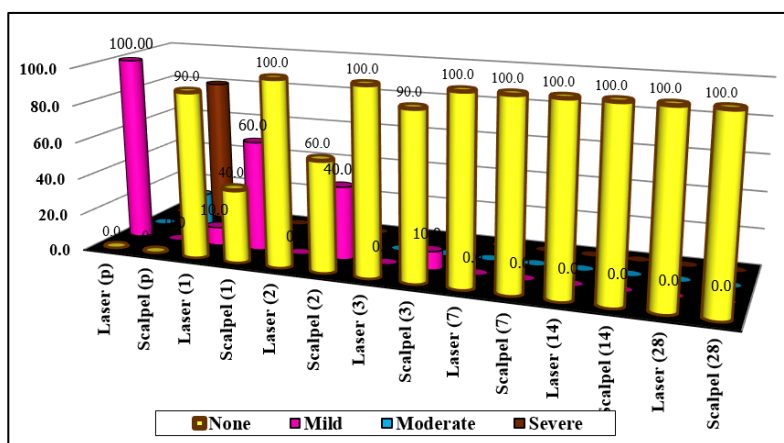


Diagram 1: Showing distribution of per (p)and postoperative bleeding (on day1,2,3,7,14 &28) in test & control groups

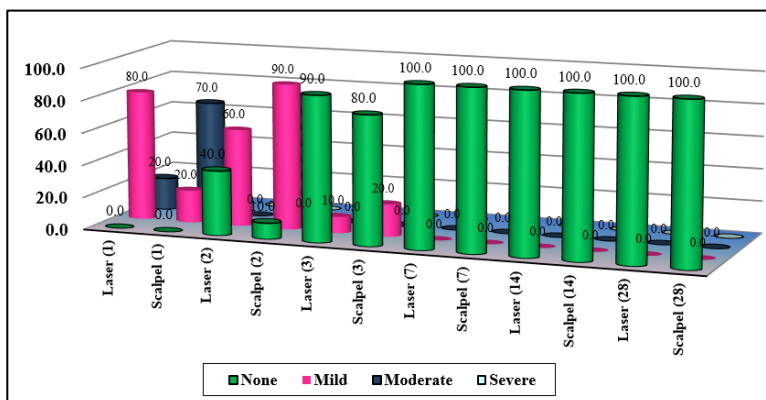
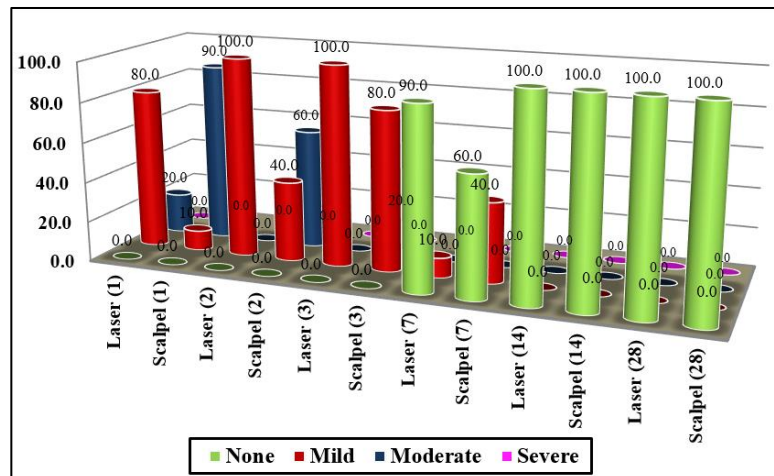


Diagram 2: Showing distribution of postoperative pain (on day1, 2, 3, 7, 14 &28) in test & control groups



**Diagram 3: Distribution of postoperative swelling (on day1, 2, 3, 7, 14 & 28) in test & control groups**

### Conclusion

Laser gingivectomy is superior in terms of controlling per and Post-operative bleeding, postoperative pain and Postoperative Swelling as compared to scalpel gingivectomy. The present study, is first of it's kind but to avoid exaggerated claims & drawing a definite conclusion regarding the efficacy of Er,Cr:YSGG lasers, further study involving higher number of samples are warranted.

### References

1. Maiman TH. Stimulated optical radiation in ruby. *Nature*. 1960;187:493-494. (Cited in:-Charles M Cobb.Lasers in Periodontics: A Review of the Literature. *J Periodontol*. 2006;77:545-564.
2. Goldman H M. Gingivectomy. *Oral Surg Oral Med Oral Pathol*. 1951;4:1136-1157.
3. Sushma Lagdive, Yogesh Doshi, P. P. Marawar. Management of gingival hyperpigmentation using surgical blade and diode laser therapy: A comparative study. *J Oral Laser Appl*. 2009;9:41-47.
4. N Thuaksuban, T Nuntanaranont. A comparative study of postoperative pain using CO<sub>2</sub> laser and scalpel in maxillofacial soft tissue surgery. *Int Congress Series*. 2003;1248:377-381.
5. Bornstein ES, Lomke MA. The safety and effectiveness of dental Er: YAG lasers: a literature review with specific reference to bone. *Dentistry Today*. 2003;129-133.
6. Meyer RA, Campbell JN, Raja SN. Peripheral neural mechanisms of nociception. In: Wall PD, Melzack R, editors. *Textbook of pain*. London: Churchill Livington1994:13-44
7. Schuller DE. Use of the laser in the oral cavity. *Otolaryngol Clin North Am*. 1990;23:31-42.
8. Camillo D Arcangelo, Franca Di Nardo Di Maio. A preliminary study of healing of diode laser versus scalpel incisions in rat oral tissue: a comparison of clinical, histological and immune-histochemical results. *Oral Surg Oral Med Oral Pathol Oral Radiol Endod*. 2007;103:764-773.
9. Hall R R. The healing of tissues incised by CO<sub>2</sub> laser. *Br J Surgery*. 1971;58:222.

**How to cite this article:** Srivastava A. K, Bandyopadhyay P, Kumar M, Bhutani N, Sangolika D. Comparative study for evaluation of ErCr:YSGG laser gingivectomy over conventional scalpel gingivectomy. *Int J Oral Health Dent*. 2018;4(4):222-225.