

Functional outcome of fracture middle-third clavicle treated in tertiary institute

Eeshan Bhardwaj^{1,*}, F. Abdul Khader²

¹Post Graduate, ²Associate Professor, Dept. of Orthopaedics, Shri Sathya Sai Medical College & Research Institute, Ammapettai, Tamil Nadu, India

***Corresponding Author: Eeshan Bhardwaj**

Email: dreeshanb@gmail.com

Abstract

Introduction: Clavicle is the bone which links thorax to the shoulder and help in movements at shoulder joints. It is the first long bone to ossify in the body. Clavicle fractures are the most common fractures in the upper limb. The purpose of this study is to measure the functional outcome of mid third displaced clavicular fractures treated by open reduction and internal fixation with plate osteosynthesis and conservative management.

Materials and Methods: This study was done in Tertiary Institute, Ammapettai, in between May 2017 – September 2018, Ethical committee approval obtained, IHEC No: 2017/312. Patients were allocated in two groups and were given treatment as per the group. 20 cases were treated conservatively and 20 with plate osteosynthesis. Patients were followed every 3rd, 6th, 9th month.

Result: The mean union rate in our study was 10 weeks and constant shoulder score was 90 for conservative group. 20 patients in plate Osteo-synthesis the average union was 6wks and constant shoulder score was about 95 with an excellent grade.

Conclusion: Plate osteosynthesis in displaced midshaft clavicle fracture has resulted in excellent functional outcomes and also good union rate.

Keywords: Clavicle, Middle third, Displaced fracture, Conservative, Surgical, Plate osteosynthesis.

Introduction

Clavicle fractures are common injuries in adults (2-5%).¹ Fracture of middle third of clavicle forms (70-80%) whereas lateral fracture contributes to (15-30%) and medial fracture 3% which are least common. Incidence peaks in 3rd decade of life.² Non operative treatment is no longer valid in treating clavicle fractures with good functional outcomes.³ In some studies non –union rate reported in mid clavicle fracture is 15% treated conservatively.⁴ Mid shaft fractures of clavicle treated conservatively with axial shortening leads to non-union, malunion.⁵ Other symptoms include neurological complications, restricted shoulder movement, protuberant callus which is cosmetically unfavourable for the patient. Patients with higher activity level and rigorous daily routine work will not accept the treatment which give prolonged recovery and restricted shoulder movements.

Early fixation of the clavicle gives better shoulder functions and provides comfort to the patient. Successful surgical interventions for middle third clavicle fracture includes plate osteosynthesis fixation and intramedullary nailing like “TENS” nailing.

Open reduction and internal fixation with plating provides rigid fixation, early functional recovery which lowers the incidence of non-union and malunion. Surgical treatment of middle shaft fracture results less no of cases with non-union as compared to conservative treatment.⁶ We have taken this study of middle third clavicle fracture to see the functional outcomes on the patients undergoing treatment with plate osteosynthesis and conservative.

Objective

To evaluate the functional outcome of fracture middle-third clavicle treated with conservative or Plate osteosynthesis in the patients treated in tertiary institute.

Materials and Methodology

Total of 40 patients were studied in this project.

Out of 40 patients,

1. 20 patients were included in conservative group, 16 Male, and 4 females.
2. 20 patients in plate osteo-synthesis group, 15 males and 5 females.

In both groups 16 patients had right side clavicle fracture and 4 patients had left side clavicle fracture. The mean age of patients treated conservatively was 33.10 years, and the mean age in years of patients treated with plate osteo-synthesis was 34.15 years.

Mode of Injury

In both groups, road traffic accident was the most common mode of injury (80%); fall on out-stretched hand was 20%. When the patient presented to us we took two views of clavicle x-ray (AP view and Zanca view). Informed and written consent were obtained from all patients in both groups. Patients were followed up for a period of 9 months (2, 4 & 6 months) from the date of Conservative / surgical intervention and evaluated clinically with Constant and Murely⁷ scoring system.

Patients whoever not willing for surgery, Conservative management was done.

Statistical Analysis

The collected data was analysed with SPSS software. To describe about the data descriptive statistics frequency analysis, percentage analysis were used for categorical variables and the mean & S.D were used for continuous variables. To find the significant difference between the bivariate samples in Independent groups (Conservative & Operative) unpaired sample t-test was used. To find the significance in categorical data Chi-Square test was used. In

both the above statistical tools the probability value .05 is considered as significant level.

Inclusion Criteria

1. All patients with age more than 18 years 60 years.
2. Closed fractures
3. Patients with displaced fracture of middle third of clavicle.

Exclusion Criteria

1. Age < 18 years
2. Open fractures
3. Fracture in proximal or distal third of clavicle.
4. Pathological fractures
5. Polytrauma.
6. Associated with neuro vascular injury
7. Established non-union from previous fracture.

Conservative Treatment

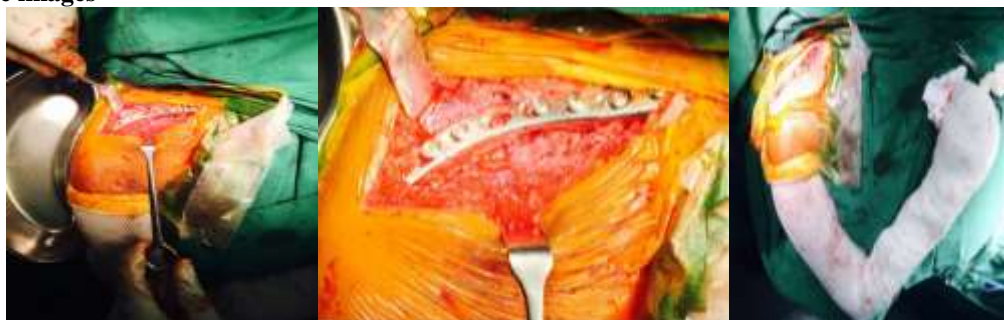There are various conservative treatment^{10,11} options available, the commonest being the use of a sling or 'figure-of-eight' bandage.^{12, 13}

1. In adults, the undisplaced fracture is treated with triangular sling which supports the upper limb, with active exercises of fingers, wrist and elbow (50 times, thrice a day). The sling is removed after 3 weeks and shoulder exercises is advised.
2. If the fracture fragments are displaced, the distal fragment is lifted upwards and pulled backwards and figure of 8 bandage is applied with good padding of both axilla with cotton.
3. Often no subsequent therapy is suggested to the patient. Sometimes, however, a patient will require stretching exercises to regain motion.
4. Periodic check-ups are important to look pressure sores in the axillary folds by figure of 8 bandage.
5. The patient with a structured rehabilitation in order to have a satisfactory outcome for most patients. To protect the healing clavicle, it is important to avoid contact sports for a minimum of 4 to 5 months.
6. Midshaft clavicle fracture goes on to healing with any method of immobilization. The choice of immobilization, then, should reflect patient comfort and function issues rather than anticipated healing rates.

Operative Technique

Under general anaesthesia, patient positioned in supine with sand bag under the scapula. Shoulder prepared and

Intra operative images



draped, and incision made over the fractured clavicle site. The fracture site identified, and fracture reduction done and fixed with a 3.5 mm pre-contour plate. Plate was fixed over bone at superior surface, with the goal of achieving minimum of three screws in the proximal and distal fragments in most cases, with care being taken to preserve soft-tissue attachments. The delto-trapezial fascia was closed with interrupted number-1 absorbable sutures as a distinct layer, followed by skin closure.¹⁴

Instruments used for middle 3rd clavicle fixation

1. 3.5mm reconstruction plate, 1/3 tubular plate.
2. 2.7 mm drill bit
3. 3.5mm universal drill guide.
4. Hand drill/pneumatic drill
5. 3.5mm Tap for cortical screw
6. Depth gauge
7. 3.5mm cortical screw of varying sizes (12-22mm).
8. Screw driver
9. General instruments like retractor, periosteal elevator

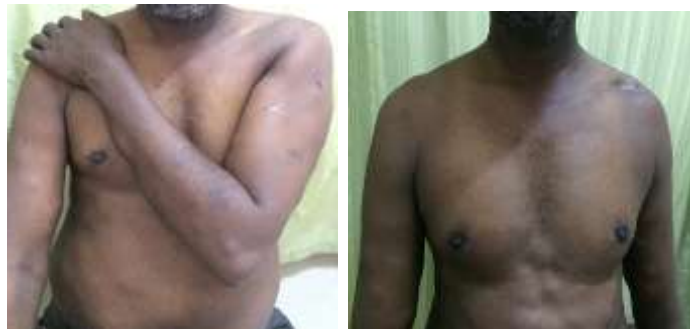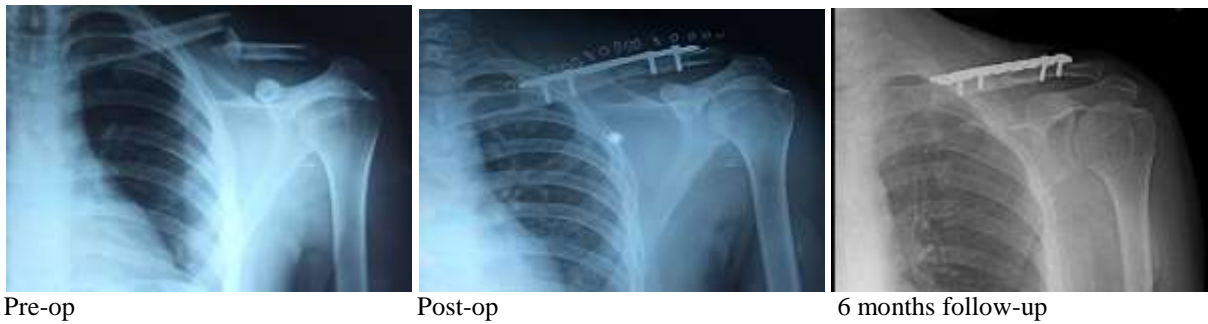Post Operative Protocol

Patients were started on IV antibiotics and analgesics. The wound was inspected on 2 post-operative day. On 12th day of the surgery the sutures were removed. The arm were kept in broad arm sling for six weeks. The Pendulum exercises were started within the first 24 hours after surgery. After the suture removal, passive flexion and extension exercises were started. All patients are sent for physiotherapy. Patients were followed up clinically and radiologically at 3 week, 3 month, 6 month and 9 months after surgery. The functional outcome was assessed by Constant and Murley¹³ score.

Results

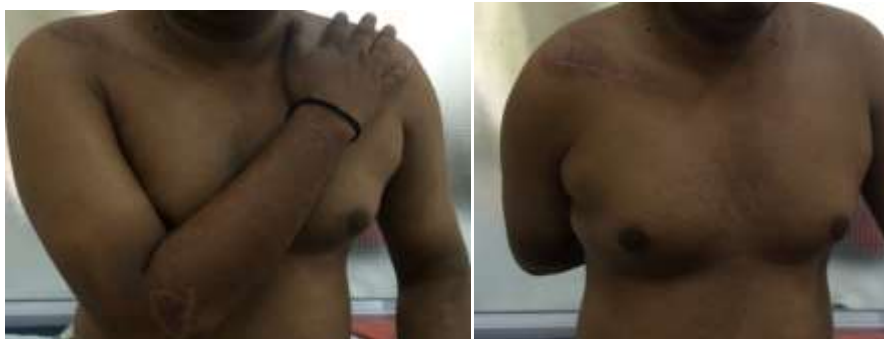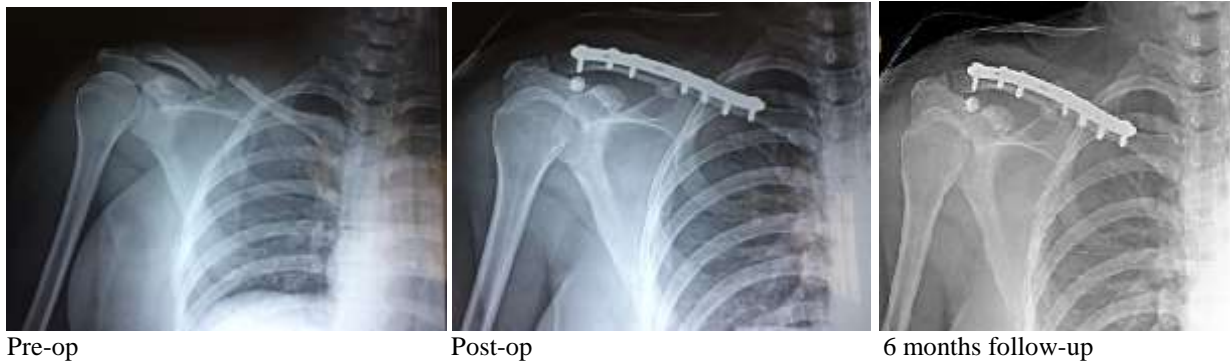
Among 20 patients in conservative group, 1 patient had non-union for whom plate osteo-synthesis with bone grafting was done. The average union rate was 10.75wks and constant shoulder score was 90 with good grade. 20 patients in plate osteo-synthesis the average union was 6wks and constant shoulder score was about 95 with an excellent grade. All other patients had excellent result with good range of movements & excellent radiological union.

Case 1: Shows rigid fixation and union with good functional outcomes



Good range of movements achieved

Case 2: Shows rigid fixation with excellent functional outcomes



Good range of movements achieved

Discussion

Our study shows, significant outcome of clavicle fractures middle third treated operatively. Patients who were treated early for middle clavicular fractures by internal

fixation gave a better postoperative outcome, quick pain relief, patient satisfaction and comfort in daily activities. A study conducted over 868 patients in U.S.A with clavicle fractures, out of them 581 had midshaft diaphyseal fracture. And it came out to be a higher non- union rate 21% for the

displaced, comminuted midshaft fracture and was statistically significant ($p < 0.05$).

Another study on fifty two patients done in Canada having displaced midshaft clavicular fractures and found that 8 patients had non-union and 16 patients had a poor outcome. And it was concluded that displaced fracture fragments more than 2 cm had an unsatisfactory result.

A recent meta-analysis reported that rate of non-union in clavicular fractures was 2.2% in displaced midshaft fractures among ten patients out of four hundred sixty patients after plate fixation (15%) when compared with non-operative care risk was reduced by 86%. This study also showed that plate fixation was safe and reliable operative mode.

Union ranging from 94-100%, lesser surgical complications, and decreased chances of infection were the result of acute midshaft clavicular fractures. Met analysis done over four hundred and sixty patients has reported a rate of non-union of 2.2%. Plate fixation has proven to be superior operative mode with the use of prophylactic antibiotics.

Neurovascular abnormalities were noted in 6% of the patients who were treated conservatively, this abnormalities were the result from callus formation and non-union. In our study there were no neurological abnormalities found.

Patients who were treated conservatively had some disability in the affected side with some loss of muscle strength. In our study range of motion was good and mean score was 90.

Treatment of displaced clavicular fractures by internal fixation is the best option as it provides early pain relief, return of shoulder functions and also in daily activities and work.

There are many methods explained to treat mid shaft clavicle fractures such as intramedullary nailing which resulted into no of complications rotational instability, tense nail migration, fixing screws or wire within the fragment leads to immobilization and is not sufficient. In our study we chooses rigid fixation of the plate which gives good results in treatment of acute clavicular fractures.

So we should consider treatment of acute middle third clavicular fractures should be reserved for the patients who choice to return early to their daily activities. Patients should be informed about the infection and wound complications.

Limitations

In our study proper follow up was not possible upto 1 year due to irregularity of the patients. Open fractures were not included in our study. Even patients who presented with non-union of mid third clavicular fractures were excluded from the study.

Conclusion

Operative treatment resulted in early return to function and better anatomical stability as compared to conservative treatment.

Funding: Nil.

Conflict of Interest: None.

Ethical Approval: Institutional ethical committee approval obtained - IHEC No: 2017/312.

References

1. Craig EV, Basamania CJ, Rockwood CA. Fractures of the clavicle. In Rockwood CA, Matsen FA, Wirth MA, Lippitt SB, editors. The shoulder. 3rd edition. Philadelphia: Saunders. 2004;455-519.
2. Jupiter JB, Leffert RD. Non-union of the clavicle associated complications and surgical management. *J Bone Joint Surg* 1987;69:753-760.
3. Hill JM, Mcguire MH, Crosby LA. Closed treatment of displaced middle third fractures of the clavicle gives poor results. *J Bone Joint Surg* 1997;79:537-40.
4. Chen CH, Chen IC, Wang C. Semi tubular plates for acutely displaced midclavicular fractures: a retrospective study of 111 patients followed for 2.5 to 6 years. *J Orthop Trauma* 2008;22:463-466.
5. Lazarus MD. Fractures of the Clavicle. In: Bucholz RW and Heckman JD, editors. Rockwood and Green's fractures in adults, 5th edition, Philadelphia: Lippincott Williams and Wilkins. 2001;1041-1078.
6. Robinson CM. Fractures of the clavicle in the adult Epidemiology and classification. *J Bone Joint Surg* 1998;80:476-484.
7. Constant CR, Murley AHG. A clinical method of functional assessment of the shoulder. *Clin Orthop Relat Res* 1987;214:160-164.
8. Creashaw AH. Fractures of shoulder, arm and forearm. In: Canale ST, editor. Campbell's operative orthopaedics, 10th edition. St. Louis Mosby. 2003;2985-3071.
9. Nordqvist A, Petersson CJ, Johnell I. Mid clavicular fractures in adults: end result study after conservative treatment. *Orthop Trauma* 1998;12:572-576.
10. Robinson CM, Court Brown. CM, Mcqueen MM, Walkefield AE. Estimating the risk of non-union following non-operative treatment of a clavicular fracture. *J Bone Jt Surg* 2004;86:1359-1365.
11. Solheim K, Vaage S. Delayed union and nonunion of fractures: clinical experience with the ASIF method. *J Trauma* 1973;13:121-128.
12. Mishra A, Kumar D, Yadav A, Pandey D, Sinha A. Functional outcome of conservative versus plate osteosynthesis in displaced midshaft clavicle fracture in manual labours. *Int Surg J* 2017;4:966-970.
13. Rowe CR. An atlas of anatomy and treatment of midclavicular fractures. *Clin Orthop Relat Res* 1968;58:29-42.
14. Nordqvist A1, Petersson CJ, Redlund-Johnell I. Midclavicle fractures in adults: end result study after conservative treatment. *J Orthop Trauma* 1998;12(8):572-576.
15. Robinson CM1, Goudie EB, Murray IR, Jenkins PJ, Ahkter MA, Read EO et al. Open reduction and plate fixation versus nonoperative treatment for displaced mid shaft clavicular fractures: a multicenter, randomized, controlled trial. *J Bone J Surg Am* 2013;4;95(17):1576-1584.
16. VanBeek C1, Boselli KJ, Cadet ER, Ahmad CS, Levine WN. Precontoured plating of clavicle fractures: decreased hardware-related complications? *Clin Orthop Relat Res* 2011;469(12):3337-3343.
17. Judd DB, Pallis MP, Smith E, Bottoni CR. Acute operative stabilization versus non operative management of clavicle fractures. *Am J Orthop* 2009;38(7):341-345.

18. Witzel K. [Intramedullary osteosynthesis in fractures of the mid-third of the clavicle in sports traumatology]. *Z fur Orthop und Unfallchirurgie* 2007;145(5):639-642. doi: 10.1055/s-2007-965616.
19. Neer CS II. Fracture dislocation of the shoulder. In: Rockwood CA Jr, Green DP (eds) *Fractures in adults*, 2nd edn. Lippincott, Philadelphia, 1984:711-712.
20. Neer CS. Fractures of the distal third of the clavicle with detachment of the coracoclavicular ligament in adults. *J Trauma* 1963;3:99-100.
21. Edwards DJ, Kavanagh TG, Flannery MC. Fractures of the distal clavicle: a case for fixation. *Injury* 1992;23:44-46.
22. Hill JM, McGuire MH, Crosby LA. Closed treatment of displaced middle-third fractures of the clavicle gives poor results. *J Bone Jt Surg Br* 1997;79(4):537-539.
23. Roberto Postacchini, Stefano Gumina, Pasquale Farsetti, Franco Postacchini: Long-term results of conservative management of midshaft clavicle fracture. *Int Orthop* 2010;34(5):731-736.

How to cite this article: Bhardwaj E, Khader FA. Functional outcome of fracture middle-third clavicle treated in tertiary institute. *Indian J Orthop Surg* 2019;5(1):10-14.