

Clinical signs of thyroid eye disease

Jagriti Rana¹, S. P. Singh², Mimansaa Agasti^{3,*}

¹Associate Professor, ²Professor, ³Senior Resident, Dept. of Ophthalmology, Motilal Nehru Medical College, Allahabad, Uttar Pradesh, India

***Corresponding Author: Mimansaa Agasti**

Email: obviouslymimansaa@gmail.com

Abstract

Thyroid Eye Disease (TED) or Thyroid Ophthalmopathy or Grave's Ophthalmopathy is the single most common cause of bilateral proptosis in adulthood. It is associated with orbital involvement in 25-50% of patients and 5-10% of patients may develop serious complications like compressive optic neuropathy improved motility and inflammation.

The characteristic clinical signs may include a combination of eyelid signs, lid lag, globe lag, proptosis, restrictive extraocular myopathy and optic neuropathy. Werner's classification is helpful in summarizing the clinical classification of Grave's Ophthalmopathy.

Various diseases such as myasthenia gravis, orbital myositis, CPEO etc mimic thyroid eye disease and its important to know how they can be differentiated.

Finally blood investigations and imaging studies are very helpful in endorsing the clinical signs and help one arrive at the diagnosis.

Since various medical and surgical management is amenable to us, establishing the correct diagnosis of TED is extremely important. This disease may have sight threatening complications, if not diagnosed on time, therefore, it is important to know the clinical signs of TED.

The management is conservative most of the times and a better understanding of the immunological pathogenesis may propel the medical management of the disease in a different direction.

Keywords: Proptosis, Restrictive myopathy, Thyroid ophthalmopathy.

Introduction

Thyroid Eye Disease (TED) or Thyroid Ophthalmopathy or Grave's Ophthalmopathy¹⁰ is the single most common cause of bilateral proptosis in adulthood. It is also the most common cause of unilateral proptosis in adults.¹

The disease is always bilateral, but at times, unilateral presentation may be because of an asymmetrical involvement of the two orbits. The axial proptosis in TED is referred to as 'Exophthalmos' and is associated with hyperthyroidism in 90-95% of the cases, although around 6% of the cases may have a euthyroid or a hypothyroid status.^{2,12,13}

It occurs in all ages, and races, has a predilection for females and is most common between the second and the sixth decades. This disfiguring and sight-threatening autoimmune disorder is associated with orbital involvement in 25-50% of patients and 5-10% of patients may develop serious complications like compressive optic neuropathy,^{14,15} improved motility and inflammation.

When the disease presents itself with the classical clinical signs of bilateral proptosis, diffuse goitre and signs and symptoms of hyperthyroidism, especially in an adult female, the diagnosis is not difficult. Even in cases with no symptoms of hyperthyroidism, lid lag and lid retraction are often present along with proptosis which may help one to clinch the diagnosis.¹⁰ But sometimes, in the congestive or progressive form of TED, a few symptoms and signs like lid swelling, chemosis and conjunctival hyperemia are superimposed on the basic signs of proptosis, lid lag and lid retraction which may mimic other orbital disorders and cause confusion. Indeed it is definitely not uncommon to misdiagnose it as conjunctivitis or allergy,³ in the active phase of the disease.

The signs usually begin shortly after the onset of hyperthyroidism and subside or slowly stabilize, either spontaneously or upon the control of hyperthyroidism. However in a few cases, the disease may progress unrelently.

Many a times, a patient with no symptoms presents to the ophthalmologist who may be alerted by the lid retraction and other signs and may refer the patient to an endocrinologist for thyroid assessment. Establishing the correct diagnosis is of paramount importance as not only it helps alleviate the signs and symptoms of TED but also goes a long way in preventing any vision threatening complications associated with the disease. We, in this article, have attempted to discuss the important signs of TED, which will help the ophthalmologist in making an early diagnosis.

Symptoms of Thyroid Eye Disease

The common symptoms are:

1. Redness in the eyes or lids
2. Puffy eyelids
3. Eyes seem to be wide open
4. Ocular pain
5. Change in the appearance of the eyes, particularly eyeball protrusion with eyelid swelling
6. Double vision
7. Inability to fully close the eyes
8. Visual loss
9. Dry eyes, irritation, foreign body sensation
10. Watering

Signs of Thyroid Eye Disease

The characteristic clinical signs may include a combination of eyelid retraction, lid lag, globe lag, proptosis, restrictive extraocular myopathy¹⁵ and optic neuropathy.^{2,4} In this regard, the Werner's classification is quite helpful as it easily summarizes the clinical classification of Grave's Ophthalmopathy.

Table 1: Werner's classification of grave's ophthalmopathy¹⁶

Classes*	Description
0	No signs or symptoms
1	Only signs(eyelid retraction)
2	Soft tissue periorbital swelling
3	Proptosis of eyes
4	Extraocular muscle involvement, diplopia
5	Corneal involvement, exposure
6	Sight loss, by optic nerve compromise

* Classes 0 and 1 are non-infiltrative disease.

Classes 2-6 are infiltrative disease

Although this classification provides a useful format of increasing severity, in reality, clinical signs, do not always progress in this sequence. The disease may manifest asymmetrically, as already discussed, and may undergo spontaneous exacerbations and remissions.

Class 0 represents subclinical disease without signs or symptoms, Class 1 includes signs of eyelid retraction and stare, Class 2 includes soft tissue edema and inflammation, Class 3 includes exophthalmos, Class 4 includes ocular motility, imbalance and diplopia from restrictive myopathy, Class 5 covers exposure keratopathy and Class 6 represents optic neuropathy with potential blindness. This classification is often referred to by the mnemonic "NO SPECS" based on the first letter of each sign in Werner's original table.

Grave's disease usually runs a progressive course for 3-5 years, then stabilises. Some of these clinical signs mandate discussion.

Lid Signs:¹⁰ Like lid retraction and lid lag (lagophthalmos), lid edema are frequently seen. This may be a result of direct involvement of levator palpebrae superioris due to orbitopathy or induced sensitization of Muller's muscle to circulating catecholamines resulting in a staring look.

Periorbital puffiness may be present resulting from vascular compression within the orbit and decreased lymphatic and venous drainage.

Exophthalmos:¹¹ Is a special term reserved to denote proptosis, very commonly seen in TED. Exophthalmos is almost always bilateral and usually relatively symmetrical. There is an increased resistance to retropulsion. The presence of lid retraction leads to corneal exposure and ulceration. The exophthalmos is a reflection of an increase in soft tissue mass within the bony orbit and may result from enlargement of the extraocular muscles from increased orbital fat volume⁴.

Restrictive Myopathy:¹⁵ Extraocular muscles are involved due to the lymphatic infiltration and fibrosis of the extraocular muscles.

Inferior rectus is most commonly involved, followed by medial and superior rectus. The patient may complain of a vertical diplopia. He may also complain of a feeling of a pulling sensation when they are seeing in a direction opposite to the restricted muscle.

An increased intraocular pressure of more than 8 mm Hg may be seen on gaze which is away from a restricted muscle.

Exposure Keratopathy:¹⁷ Exposure keratitis can result from either eyelid retraction, exophthalmos and a poor Bell's phenomenon. Dry eye is extremely common because of increased exposure due to lagophthalmos, disturbances in the tear film constitution and quantity. The patient may complain of foreign body sensation, dryness, itching etc. Superficial punctate keratitis and superior limbic keratitis may occur. Corneal ulcers may also occur.

Conjunctival Signs

1. Conjunctival chemosis may be seen.
2. Conjunctival injection may be seen over the rectus muscle insertions.

Compressive Optic Neuropathy:^{14,15,18} This occurs at the orbital apex by the enlarged muscles. This has a very likely association with superior rectus enlargement in the absence of exophthalmos. This compression results in a decreased visual acuity, colour loss, afferent pupillary defect and a visual field loss. The disc may appear as swollen, normal or atrophic.

Choroidal Folds: May be seen with thyroid ophthalmopathy.

Some other signs are:-

1. Vigouroux sign- sign of eyelid fullness
2. Stellwag's sign- 'staring look' (incomplete and infrequent blinking with widening of palpebral fissure.)
3. Grave's sign- resistance to pulling down the retracted upper lid
4. Mobius sign- failure to converge the eyeballs
5. Ballet sign- restriction of one or more extraocular muscles.
6. Joffroy's sign- absent creases in the forehead on superior gaze.
7. Dalrymple's sign- upper sclera is visible due to retraction of upper eyelids.
8. Von-Graefe's sign- upper eyelid lags behind the eyeball when the patient looks downward
9. *Pretibial edema and thyroid acropachy*- (which mimics clubbing) are some of the cutaneous manifestations of TED.⁷

The diagnosis is not easy in TED. Many a times, a patient having periorbital puffiness, conjunctival chemosis are misdiagnosed and treated along the lines of allergic conjunctivitis. It is indeed necessary that we differentiate between thyroid eye disease and other causes of periorbital edema. It will help us to know whether eyelid retraction and

restricted ocular motility is also present, which occurs in TED.

Differential Diagnosis: Since the signs of TED mimic the signs of some other diseases closely, it shall be wise to compare them.

- a. **Allergic Conjunctivitis:** itching and redness, along with a stringy discharge is seen in allergic conjunctivitis but typically, lid retraction, restrictive myopathy is absent.
- b. **Myasthenia Gravis:**¹⁷ In all patients of TED with exotropia, the possibility of concurrent Myasthenia Gravis should be considered. The presence of ptosis and extraocular muscle weakness which either fluctuates or does not conform to any pattern of ocular motor nerve paresis raises the suspicion of Myasthenia Gravis. Also, the diplopia usually fluctuates throughout the day.
- c. **Orbital Myositis:** Presentation is quite similar to TED but this is usually a unilateral condition.
- d. **Chronic Progressive External Ophthalmoplegia (CPEO):** The patients of CPEO exhibit initial ptosis along with limitation of ductions in all directions. The downward gaze may be spared until late in the disease. Also, these patients rarely complain of diplopia.
- e. **Diffuse Idiopathic Orbital Inflammation (Pseudotumor):** This disease has no systemic manifestations and is typically a unilateral condition. This responds dramatically to systemic steroids.
- f. **Orbital Cellulitis:** This is usually unilateral, and manifests with pain, lid edema, proptosis and associated with systemic features like malaise and fever. If the cavernous sinus is involved, headache, nausea, vomiting and even altered sensorium may be there.

A few other important conditions which can mimic TED are sarcoidosis, orbital tumours, etc.

The discussion of clinical signs of TED is incomplete without throwing some light on the blood investigations and imaging studies which are, indeed very helpful in endorsing the clinical signs and help arrive one at the diagnosis.

Blood: The combination of Serum T₃, T₄ (thyroxine), TSH (thyroid stimulating hormone) or serum TSH (thyrotropin) are highly sensitive and specific.

Serum TSH is low in hyperthyroidism and high in hypothyroidism.

In a patient of euthyroid eye disease, there may be an increased level of anti-thyroid antibodies and thyroid stimulating immunoglobulin (TS Ab).

The increased level of autoantibodies and thyroid – stimulating hormone receptor antibodies in a patient with signs of TED, helps to clinch the diagnosis.

In addition to these, thyroglobulin (Tg Ab) and thyroid peroxidase (TPO Ab) are both auto- immunoglobulin markers of TED. Out of these, Tg Ab is less prevalent and less useful than TPO Ab for prediction of thyroid dysfunction.⁹

Imaging Studies

CT Scan: This is often enough for establishing the diagnosis in conjunction with other features of TED.

Usually it is not necessary but may aid the diagnosis in those with atypical presentations, e.g non-axial globe proptosis, suspected optic neuropathy, unilateral cases etc or prior to bony decompression or divergent squint.

The typical finding on a CT scan are enlarged extraocular muscles with sparing of the tendons.⁶ This will be observed in both the eyes. Even those presenting with a unilateral presentation may show involvement of the muscles of the other eye, albeit asymmetrically.

MRI

Here, as in the case of CT scan, both axial and coronal sections are asked for.

It is very sensitive for the optic nerve and shows apical crowding around it.

Extraocular muscles are also visualized better on it.

1. On MRI, the T1 is iso-intense and the T2 is intense to slightly hyperintense to muscle.
2. Extraocular muscles are enlarged with tendinous sparing.
3. In marked proptosis, even straightening of the optic nerve can be seen.

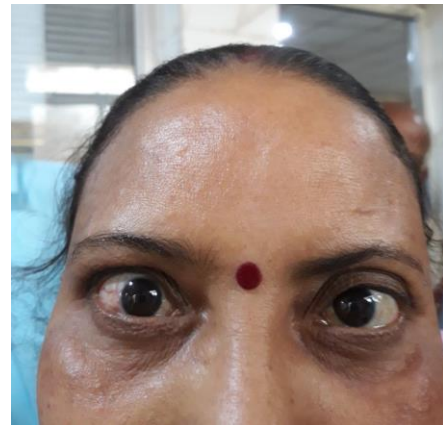

Fig. 1



Fig. 2

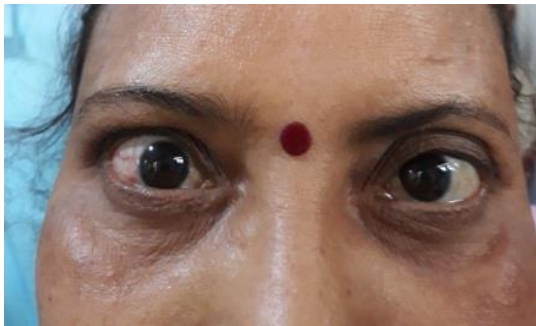

Fig. 3

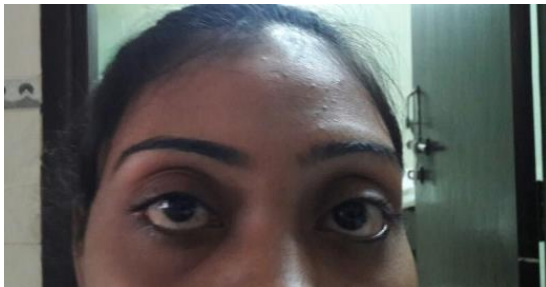


Fig. 4

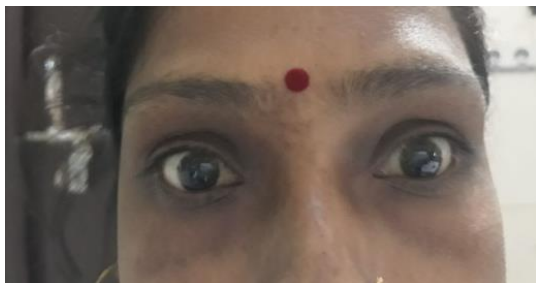

Fig. 5

Conclusion

Since various medical and surgical management is amenable to us, establishing the correct diagnosis of TED is extremely important. This disease may have sight threatening complications, if not diagnosed on time, therefore, it is important to know the clinical signs of TED. The management is conservative most of the times and incomplete without referring the patient to an endocrinologist.

In the future, a better understanding of the immunological pathogenesis may propel the medical management of the disease in a different direction.

The disease closely mimics various other orbital disorders but with the help of investigations (both blood and imaging) can be diagnosed properly.

Conflict of Interest: None.

References

1. Peyman GA, Sanders DR, Goldberg MF: Principles and Practice of Ophthalmology: Vol III, W.B, Sander's Company (Jaypee Brothers 1987), Part 9, Chapter 32, pg 2174-2175.
2. Grave's Ophthalmopathy: Basic and Clinical Science Course. *Am Acad Ophthalmol* 2002;7:44-45.
3. Mac Ewen C. Know how to diagnose and manage thyroid eye disease. G Poline, 14 March 2012. Available online at www.gponline.com/Clinical/article/1120742/expert-opinion-diagnosing-thyroid-eye-disease/ [accessed 3 February 2015]
4. Steel HW, Potts MJ, Thyroid Eye Disease. *Oxford Text Book of Ophthalmology* 1999;722-730.
5. Petros Perros. Management of patients with Grave's orbitopathy: initial assessment, management outside specialised centres and referral pathways. *Clin Med* 2015;15(2):173-178.
6. Yanoff M, Duker Jay S. *Ophthalmology* Fourth Edition. Elsevier Saunders Co; 2014;Ch. 9.18:946, 1327.
7. Shah Y. Thyroid Ophthalmopathy. *Supplement to JAPI* 2011;59:60-65.
8. Boboridis K, Perros P. General management plan. In: Weirsinga WM, Kahaly GJ, eds, *Grave's ophthalmopathy: A multi-disciplinary approach*. Basel: Karger 2008:88-95.
9. Mc Lachlan S.M, Rapoport B, 2004. Why measure thyroglobulin autoantibodies rather than thyroid peroxidase autoantibodies? *Thyroid* 14(7):510-520.
10. Colm McAlinden.; An overview of thyroid eye disease. *Eye Vis (Lond)* 2014;1:9.
11. Graves RJ; *Clinical Lectures. London Med Surg J* 1835;7:516-517.
12. Maheshwari R, Weis E. Thyroid associated orbitopathy. *Indian J Ophthalmol* 2012;60(2):87-93.
13. Stan MN, Bahn RS.; Risk factors for development or deterioration of Graves' ophthalmopathy. *Thyroid* 2010;20(7):777-83
14. *Oxford Handbook of Ophthalmology*. Second edition.: Oxford University Press; Denniston AKO, Murray PI: 2009.
15. Bartley GB, Fatourech V, Kadmas EF, Jacobsen SJ, Ilstrup DM, Garrity JA, Gorman CA. Clinical features of Graves' ophthalmopathy in an incidence cohort. *Am J Ophthalmol* 1996;121:284-290. doi: 10.1016/S0002-9394(14)70276-4.
16. Werner SC. Classification of the eye changes of Graves' disease. *Am J Ophthalmol* 1969;68:646-648.
17. Wiersinga WM, Kahaly GJ. 2007. *Graves orbitopathy: A multidisciplinary approach*. Basel: Karger;
18. *Management of Eyelid Malposition in Thyroid Eye Disease: Smith and Nesi's Ophthalmic Plastic and Reconstructive Surgery* pp 1185-1211; *Smith and Nesi's Ophthalmic Plastic and Reconstructive Surgery* pp 1185-1211: Springer Link : First online 16 December 2011.
19. Sikder S, Weinberg RS. Thyroid eye disease: pathogenesis and treatment. *Ophthalmologica* 2010;224(4):199-203.
20. Verity DH, Rose GE.; Acute thyroid eye disease (TED): principles of medical and surgical management. *Eye (Lond)* 2013;27(3):308-319.
21. Yu P, Liu S, Zhou X, Huang T, Li Y, Wang H, Yuan G. Thyroid-associated orbitopathy in patients with thyroid carcinoma: A case report of 5 cases. *Med (Baltimore)* 2017;96(47):e8768.
22. Reddy SV, Jain A, Yadav SB, Sharma K, Bhatia E.; Prevalence of Graves' ophthalmopathy in patients with Graves' disease presenting to a referral centre in north India. *Indian J Med Res* 2014;139(1):99-104.
23. Feman SS.; Diabetes and thyroid-related eye disease. *Curr Opin Ophthalmol* 1995;6(6):64-69.
24. Leray B, Imbert P, Thouvenin D, Boutault F, Caron P Diagnosis and treatment of dysthyroid orbitopathy: a multidisciplinary disease. *J Fr Optalmol* 2013;36(10):874-885.
25. Lee HB, Rodgers IR, Woog JJ. Evaluation and management of Graves' orbitopathy. *Otolaryngol Clin North Am* 2006;39(5):923-942.

26. Perros P, Dayan CM, Dickinson AJ, Ezra D, Estcourt S, Foley P, Hickey J, Lazarus JH, MacEwen CJ, McLaren J, Rose GE, Uddin J, Vaidya B. Management of patients with Graves' orbitopathy: initial assessment, management outside specialised centres and referral pathways. *Clin Med (Lond)* 2015;15(2):173-8
27. Piantanida E, Tanda ML, Lai A, Sassi L, Bartalena L.; Prevalence and natural history of Graves' orbitopathy in the XXI century. *J Endocrinol Invest* 2013;36(6):444-449.
28. Laurberg P, Berman DC, Bülow Pedersen I, Andersen S, Carlé A. Incidence and clinical presentation of moderate to severe graves' orbitopathy in a Danish population before and after iodine fortification of salt. *J Clin Endocrinol Metab* 2012;97(7):2325-2332.
29. Tanda ML, Piantanida E, Liparulo L, Veronesi G, Lai A, Sassi L, Pariani N, Gallo D, Azzolini C, Ferrario M, Bartalena L. Prevalence and natural history of Graves' orbitopathy in a large series of patients with newly diagnosed graves' hyperthyroidism seen at a single center. *J Clin Endocrinol Metab* 2013;98(4):1443-1449.
30. Lim SL, Lim AK, Mumtaz M, Hussein E, Wan Bebakar WM, Khir AS. Prevalence, risk factors, and clinical features of thyroid-associated ophthalmopathy in multiethnic Malaysian patients with Graves' disease. *Thyroid* 2008;18(12):1297-301.
31. Park SW, Khwarg SI, Kim N, Lee MJ, Choung HK. Acquired lower eyelid epiblepharon in thyroid-associated ophthalmopathy of Koreans. *Ophthalmol* 2012 Feb;119(2):390-395.
32. Gould DJ, Roth FS, Soparkar CN. The diagnosis and treatment of thyroid-associated ophthalmopathy. *Aesthetic Plast Surg* 2012;36(3):638-648.

How to cite this article: Rana J, Singh SP, Agasti M. Clinical signs of thyroid eye disease. *Indian J Clin Exp Ophthalmol* 2019;5(1):3-7.