



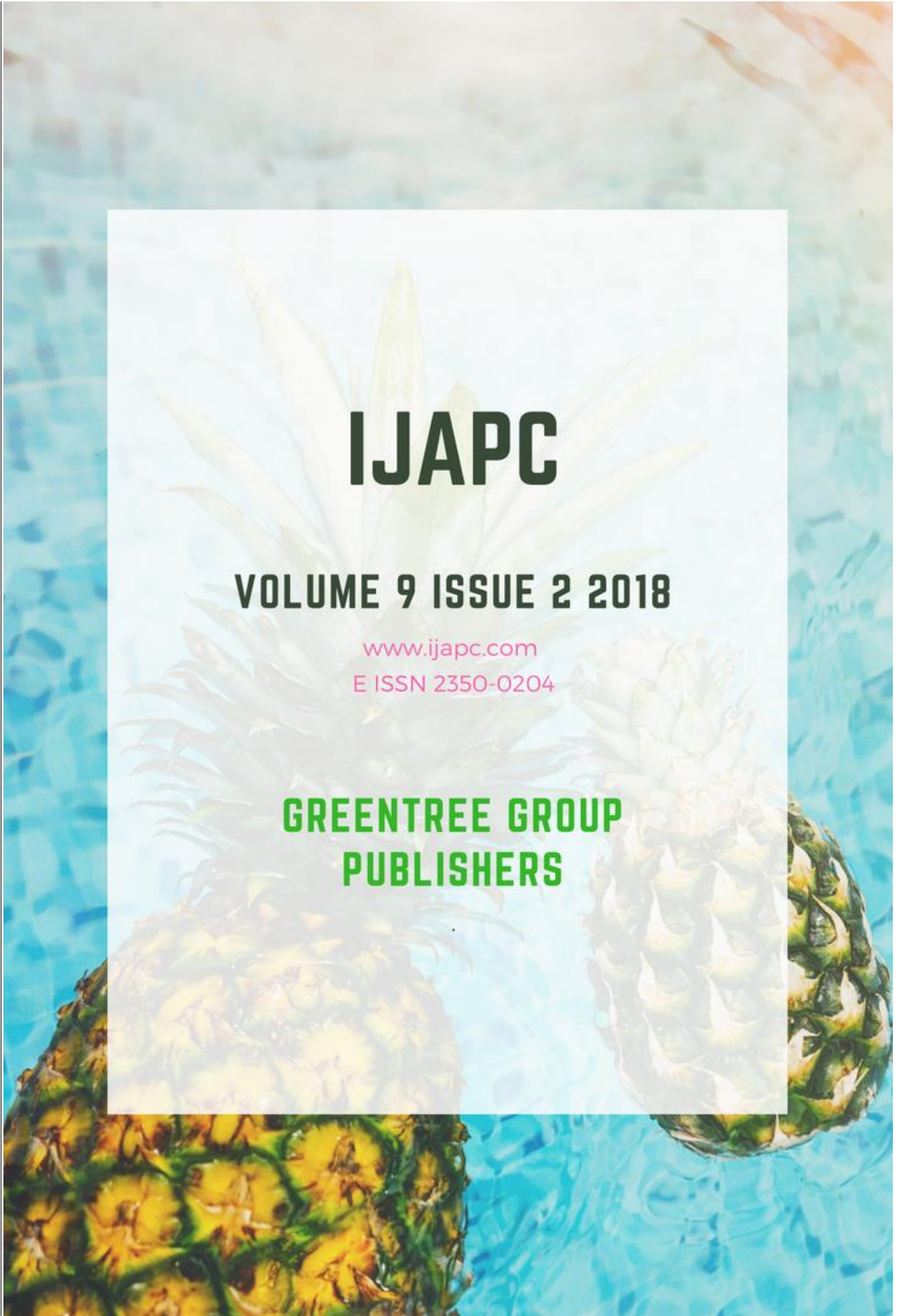
IJAPC

VOLUME 9 ISSUE 2 2018

www.ijapc.com

E ISSN 2350-0204

**GREENTREE GROUP
PUBLISHERS**





Ayurvedic Enema Therapy in the Management of Thromboangitis Obliterans (TAO) - A Case Study

Madan Bhandari^{1*}, Prasanna N. Rao², Gopikrishna B J³ and Suhas Kumar Shetty⁴

¹⁻⁴Department of Shalya Tantra,,Sri Dharmasthala Manjunatheshwara College of Ayurveda & Hospital, Hassan, Karnataka, India

ABSTRACT

Thromboangitis Obliterans (TAO) is a non-atherosclerotic inflammatory disorder of unknown etiology that affects small and medium-sized vessels of the extremities and has a strong association with smoking. The clinical criteria include: age under 45 years; current or recent history of tobacco use; presence of distal-extremity ischemia indicated by claudication, pain at rest, ischemic ulcers or gangrenes and documented by non-invasive vascular testing. A diagnosed case of TAO with gangrene on right great toe with post lumbar sympathectomy status was admitted for severe pain on right lower limb. Ayurvedic enema therapy (Manjisthadi Kshara Basti) for 30 days (Karma Basti) was given for the patient who resulted in significant clinical improvement on the pain and subsequent healing of ulcer. Oil based enema made up *Rubia cordifolia* (Manjisthadi taila) and kvath(decoction) based enema with manjisthadi kshara basti was executed here on alternate days and had shown significant results on the pain, claudication distance etc.

KEYWORDS

Thromboangitis Obliterans, Manjisthadi Kshara Basti, Karma Basti, Anubhuta Yoga



Greentree Group Publishers

[Received 21/06/18](#) [Accepted 23/07/18](#) [Published 10/09/18](#)



INTRODUCTION

Thromboangitis Obliterans (TAO), also known as Buerger's disease is an inflammatory disorder of vessels where inflammatory endarteritis hampers the proper blood supply. The condition has strong association with tobacco use¹. The onset of Buerger's disease occurs between 40 and 45 years of age, and men are most commonly affected. It begins with ischemia of the distal small vessels of the arms, legs, hands and feet. Involvement of the large arteries is unusual and rarely occurs in the absence of occlusive disease of the small vessels².

In modern medicine, analgesics, vasodilators, anti-platelet aggregators are some choice for conservative management³. Lumbar Sympathectomy can be used for short-term pain relief and to promote ulcer healing in patients with Buerger's disease but has no long-term benefit⁴. The symptoms of TAO can be well correlated with Gambhira Vatarakta⁵ in Ayurveda. Alkaline Enema (Kshara Basti)⁶ is explained by Chakradatta and decoction of *Rubia cordifolia* and other ingredients (Manjisthadi Kvath)⁷ is explained by Sarangadhara for Vatarakta. Alkaline enema of *Rubia Cordifolia* and other ingredients (Manjisthadi Kshara Basti) is an Anubhuta Yoga (established through

empirical use) and is effective in management of Srotavarodha (blocked channels). Based on the above mentioned views Manjisthadi Kshara Basti was considered for a case of Thromboangitis Obliterans (TAO).

CASE STUDY

A male patient of age 29 years, Coolie by occupation, from Hassan, Karnataka came to an Ayurveda Hospital with the complaint of pain and burning sensation on right lower limb for 4 months associated with an ulcer on right great toe with complete loss of nail bed for 3 months.

History of Present Illness

According to the patient he was apparently healthy 4 months back then he gradually developed pain on right calf region. The pain was cramp like, moderate to severe in intensity, initially intermittent in nature and aggravated on exposure to cold and physical activity.

Gradually, he developed swelling and reddish discoloration on right great toe associated with blackish discoloration on fore foot. After a week, there was a crack on right toe and the nail was completely peeled off at night leaving an ulcer [Fig:1].

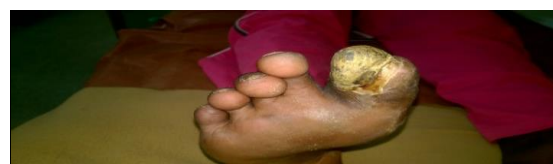

Fig 1 Before treatment ulcer of the patient



History of Past Illness

No History of Hypertension, Diabetes Mellitus, Pulmonary tuberculosis.

Treatment History

For the aforementioned complaints, he visited nearby Medical College where a General Surgeon diagnosed him of Thromboangitis Obliterans (TAO) on Right Lower Limb and advised anti-platelet aggregators and analgesics. As the pain and ulcer was not reduced with the medicines he re-visited the hospital after 2 weeks of treatment. Then he was advised for Right Lumbar Sympathectomy following that.

After Lumbar Sympathectomy, blackish discolouration on the fore foot got reduced but the pain and ulcer remained the same. Later, he was referred to Vascular Surgeon at Bangalore. At Bangalore, the vascular surgeon added some medications and counselled him to be prepared for Below Knee Amputation if the condition remained the same. The patient continuously took the medicines for 2 weeks but the pain was not desirably subsided. As, the patient was not ready for amputation he left the follow-up and came for consultation in our hospital.

Personal History

Appetite – Decreased, Bowel – Regular, Micturition – Normal, Sleep – Disturbed due to pain

Habits: Chronic Smoker for 9 years, 1 pack per day (25 cigarettes per pack), Mixed beedi and cigarette

Examination of Patient

Blood Pressure – 130/80 mm of Hg on supine position, Pulse – 76bpm, regular
Pallor-Icterus-Lymphadenopathy-
Cyanosis-Clubbing-Oedema-Dehydration}
Not present

Respiratory System: Bilateral equal air entry, Normal Vesicular Breath Sound

Per Abdomen: Soft, nontender, no organomegaly

Cardiovascular System: S1S2 sound head, No murmurs

Central Nervous System: Oriented to time, place and person

Local Examination:

-Inspection: An ulcer on right great toe, dry and hard on consistency with nail bed peeled off, loss of hairs [Fig:1]

-Palpation: Right lower limb-Decreased local temperature, Popliteal artery, Posterior Tibial Artery, Anterior Tibial Artery, Dorsalis pedis Artery not palpable

-Gait: Limping gait with Intermittent Claudication, Claudication distance-30 metres

Investigations

Arterial Doppler of Right Lower Limb: Near complete stenosis (>90%) of distal popliteal artery causing significant reduced



flow in posterior tibial artery and distal popliteal artery.

Diagnosis

Thromboangitis Obliterans (TAO) with dry gangrene on Right great toe/ S/P Right Lumbar Sympathectomy

Treatment

The patient was advised for Ayurvedic Enema for 30 days (Karma Basti) with alternate day only medicated oil enema (Anuvasana Basti of Manjisthadi Taila) and medicinal decoction enema (Niruha Basti) of Manjisthadi Kwatha and other ingredients listed below in table 1:

Table 1 Ingredients of Manjisthadi Kshara Basti

Ingredients	Latin/English name	Amount
SaindhavaLavana	Rock Salt	5gm
ManjisthadiTaila	Oil of <i>Rubiaccordifolia</i> and other ingredients	60ml
Madhu	Honey	80 ml
ManjisthadiKwath	Decoction of <i>Rubiaccordifolia</i> and other ingredients	100ml
Gomutra	Cow's urine	100 ml
Kanji	Medicinal rice gruel	100ml

Dressing with Jatyadi taila (Herbal oil, where jasmine is chief ingredient) on the ulcer once daily.

OBSERVATIONS

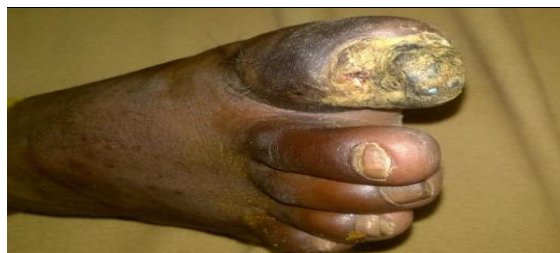

Fig 2 After treatment healed ulcer

Table 2 Assessment of BT and AT on different parameters

Parameters	Before Treatment	After Treatment
Pain and Burning sensation on Right lower limb	Visual Analogue Scale- 8 points	Visual Analogue Scale-3 points
Claudication distance	30 metres	500 metres
Ulcer	Purulent discharge present	Healed
Skin Discolouration	Present on the right fore foot	Reduced
Sleep	Disturbed due to severe pain	Sound Sleep
Size of ulcer	3x1x0.5 cm with purulent discharge[Fig:1]	Healed completely[Fig:2]

DISCUSSION

TAO is one of the most painful vascular diseases. The long term management of it is challenging for the modern surgeons too. In the aforementioned case the patient consulted various General Surgeons and Vascular Surgeons and continuously took the medications that were prescribed for him. He was advised for Right Lumbar Sympathectomy and was operated which was even unable to relieve the pain of patient.

The sign and symptoms of TAO can be well correlated with GambhiraVatarakta in Ayurveda. In Vatarakta, due to the diet and lifestyle aggravating the Rakta (blood), the Rakta gets vitiated and it does the Avarana (covering) of Vata. VataPrakopa (aggravation) happens and it gets localised



on different parts of the body manifesting the signs and symptoms of aggravated Vata like pain etc. In Ayurveda, Manjistha (*Rubia cordifolia*) is a renowned Rakta Prasadaka (blood purifier), Tridosahara (balancing the 3 Doshas) and Srotosodhaka (cleansing the channels). So, use of Manjisthadi Kvath (decoction) and Manjisthadi Taila (oil) purifies the Rakta (blood), pacifies the Vata and makes the proper flow inside the channels (Srotosodhaka). Kshara Basti (Alkaline Enema) has the fast spreading activity which helps to clean the peripheral vascular channels. Hence, the combination Basti is very effective on Peripheral Vascular Diseases like TAO.

Conclusion

Thromboangitis obliterans (TAO) is a painful disease of mainly medium sized blood vessels. It is progressive and associated with severe pain according to ischaemic changes. It is directly associated with tobacco smoking.

An endeavour was made to manage a case of TAO with Ayurvedic treatment which was previously advised for Below Knee Amputation. The symptoms of TAO can be well correlated with Gambhira Vatarakta in Ayurveda. Ayurvedic Enema (Manjisthadi Kshara Basti) is an Anubhuta Yoga (established by empirical use) showing promising results in TAO. Alkaline Enema

(Kshara Basti) is mentioned by Chakradatta and Decoction of *Rubia cordifolia* (Manjisthadi Kvath) is mentioned by Sarangadhara. *Rubia cordifolia* (Manjistha) is renowned blood purifier (Raktasodhaka), channel cleansing (Srotosodhaka) and the Alkaline Enema (Kshara Basti) removes the Avarana of Vata (Blocking activity of Vata).

Hence, TAO can be successfully managed by Ayurvedic Enema therapy (Manjisthadi Kshara Basti).



REFERENCES

1. Papa MZ, Adar R. A critical look at thromboangiitis obliterans (Buerger's disease). *VascSurg* 1992;5:1-18.
2. Shionoya S, Ban I, Nakata Y, Matsubara J, Hirai M, Kawai S: Involvement of the iliac artery in Buerger's disease (pathogenesis and arterial reconstruction). *J CardiovascSurg (Torino)* 1978, 19:69-76.
3. F. Charles Brunicaudi et al. Schwartz's principles of surgery, 8th ed. McGraw- Hill Companies, Inc, 1969, page 792-793.
4. Lau H, Cheng SW: Buerger's disease in Hong Kong: a review of 89 cases. *Aust N Z J Surg* 1997, 67:264-269.
5. Agnivesha, CharakaSamhita, Acharya Yadavji Trikamji, Chaukhamba Sanskrit Sansthan, Varanasi, 2004, page 628.
6. Chakradatta, Indradev Tripathi, Chaukhamba Sanskrit Sansthan, Varanasi, 2005, page 455.
7. Sharangadhar Samhita, Brahmanand Tripathi, Chaukhamba Surbharti Prakashan, Varanasi, page 153.