

Orbital aspergillosis masquerading as lymphoma diagnosed by cytology – A case report

Amita K^{1,*}, Amita Kumari², Vijay Shankar S³, Sanjay M⁴

¹Professor, ²Post Graduate Student, ³Professor and HOD, ⁴Associate Professor, Dept. of Pathology, Adichunchanagiri Institute of Medical Sciences, Mandya, Karnataka, India

***Corresponding Author: Amita K**

Email: dramitay@gmail.com

Received: 10th July, 2017

Accepted: 13th August, 2018

Abstract

Orbital aspergillosis is rare, more so in immunocompetent individuals. Fine needle aspiration cytology plays an important role in diagnosis of mass lesions in orbit, in spite of the fright of hemorrhagic episodes. We herein report a rare case of aspergillosis presenting as a mass lesion in orbit in a young immunocompetent female. Clinical and radiological features favored a malignant process. Fine needle aspiration cytology (FNAC) followed by culture assisted in accurate diagnosis.

Keywords: Aspergillosis, FNAC, Cytology, Orbit.

Introduction

Aspergillus species are ubiquitous in nature. Pathological involvement typically occurs in patients with depressed immune system, but may involve immunocompetent host infrequently.¹ It commonly occurs in diabetics and patients on corticosteroids. Orbital aspergillosis is a rare entity in immunocompetent individuals. Only 35 cases of orbital aspergillosis have been reported over a period of 15 years.²

Mass lesions, proptosis and diminution of vision are the usual presenting complaints. Lesions present as diagnostic challenge to physicians and radiologist as they mimic malignancy.³

Imaging modalities such as x-ray, magnetic resonance imaging and computed tomography scan (CT) can help to establish diagnosis of fungal infections. Although fine needle aspiration cytology (FNAC) has been used as an initial investigation procedure in cases of orbital infection and masses, its role is limited in cases of deep seated orbital lesions due to risk of retro bulbar hemorrhages.

We here in report a case of orbital aspergillosis in a young immunocompetent female and emphasize the role of FNAC in the diagnosis of fungal infections.

Case Report

A 30 years female patient presented to ophthalmology department with chief complaints of diminution of vision, pain and mass in the left eye of one month duration. This

complaint was present since one year and was on and off in nature. On examination tender swelling was noted on the left eye measuring 3× 2cms. There was no history of fever, vomiting, weight loss, night sweats, swelling at other sites or loss of appetite. There was no history of diabetes, hypertension, tuberculosis and any history of drug intake. On examination swelling was noted in the left orbital region. There was drooping of the left eye and congestion was seen in the conjunctiva. Swelling was 3 x 2 cm. The right eye was normal. There was no evidence of any lymphadenopathy or hepatosplenomegaly, CT scan showed mass lesion with infiltration in surrounding structure. Peripheral smear showed pancytopenia and bone marrow biopsy revealed erythroid hyperplasia with megaloblastic maturation. Biochemistry, serology and urine analysis were within normal limits. Clinical and radiological provisional diagnosis of lymphoma was made. FNAC of the orbital mass was advised for further evaluation.

FNAC was done by standard technique. At FNAC pus like material was aspirated. Microscopy showed numerous neutrophilic debris, necrotic patches, foamy histiocytes, foreign body giant cell reaction, epithelioid cell granulomas. (Fig. 1 A & B) A careful search revealed fungal hyphae in singles and at places forming entangled masses. (Fig. 2 A & B) The hyphae were thin, septate and showed acute angled branching. (Fig. 2 C & D) Culture in sabarouds medium showed colonies of aspergillus fumigates.

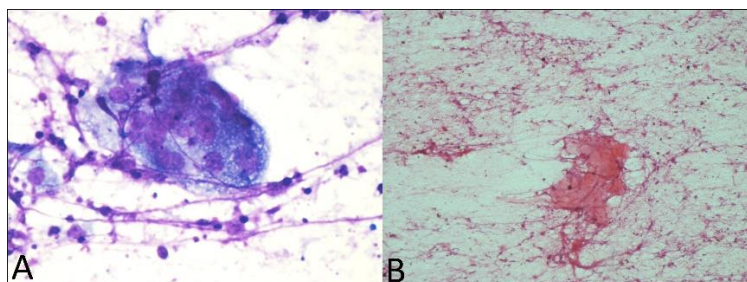


Fig. 1

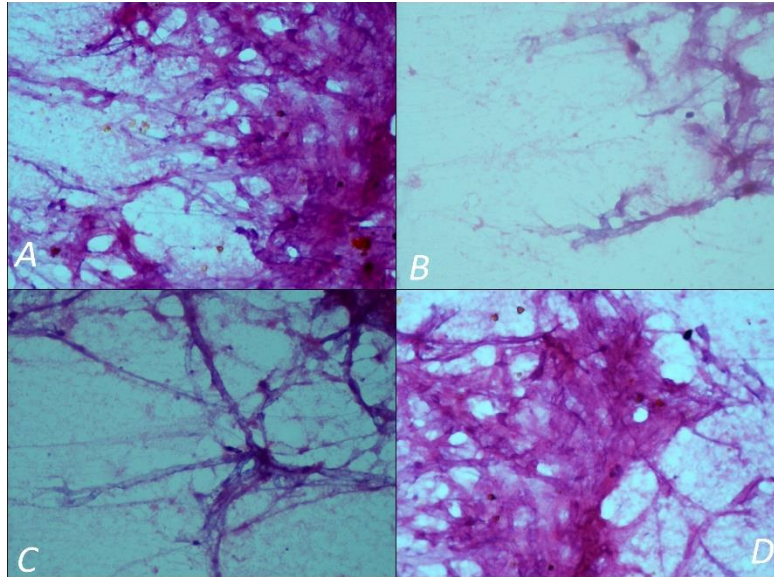


Fig. 2

Discussion

Aspergillosis is a fungal infection caused by aspergillus species. More than 300 odd species of aspergillus have been identified, in which aspergillus fumigatus is the major pathogen. These species are highly pathogenic for birds and occasionally cause invasive disease in human beings. They tend to habitat in soil, dust and spores and are ubiquitous in nature.⁴

Aspergillosis mainly occur in people with underlying illness such as diabetes, tuberculosis, chronic obstructing pulmonary disease, patient undergoing hematopoietic stem cell transplantation and patient on chemotherapy, but it can affect immunocompetant individuals also. Fungal granulomas has been reported in immunocompetant individuals of Pakistan, Sudan and India. They are usually not seen in the western worlds.⁵

Mode of entry of aspergillosis include respiratory tract, cornea, infected and damaged wounds. Inhaled spores provokes hypersensitivity reaction and cause allergic bronchopulmonary aspergillosis and is associated with increase in serum IgE levels. In Aspergilloma fungal ball grow within lung cavity in case of old tuberculosis and bronchiectasis. Superficial infection involves otomycosis, mycotic keratitis and nasal sinuses.⁶

In head and neck primarily aspergillosis affects nasal cavity and paranasal sinuses. Fungal infection of orbit by aspergillus species is rare entity. Only 35 cases of orbital aspergillosis were reported over a periods of 15 years.

Fungal infections of orbit can be primarily orbital or sino-orbital with and without intracranial involvement. Patients with fungal infection of orbit can be present with pain, proptosis, nasolacrimal duct obstruction, mass and diminution of vision. At times these patients present as infiltrating lesion and mimic as malignancy. Clinical features of orbital aspergillosis are highly variable leading to misdiagnosis and inappropriate management. In a series of 35 cases of orbital aspergillosis occurring in immunocompetant

individuals, proptosis and mass lesion were the most common presenting complaints. Infiltrative bone destruction was noted in majority of the cases. Histopathology and culture was the prime mode of diagnosis in these cases.

Other common orbital fungal infections are mucormycosis caused by fungus in the order Mucorales, of which Rhizopus species is the most common. Rhino-orbital-cerebral zygomycosis occurs almost exclusively in the immunocompromised host. Approximately 60–80% of cases occur in diabetic patients with ketoacidosis. The hyphal forms of mucor are aspetate, broad and obtuse angled branching as compared to aspergillus which show thin 3 to 6 micron, septate and acute angle branching.⁷ Several diagnostic modalities like imaging, serology, culture, ultrasonography & CT scan have been proposed and used for diagnosis of OA, however nothing short of tissue diagnosis can aid in accurate diagnosis.

FNAC has an important role in mass lesions of orbit, especially in differentiating infectious from neoplastic and benign from malignant lesions. It is advised in atypical presentations, where a coherent diagnosis between clinical and radiologic findings is not possible. Fungal infection of the orbital region very commonly mimics a neoplastic process clinically.⁸ There is an extreme apprehension when a call for FNAC of ocular lesions is made. The reason being the fear of retro orbital hemorrhage.⁹ There are few case reports describing role of FNAC is initial diagnosis of aspergillus involvement in orbital region. Sreelaksmi et al reported two cases of orbital and periorbital aspergillosis which were diagnosed by FNAC.¹⁰ Reena Das et al, in their study involving 26 cases of fungal infections confirmed FNAC as a rapid test in definitive diagnosis in union with culture. The spectrum of fungus was wide with aspergillus being the most commonly encountered entity.¹¹ Similar findings were observed by Gochhait D et al who studied 125 cases of fungal infections initially diagnosed by FNAC. At cytology the morphologic smear pattern observed in fungal

infections include foreign body giant cells, foamy macrophages and necrosis. Multinucleate giant cells outnumbering the epithelioid cell granulomas and predominance of eosinophils are clues for the cytologist to search for a fungus.¹²

Though culture is a gold standard, colonies grow after 48hrs but longer period may be required before characteristically morphological features develop. Furthermore, aspergillus species are ubiquitous and hence fungal colonies may contaminate cultures. Due to these limitations, cytomorphology plays a major role in an accurate diagnosis.⁷

In our case, young immunocompetent patient who was suspected to harbor malignancy on clinical and radiological grounds, however a diagnosis of aspergillosis on FNAC averted a surgical procedure. Patient responded well to Amphotericin B which is the conventional mode of treatment.

Conclusion

Aspergillosis can present as a destructive mass lesion of orbit and hence truant a malignant process. FNAC is a powerful tool for diagnosis of mass lesions and can surmount the need for a surgical procedure if an infective pathology is established.

Conflict of Interest: None.

References

1. Fuqua TH, Sittitavornwong S, Knoll M, Said-Al-Naief NJ. Primary invasive oral aspergillosis: an updated literature review. *Oral Maxillofac Surg* 2010;68(10):2557-2563.
2. Mody KH, Ali MJ, Vemuganti GK, Nalamada S, Naik MN1, Honavar SG. Orbital aspergillosis in immunocompetent patients *Br J Ophthalmol* 2014;98:1379-1384.
3. Singhal N, Raghubanshi G, Handa U, Punia RP, Singhal S. Fine needle aspiration cytology: A useful technique for diagnosis of invasive fungalrhinosinusitis. *Head and Neck Pathol* 2013;7:236-240.
4. Ananthanarayan and Paniker. Textbook of microbiology In: Reba Knungo editors. Systemic and opportunistic mycosis. 10th ed. Hyderabad: University press;2013,609-624.
5. Lackner A, Stammberger H, Buzina W, Freudenschuss K, Panzitt T, Schosteritsch, et al. Fungi: a normal content of human nasal mucus. *Am J Rhinol* 2005;19:125-129.
6. Afghani T, Mansoor H, Syed AN. Serum IgE Levels: An Effective Diagnostic Tool for Evaluation and Monitoring of Orbital Fungal Granuloma. *J Coll Physicians Surg Pak* 2015;25:671-674.
7. Kumar Behera S, Patro M, Mishra D, Bal A, Behera B, Sahoo S. Fine needle aspiration in aspergilloma of frontal sinus: a case report. *Acta Cytol* 2008;52:500-504.
8. Levin LA, Avery R, Shore JW, Woog JJ, Baker S. The spectrum of orbital Aspergillosis: a clinicopathologic review. *Surv Ophthalmol* 1996;41:142-154
9. Vemuganti G K. Inflammatory and non-neoplastic lesions of eyelids, eyeball and orbit. *J Cytol* 2007;24:26-30.
10. Kuruba SL, Prabhakaran VC, Nagarajappa AH, Biligi DS. Orbital aspergillus infection diagnosed by FNAC. *Diagn Cytopathol* 2011;39:523-526.
11. Das R, Dey P, Chakrabarti A, Ray P. Fine-needle aspiration biopsy in fungal infections. *Diagn Cytopathol* 1997;16:31-34.
12. Gochhait D, Dey P, Rajwanshi A, Nijhawan R, Radhika S, Gupta N. Spectrum of fungal and parasitic infections on fine needle aspiration cytology. *Diagn Cytopathol* 2015;43:450-55.

How to cite this article: Amita K, Kumari A, Vijay SS, Sanjay M. Orbital aspergillosis masquerading as lymphoma diagnosed by cytology – A case report. *Indian J Pathol Oncol* 2019;6(1):148-150.