

# Clinicopathological and immunohistochemical profile of poorly differentiated neoplasms of stomach and intestine

T. Rajeswari<sup>1</sup>, V. Rajalakshmi<sup>2,\*</sup>

<sup>1</sup>Assistant Professor, <sup>2</sup>Professor, Dept. of Pathology, ESIC Medical College & PGIMSR, Chennai, Tamil Nadu, India

\* Corresponding Author: V. Rajalakshmi

Email: raji\_path@rediffmail.com

Received: 29<sup>th</sup> July, 2018

Accepted: 28<sup>th</sup> August, 2018

## Abstract

**Introduction:** The aim of this study was to review the clinicopathological and immunohistochemical features of poorly differentiated neoplasms of gastric and intestinal region, reported in a tertiary care hospital, for a period of two years. Among the total of 454 cases of gastrointestinal malignancies, 60 cases were poorly differentiated malignancies (PDM) of stomach and intestine and were included in the study. Immunohistochemical analysis was done in all cases with carcinoembryonic antigen (CEA), CD 20, synaptophysin and chromogranin A. Results were analysed, of the 60 cases of poorly differentiated malignancies of gastric and intestinal region, 46 cases were poorly differentiated adenocarcinomas (PDAC), 12 cases were non-Hodgkins lymphomas (NHL) and 2 cases were neuroendocrine carcinomas (NEC).

**Keywords:** Poorly differentiated malignancies, Carcinoembryonic antigen, CD 20, Poorly differentiated adenocarcinomas, Non-Hodgkins lymphomas, Neuroendocrine carcinomas.

## Introduction

The gastrointestinal tract is a remarkably dynamic organ system with complex secretory, absorptive and motility functions. Furthermore, the mucosal surface is characterised by a very rapid turnover of the epithelial cells, creating inherently the setting for a variety of neoplastic disorders.

Gastrointestinal malignancies include a wide variety of tumors. In the list of commonly occurring malignancies, gastrointestinal tumors are definitely need to be mentioned at an unavoidable position. Patients are usually seeking medical advice after a long period of time, since the disease has actually started, as there are no notable symptoms in the early period. As diagnosis is based on the biopsy material obtained by endoscopy guided procedure which are usually smaller and especially at situations when the size of biopsy specimens are very tiny, the importance of immunohistochemistry (IHC) becomes very critical. Almost each and every type of gastrointestinal malignancies have near specifically identifiable immunohistochemical signatures, which helps in appropriate diagnoses and there by very useful for optimum treatment procedures.

Histopathological diagnosis, tumor classification and identification of histogenesis of metastases of unknown or uncertain primary tumors are considered to be the most important responsibilities of histopathologists. At present in addition to the traditional light microscopy, there is a list of other informative methods that support histopathologists in their work such as immunohistochemistry and molecular diagnosis.

Immunohistochemistry, is a method, the one which microscopically recognizes cellular contents by using antibodies that are specific, has very much improved the field of surgical pathology by empowering the hematoxylin and eosin staining.<sup>1</sup> In the diagnosis of the suspected poorly

differentiated malignancies and tumors of unknown origin, IHC is very much useful in detecting the origin of the tumor at the cellular level, with the help of antibodies that are specific to tissues. This enables the pathologists to diagnose the tumors accurately. Results of the immunohistochemical methods should be studied and analysed, based on the light microscopic hematoxylin and eosin stained sections. Immunohistochemistry gives important and useful information regarding the behaviour of the tumor, its invasive and metastatic nature.

In the past 20 years immunohistochemistry has expanded leaps and bounds and has become a very powerful as well as simple tool in diagnostic histopathology<sup>1</sup>. Nowadays the methods of immunohistochemical procedures have been modified and simplified to the level, such that it can be done in almost all the laboratories. Many a number of newer diagnostic antibodies are introduced regularly to resolve diagnostic problems and to improve the diagnostic accuracy.

As the size of biopsies decrease, particularly in gastrointestinal tract lesions the role of immunohistochemical stains will become even more important in determining the site of origin and differentiation of these tumors.<sup>1</sup>

This study, analysed the clinicopathological and immunohistochemical features of gastric and intestinal poorly differentiated neoplasms.

## Materials and Methods

This prospective study was conducted in the Department of Pathology in a tertiary care hospital, Chennai after approval from the institutional ethics committee. Among the total 454 reported cases of gastrointestinal malignancies, 60 cases were categorized as poorly differentiated malignancies of stomach and intestine, and

were included in the study design. In all patients, the clinical data, including age, sex, occupation, personal history, clinical history, endoscopic findings, anatomic site and operative findings were recorded.

Among the 60 specimens, 54 were biopsies and 6 were resected specimens. All the specimens received were fixed in 10% neutral formalin for 18-24 hours. Detailed gross examination of the specimens were done. Representative samples were taken. Majority of specimens were endoscopic small biopsies, approximately 0.1 cc to 0.3cc, embedded in total. The tissues were processed in various grades of alcohol and xylol using automated histokinette.

Histopathological study was done in all the specimens as per standard guidelines. Immunohistochemical analysis was done in all 60 cases using carcinoembryonic antigen, CD 20, synaptophysin and chromogranin A to diagnose poorly differentiated adenocarcinomas, non-Hodgkins lymphomas and neuroendocrine carcinomas, among the poorly differentiated malignancies of stomach and intestine.

## Results

454 cases of gastrointestinal malignancies were reported during the study period. Among the total cases, gastric malignancies constitute maximum number of cases (350/454). Large intestine was placed next to stomach (92/454) and small intestine was in the third place (12/454).

Of these, 60 cases (13.21%) were categorised as poorly differentiated malignancies (PDM) of stomach and intestine. The most common site involved was stomach constituting 85%, followed by large intestine 11.7%, followed by small intestine, with 3.3%.

Among the total 60 cases, 46 cases showed expression of carcinoembryonic antigen (CEA). 14 cases showed negative results (Fig. 3-6).

12 out of 60 cases showed expression of CD 20 in our study and confirms the diagnosis of B-cell non-Hodgkins lymphomas. 2 cases showed synaptophysin and chromogranin A positivity.

Based on immunohistochemical analysis, out of total 60 cases, 46 cases were diagnosed as Adenocarcinomas, 12 cases were non-Hodgkins lymphomas (NHL), 2 cases were Neuroendocrine carcinomas (Graph 1).

The 60 cases consisted of 39 males and 21 females, and the age ranged from 19 – 85 years with a median of 56 years. Of the total cases, 51 cases (85%) were gastric poorly differentiated malignancies, 2 cases (3.33%) were small intestinal poorly differentiated malignancies, 7 cases (11.66%) were large intestinal poorly differentiated malignancies. 46 cases (76.67%) were poorly differentiated adenocarcinomas (PDAC), 2 cases (3.33%) were neuroendocrine carcinomas (NEC), 12 cases (20%) were lymphomas. The most common site of poorly differentiated adenocarcinomas was stomach.

In the 51 gastric poorly differentiated malignancies (male : female =12:5, age range =19–85 years, median = 58 years), 42 cases (91.30%) were poorly differentiated adenocarcinomas, 7 cases (13.73%) were B - cell lymphomas, 2 cases (3.92%) were neuroendocrine

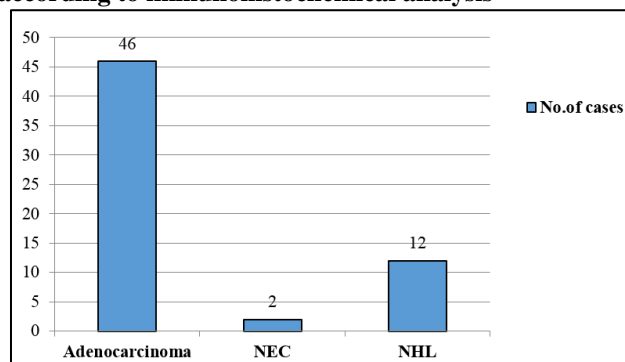
carcinomas (69 years/male, 70 years/ male). Among the poorly differentiated malignancies of stomach, the predominant histological type was poorly differentiated adenocarcinoma based on the results of this study.

In the 42 gastric poorly differentiated adenocarcinomas (male:female = 3 : 1, age range 37 – 85 years, median = 52 years), 5 cases (11.90%) were located in the upper part (cardia, incisura, fundus) of stomach, 11 cases (26.19%) were located in the body of stomach and the remaining 26 cases (61.91%) were located in antral portion of stomach (Graph 2). 38 cases (90.48%) were presented with localised lesions, 4 cases (9.52%) were infiltrative lesions (Graph 3). As per our study the antral portion of the stomach was the most common site of involvement followed by, body of the stomach. Upper part (cardia, incisura, fundus) of the stomach was the least common site affected. The most common macroscopic presentation of PDAC was of localised pattern of growth as per the study.

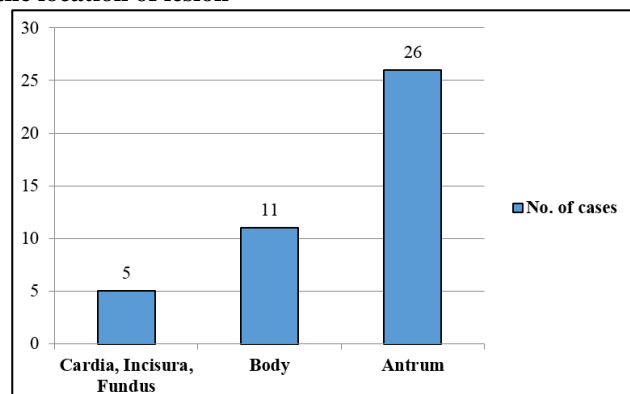
In the 7 colonic poorly differentiated malignancies, 4 cases (57.14%) were poorly differentiated adenocarcinomas, 3 cases (42.86%) were lymphomas. Of the total 4 poorly differentiated adenocarcinomas of colon (male : female = 0: 4, age range = 37 – 65 years, median = 52 years) 2 were (50%) located in rectum, among the remaining two cases, each located in ascending colon and transverse colon (Fig. 1, 2).

Among the total 12 cases of B – cell lymphomas, 7 cases (58.33%) were located in stomach, 2 cases (16.67%) were located in small intestine and 3 cases (25%) were located in large intestine. The neuroendocrine carcinomas (69 years/male, 70 years/male) were located in stomach (fundus, antrum).

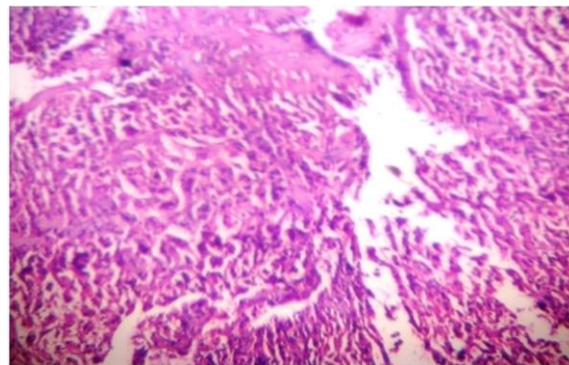
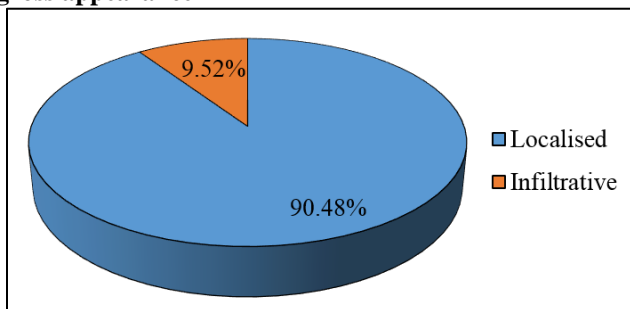
**Graph 1: Distribution of PDM of stomach and intestine according to immunohistochemical analysis**



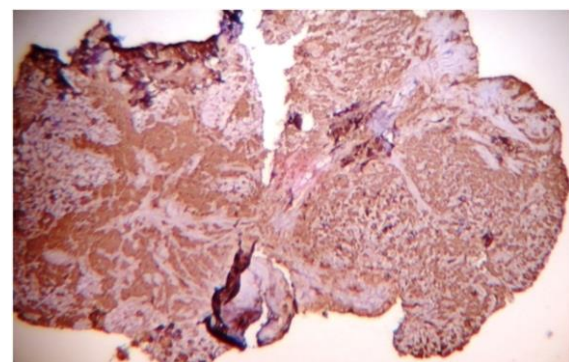
**Graph 2: Distribution of PDAC of stomach according to the location of lesion**



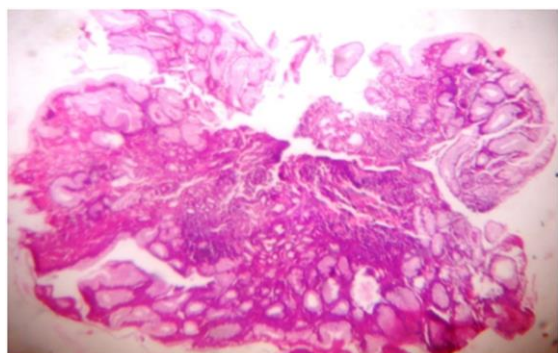
**Graph 3: Distribution of PDAC of stomach according to gross appearance**



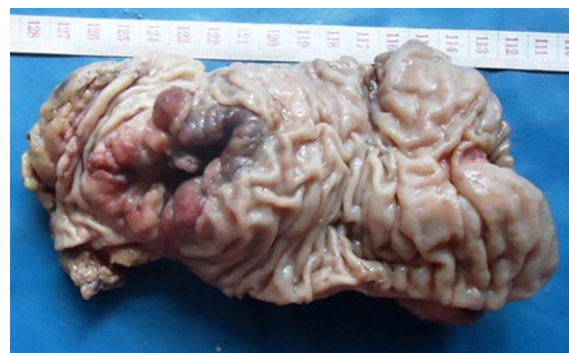
**Fig. 3: 4 X – Poorly differentiated malignancy of large intestine**



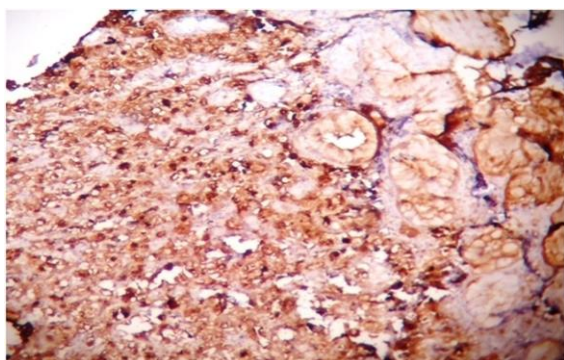
**Fig. 4: 10 X – CEA positive**



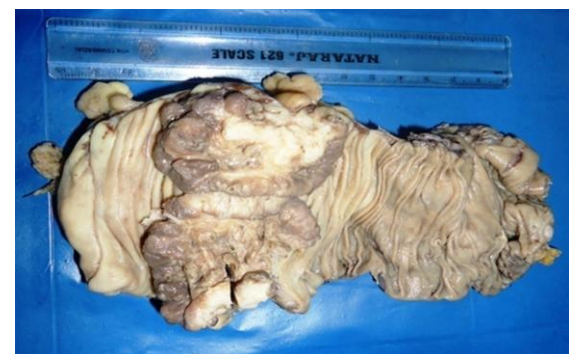**Fig. 1: 4 X – Poorly differentiated malignancy of stomach**



**Fig. 5: Colectomy specimen – proliferative growth**



**Fig. 2: 10 X – CEA positive**



**Fig. 6: Colectomy specimen –ulceroproliferative growth.**

## Discussion

The gastrointestinal tract tumors are heterogeneous group of lesions with varied architecture, pattern of growth, cell differentiation, and histogenesis. It is wise to mention that these tumors share many characteristics, making definitive diagnosis a very challenging one. Since the histological type of each and every tumor is important for assessing staging, treatment protocols and prognosis, it highlights the strong role of pathologists who should use all available resources and recent advances, along with light microscopy to arrive at a definitive final diagnosis.

Tumors of the gastrointestinal tract are varied and hence prove to be diagnostically challenging.<sup>1</sup> When considering poorly differentiated malignancies which are categorised as tumors with poor prognosis, it is a must to give specific diagnosis to select appropriate therapeutic strategy and to predict prognosis. Understanding the unique immunohistochemical profiles of each tumor entity will greatly aid in the diagnoses of these tumors.<sup>1</sup>

Poorly differentiated types of gastric and intestinal malignancies are generally more spreading in nature, locally, to the surrounding structures and to the distant organs, very rapidly and risking the survival of the patients, mortality higher when compared with differentiated types.<sup>2</sup>

Based on the degree of cellular differentiation, literature data proved, that the most favourable prognosis is associated with well differentiated tumors, well differentiated neoplasms have significantly better survival rate as compared with poorly differentiated neoplasms.<sup>3-8</sup>

In the present study, of the 454 cases of gastrointestinal malignancies, 350 cases (77.09%) were gastric malignancies, 12 cases (2.64%) were small intestinal malignancies, and 92 cases (20.26%) were colon malignancies. Small intestine was the least affected organ. This analytical finding was similar to literature data, which also prove that the small intestinal malignancies are very rare compared to other gastrointestinal organs.<sup>9-11</sup>

In our analysis, the observed incidence of well differentiated adenocarcinomas of stomach is 85.51% and the incidence of poorly differentiated adenocarcinomas is 14.49%.

Chikara Kunisaki et al<sup>12</sup> studied the clinicopathological properties of poorly differentiated adenocarcinoma of stomach in 1558 patients, found that incidence of well differentiated adenocarcinoma of stomach as 71.75% and the incidence of poorly differentiated adenocarcinoma as 28.25%, which correlates with our findings.

When we consider other studies, Yosuke Adachi et al<sup>13</sup> study on the topic of pathology and prognosis of gastric carcinoma on 504 gastric carcinoma patients, concluded higher incidence of poorly differentiated adenocarcinomas of about 43.85%.

The median age at diagnosis of poorly differentiated adenocarcinomas of stomach in the present study is 60 years, with the age range between 37–85 years. There is a positive correlation observed between our study and Yosuke Adachi et al Study<sup>13</sup> on the grounds of mean age and age range (Table 1).

Chikara Kunisaki et al (2006)<sup>12</sup> conducted studies on 1558 patients and stated that males constituted 60.23%, females were 39.77%.

In Yosuke Adachi et al study on 504 patients, males were 57%, whereas females were 43%. Over all, male predominance observed in our study correlates with other studies.

Our study showed predominantly localised growth pattern (90.48%), which included proliferative, ulceroproliferative, ulcerated and nodular lesions. Chikara Kunisaki et al,<sup>13</sup> observed maximum number of cases (89%) with infiltrative growth pattern in their study.

When we analyse the anatomical site of lesion, our study showed that the commonest location of involvement is antral portion of stomach (61.91%). Yosuke Adachi et al,<sup>13</sup> noted highest (55%), incidence of tumors in body of stomach.

Yosuke Adachi et al<sup>13</sup> and Chikara Kunisaki et al<sup>12</sup> both observed maximum number of cases in body of stomach.

Observations related with the large intestinal lesions were compared with the study of Takefumi Yoshida,<sup>14</sup> who have done a clinicopathological study on poorly differentiated adenocarcinomas of colon on 1074 patients in 2011. Positive correlation observed in terms of incidence and location (Table 2, 3).

**Table 1: Gender distribution of PDAC of stomach**

Variables	Present Study	Yosuke Adachi et al Study <sup>3</sup>
Mean age in years	60	58
Age range in years		
< 60	47.83%	51%
> 60	43.48%	49%
Male	76.19%	57%
Female	23.81%	43%

**Table 2: Incidence of PDAC of large intestine**

Incidence	Present study	Takefumi Yoshida Studies (2011) <sup>14</sup>
WDAC	92.39%	92%
PDAC	7.6%	8%

**Table 3: Comparison based on gender distribution & location of PDAC of large intestine**

Gender	Present study	Takefumi Yoshida Studies (2011) <sup>14</sup>
Male	0%	56.82%
Female	100%	43.18%
Site of Lesion		
Ascending and descending colon	50%	57.95%
Rectum	50%	42.05%

### Conclusion

To conclude, the histological variant of gastric and intestinal malignancies is one of the crucial factor which determines staging, treatment protocol and prognosis of these tumors. As the endoscopically derived biopsy specimens are tiny, the role of immunohistochemical stains will become even more important in determining the origin and differentiation of gastrointestinal tract tumors. In each and every case of poorly differentiated malignancies, a panel of markers should be used to arrive at a definitive diagnosis as well as to avoid the errors in diagnosis.

**Conflict of Interest:** None.

### References

1. Wong HH, Chu P. Immunohistochemical features of the gastrointestinal tract tumors. *J Gastrointest Oncol* 2012;3(3):262.
2. Lee HH, Song KY, Park CH, Jeon HM. Undifferentiated-type gastric adenocarcinoma: prognostic impact of three histological types. *World J Surg Oncol* 2012;10(1):254.
3. Lazar D, Taban S, Sporea I, Dema A, Cornianu M, Lazar E, et al. Gastric cancer: correlation between clinicopathological factors and survival of patients. II. *Rom J Morphol Embryol* 2009;50(2):185-194.
4. Gorbunov E, Wechsler J, Stašek J, Tomin A, Solodun L. Significant prognostic factors in 283 patients after surgery for adenocarcinoma of the stomach. *Scripta Medica Facultatis Medicae Universitatis Brunensis Masarykianae*. 2005;78(1):3-16.
5. Dicken B, Saunders L, Jhangri G, De Gara C, Cass C, Andrews S, et al. Gastric cancer: establishing predictors of biologic behavior with use of population-based data. *Ann Surg Oncol* 2004;11(6):629-635.
6. Kim D-Y, Joo J-K, Ryu S-Y, Park Y-K, Kim Y-J, Kim S-K. Clinicopathologic characteristics of gastric carcinoma in elderly patients: a comparison with young patients. *World J Gastroenterol: WJG* 2005;11(1):22.
7. Su Jin S, Baek J, Kim H, Park J, Kim G, Kim D, et al. Prognostic factors in patients with recurrent gastric cancer after curative gastrectomy. *J Clin Oncol* 2008;26(15\_suppl):15612.
8. Medina-Franco H, Heslin MJ, Cortes-Gonzalez R. Clinicopathological characteristics of gastric carcinoma in young and elderly patients: a comparative study. *Ann Surg Oncol* 2000;7(7):515-519.
9. Hamilton SR, Aaltonen LA. Pathology and genetics of tumours of the digestive system: IARC press Lyon; 2000.
10. Haselkorn T, Whittemore AS, Lilienfeld DE. Incidence of small bowel cancer in the United States and worldwide: geographic, temporal, and racial differences. *Cancer Causes Control* 2005;16(7):781-787.
11. Terada T. Malignant tumors of the small intestine: A histopathologic study of 41 cases among 1,312 consecutive

specimens of small intestine. *Int J Clin Exp Pathol* 2012;5(3):203.

12. Kunisaki C, Akiyama H, Nomura M, Matsuda G, Otsuka Y, Ono Ha, et al. Clinicopathological properties of poorly-differentiated adenocarcinoma of the stomach: comparison of solid-and non-solid-types. *Anticancer Res* 2006;26(1B):639-646.
13. Adachi Y, Yasuda K, Inomata M, Sato K, Shiraishi N, Kitano S. Pathology and prognosis of gastric carcinoma: well versus poorly differentiated type. *Cancer: Interdisciplinary. Int J Am Cancer Soc* 2000;89(7):1418-1424.
14. Yoshida T, Akagi Y, Kinugasa T, Shiratsuchi I, Ryu Y, Shirouzu K. Clinicopathological study on poorly differentiated adenocarcinoma of the colon. *Kurume Med J* 2011;58(2):41-46.

**How to cite this article:** Rajeswari T, Rajalakshmi V. Clinicopathological and immunohistochemical profile of poorly differentiated neoplasms of stomach and intestine. *Indian J Pathol Oncol* 2019;6(1):75-79.