

Study of FNAC in diagnosis of thyroid lesions: A prospective study

Sushant Mohite¹, Rupali Yelave^{2,*}, Vaibhav Mane³

¹Assistant Professor, Dept. of Pathology, Dr. D.Y. Patil Medical College, Kolhapur, Maharashtra, ²Junior Resident III, ³Associate Professor, Bharati Vidyapeeth (Deemed to be University) Medical College and Hospital, Sangli, Maharashtra, India

*Corresponding Author: Rupali Yelave

Email: vaishnavilab1060@gmail.com

Received: 19th May, 2018

Accepted: 20th July, 2018

Abstract

Introduction: Fine needle aspiration cytology (FNAC) is the most sensitive, accurate and cost effective initial method for the clinical management of patient with thyroid nodules. Majority of the thyroid nodules are benign, with cancer accounting for only 1% of all the lesions. Hence it is imperative for the treating surgeon to know the biologic nature, as to benign versus malignant lesions and thus plan appropriate treatment. This would in turn avoid unnecessary surgeries. Follicular patterned lesions is a grey zone area in cytology.

Aims and Objectives: To study the various morphological features of thyroid lesions by fine needle aspiration cytology and classify them according to Bethesda system for thyroid cytopathology-2007 and to evaluate the utility of FNAC in planning the management of thyroid lesions.

Materials and Methods: The study was conducted in Department of Pathology, Bharati Vidyapeeth (Deemed to be University) Medical College and Hospital, Sangli, on patients meeting the mentioned inclusion and exclusion criteria.

Results : Out of 90 cases, 3 cases (3.34%) were unsatisfactory for reporting, 69 cases (76.67%) were benign, 7 cases (7.77%) were categorized under AUS/FLUS. 9 cases (10%) were reported as Follicular Neoplasm (FN) or Suspicious for FN, 1 case (1.11%) was reported as suspicious of malignancy and 1 case (1.11%) were reported as malignant.

Conclusion: FNAC of the thyroid is simpler and accurate preoperative diagnostic test compared with other diagnostic modalities. The results of thyroid cytology must be assessed in conjunction with the clinical findings and other investigations like TFT and USG findings, in view of the possibility of false negative or false positive cytological diagnosis.

Keywords: FNAC, Bethesda, Thyroid, Follicular Neoplasm.

Introduction

The word Thyroid originated from “Thyreos”, a Greek word meaning shield.¹ Diseases of the thyroid gland are common endocrine diseases particularly in countries like India where iodine intake through diet is low.²

Thyroid carcinoma closely resembles its benign counterpart in physical characteristics, measurable physiological parameters such as serum T3/T4 levels and ultrasonic characteristics.³ Therefore, the surgical excision of the nodule and its histological examination is the only way to differentiate between the more frequent benign and much less frequent malignant nodules.⁴ Since most of the thyroid nodules are benign, symptomless and small in size, they do not require surgical excision.⁵

In India, there are 2,16,000 new cases of thyroid malignancies per year and hence the role of properly evaluating thyroid lesions is significant.⁶

Fine-needle aspiration (FNA) has an essential role in the evaluation of euthyroid patients with a thyroid nodule.⁷ It reduces the rate of unnecessary thyroid surgery for patients with benign nodules and appropriately triages patients with thyroid cancer to appropriate surgery.⁸

Fine needle aspiration cytology (FNAC) is the most sensitive, accurate and cost effective initial method for the clinical management of patient with

thyroid nodules. Majority of the thyroid nodules are benign, with cancer accounting for only 1% of all the lesions. Hence it is imperative for the treating surgeon to know the biologic nature, as to benign versus malignant lesions and thus plan appropriate treatment. This would in turn avoid unnecessary surgeries. Follicular patterned lesions is a grey zone area in cytology.⁹ Neck swelling is a common clinical presentation all over the world.

Fine Needle Aspiration Cytology (FNAC) is a well-established, outpatient procedure used in the primary diagnosis of thyroid swellings. FNAC, by giving direct morphological information has supplanted most other tests for preoperative evaluation of thyroid nodules. Practice guidelines set forth by the American Thyroid Association and National Comprehensive Cancer Network, state that FNA should be used as an initial diagnostic test because of its superior diagnostic reliability and cost- effectiveness, before both thyroid scintigraphy and ultrasonography. As FNAC distinguishes between benign and malignant lesions quite effectively, it is the preoperative screening method of choice worldwide. Its use in recent years has resulted in a significant decrease in the number of surgeries being performed, while increasing the yield of malignant lesions of patients who have undergone surgery.¹⁰ If well-established and stringent diagnostic criteria are used, a majority of thyroid nodules can be

safely and accurately categorised by cytological assessment.

Often a specific diagnosis, such as a colloid goitre, thyroiditis, or a specific thyroid malignancy (eg papillary, medullary, anaplastic carcinoma) can be made. In some cases the use of ancillary techniques may enhance diagnostic accuracy. Some aspirates are non-diagnostic due to technical issues such as insufficient cellularity, poor quality of sample preparation or technical artefacts due to blood staining, ultrasound gel etc. In others, the distinction between benign and malignant nodules may not be possible due to interpretative difficulties. To ensure the best possible assessment of thyroid nodules some guidance on sampling, preparation of material, interpretation and reporting is warranted.^{11,12}

Due to its simplicity, low cost, and absence of major complications, it is the initial investigation in the management of thyroid disease in our teaching hospital. This study was undertaken to identify the various thyroid lesions by cytology, describe them as per Bethesda System of reporting thyroid cytopathology.¹³

This study is aimed at determining the utility and diagnostic accuracy of FNAC of thyroid lesions performed at our institution and to compare our experience with those of other regions of the world.

Aims and Objectives

1. To study the various morphological features of thyroid lesions by fine needle aspiration cytology.
2. To study age and sex wise incidence of benign and malignant thyroid lesions.
3. To classify malignant, benign and inflammatory lesions and sub-classify them. (According to Bethesda system for thyroid cytopathology-2007)
4. To evaluate the utility of FNAC in planning the management of thyroid lesions.
5. To find limitations of FNAC in diagnosis of thyroid lesions.

Materials and Methods

The study was conducted in Department of Pathology, tertiary hospital on patients meeting the mentioned inclusion and exclusion criteria. It was an hospital based observational study

Ethical Clearance: The study protocol was reviewed by The Institutional Ethical Committee and permitted by it, IEC no. is BVDUMC&H/ Sangli/ IEC/ 2014-15/75

Inclusion Criteria: Fine needle aspiration cytology of clinically palpable thyroid lesions

Exclusion Criteria

1. Subjects not consenting for fine needle aspiration.
2. Cytology of non palpable thyroid lesions.
3. Congenital anomalies of thyroid.

Data Collection

A detailed clinical history and thorough physical examination of patients having palpable thyroid swellings were carried out and entered in the proforma. An informed written consent was obtained from the patients before including them in the study. In case of minors, informed written consent was obtained from their legal guardians. The patients were explained about the procedure including its limitations and complications. Data regarding relevant radiological, biochemical and hematological investigations done for diagnostic purposes were collected.

Results

The present prospective study "Study of FNAC in Diagnosis of Thyroid lesions" was undertaken in the Department of Pathology, Tertiary Hospital from 1st January 2015 to 31st December 2015. FNAC was performed on 90 cases for cytological evaluation

Among 90 cases, 67.8% were aspirated in first attempt. Out of 90 cases, 87 cases (96.7%) were satisfactory and 3 (3.3%) cases were unsatisfactory for interpretation.

In present study the age of presentation ranged from 12 to 77, with a mean age of 41.4 ± 16.2 years. Age of the youngest patient in this series was twelve years with cytological diagnosis of lymphocytic thyroiditis. The oldest patient was of 77 years with cytological diagnosis of colloid goitre. Out of 90 cases, maximum 25 cases (27.8%) were seen in the age group of 4th decade.

In present study, the thyroid lesions were more seen in females (90%) with female to males in the ratio of 9:1.

In present study, we have studied various morphological features of thyroid lesions and classified them according to the Bethesda system for thyroid cytopathology (2007). Out of 90 cases, 3 cases (3.34%) were unsatisfactory for reporting, 69 cases (76.67%) were benign, 7 cases (7.77%) were categorized under AUS/FLUS. 9 cases (10%) were reported as Follicular Neoplasm (FN) or Suspicious for FN, 1 case (1.11%) was reported as suspicious of malignancy and 1 case (1.11%) were reported as malignant.

Out of 90 cases, benign category had 69 cases (76.7%) with colloid goiter (49 cases) being the predominant group followed by lymphocytic thyroiditis (20 cases).

Among 90 cases, the maximum number of 27 patients (30%) presented with duration of symptoms in between 6 -12 months and minimum number of 15 cases (16.8%) had the duration of symptoms with more than one year. Out of 90 cases, most of the thyroid swellings (38.9%) had size less than 3 cms. All 90 cases had common clinical symptom of midline neck swellings that moved up with deglutition. Out of 90 cases, the maximum number of thyroid cases that were investigated on USG were diagnosed as solitary colloid

goiter accounting for 63 (70%) cases. Both thyroiditis and multinodular goiter were diagnosed in 10 (11.1%) cases each.

Thyroid function tests were carried out in 70 out of 90 cases. 46 cases (65.7%) out of 70 cases were euthyroid. Cases with lymphocytic thyroiditis shows association with hypothyroidism.

In present study, the maximum number of thyroid lesions were having firm consistency (61.1%) followed by thyroid lesions of mixed consistency (26.7%).

In present study, maximum number of 48 (53.3%) cases were having bilateral diffuse involvement.

Clinically out of 90 palpable thyroid swellings the most common type of presentation was solitary thyroid nodule in 72(80%) patients while 18 (20%) patients had multinodular goitre.

Chart 1:

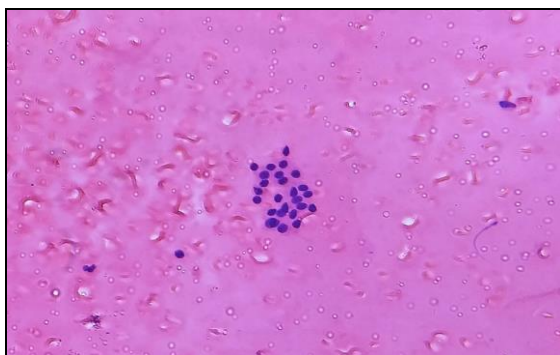
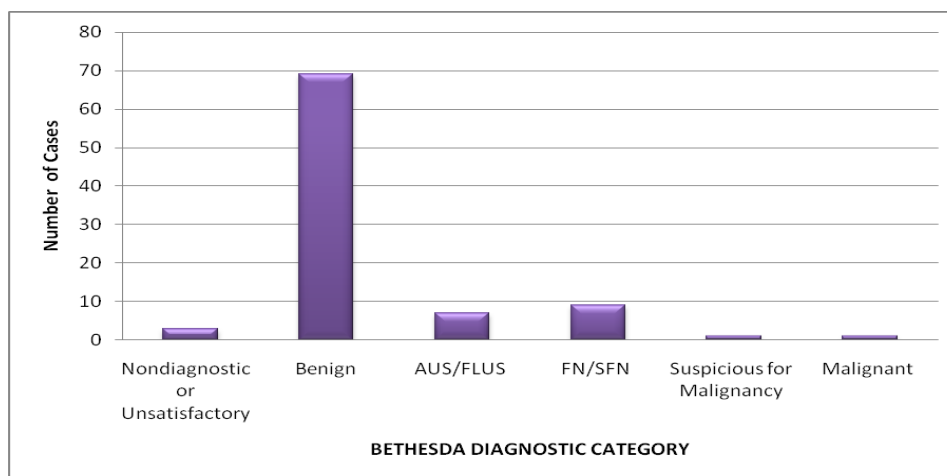


Fig. 1: H&E 40X: Colloid Goiter: Cluster of follicular cells on a background of thin colloid

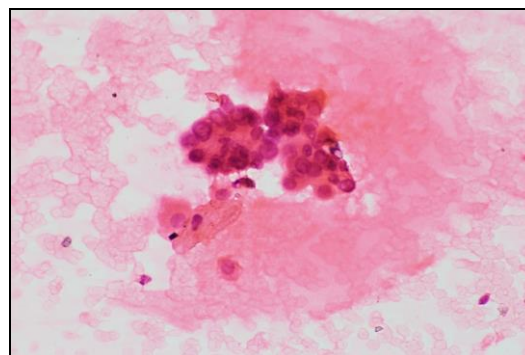


Fig. 3: H&E 40X: Suspicious for malignancy: Hypocellular smear showing follicular cells with enlarged nuclei, nuclear grooves and intranuclear pseudoinclusion

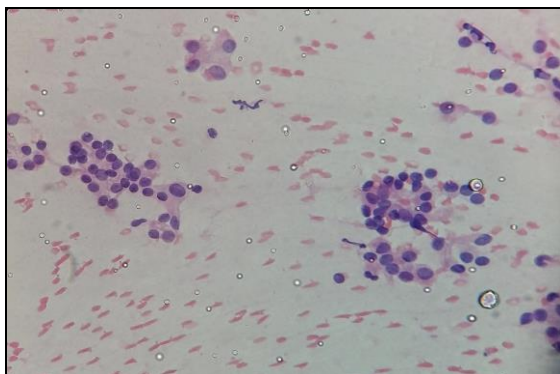


Fig. 2: H&E 40X: AUS /FLUS Follicular cells in microfollicular pattern with Hurthle cell change

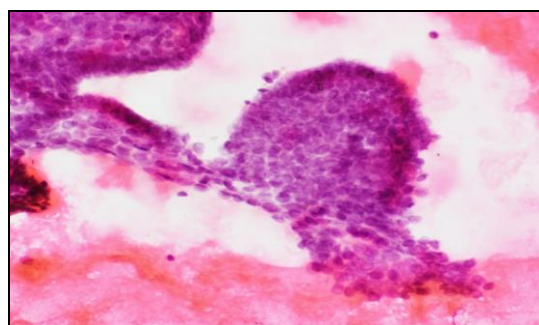


Fig. 4: H&E 40X: Papillary carcinoma: Hypercellular smear showing follicular cells arranged in papillae with enlarged nuclei, nuclear grooves and intranuclear pseudoinclusions

Discussion

Fine needle aspiration cytology has proven to be a highly effective screening and diagnostic tool in the evaluation of thyroid nodules. It is simple safe, speedy, minimally invasive, outdoor procedure and cost effective. FNAC is often used as a first priority investigation in patients with thyroid disease. The procedure was performed on an OPD basis mostly without anaesthesia and no complications. The patient compliance was good and they were very cooperative even when repeat aspiration had to be performed in some cases.

Table 1: Sex-wise distribution: Female to male ratio of thyroid lesions in various studies

S. No.	Authors	Year	Female: Male ratio
1	Vinay Kumar R et al ²³	2014	7:1
2	Sunita Bamanikar et al ²⁷	2014	8.6:1
3	Present study	2015	9:1

In our study, out of total 90 cases 81 patients were females and 9 patients were males.

Table 1 shows that Female: Male ratio in our study was 9:1. It was comparable to most of the studies. It was closest to Sunita Bamanikar et al²⁷ in which the Female: Male ratio was 8.6:1.

It is a well known fact that thyroid diseases affect females more commonly than males.

In our study 81 females (90%) with thyroid swellings were referred for cytological study during the one year study period. Out of the total 81 female cases, three cases were unsatisfactory for reporting. Sixty three cases were benign thyroid lesions, six cases were of AUS/FLUS and seven cases were reported as follicular neoplasm (FN/SFN). One case was reported as Suspicious for Malignancy and one case was reported as Malignant.

Out of 9 males (10%) with thyroid swellings were referred for cytological study during the one year study period. Out of the total 9 male cases, six cases were benign.

Table 2: Clinical presentation in other study

Authors	Year	Clinical presentation				
		Neck swelling (%)	Dysphagia (%)	Dyspnoea (%)	Pain (%)	Hoarseness of voice (%)
Handa U et al ²¹	2008	100	4	3	8	3
Present Study	2015	100	2	6	2	-

Handa U et al (2008)²¹ stated in their study that the major presenting symptom was diffuse swelling and/or nodular swelling of the thyroid. Other less frequent symptoms included pain in the swelling, dysphagia, hoarseness of voice and cough.

In present study, the most of the patients came with common complaint of swelling in front of the neck which was comparable with other studies.

Table 3: Comparison of FNAC diagnosis based on Bethesda classification

Diagnostic category	Nayar Rand Ivanovic M et al (2009) ²⁴	Mulazim Hussain Bukhari et al ²⁵	M. Mamatha et al (2015) ²²	Present Study (2015)
Nondiagnostic	5	10.8	10.8	3.4
Benign	64	60	60	76.7
AUS	18	3.4	3.3	7.7
Follicular Neoplasm /SFN	6	12.4	12.5	10
Suspicious For malignancy	2	4.2	4.2	1.1
Malignant	5	9.2	9.2	1.1

This category applies to specimens that are unsatisfactory owing to obscuring blood, overly thick smears, air drying of alcohol-fixed smears, or an inadequate number of follicular cells. For a thyroid FNA specimen to be satisfactory for evaluation (and benign), at least 6 groups of benign follicular cells are required, each group composed of at least 10 cells. There are several exceptions to the numeric requirement of benign follicular cells. Any specimen

that contains abundant colloid is considered adequate (and benign), even if 6 groups of follicular cells are not identified.

The present study had 3 (3.4%) cases in ND/UNS category. Other recent studies had 1.2% to 10.6% cases in this group. The guidelines for this category are very clear in TBSRTC. All of them were advised to be reaspirated after a minimum period of 3 months.

TBSRTC does not provide the implied risk of malignancy for this category.

The benefit of thyroid FNA derives in large part from the ability to make a reliably benign interpretation that avoids unnecessary surgery. The benign category had 69 cases (76.7%) with colloid goiter (49 cases) being the predominant group followed by lymphocytic thyroiditis (20 cases). The “benign” category had a range of 60% to 87.5% in recent studies.

Some thyroid FNAs are not easily classified into the benign, suspicious, or malignant categories. Such cases represent a minority of thyroid FNAs and in the Bethesda System are reported as “atypia of undetermined significance” (AUS) or “follicular lesion of undetermined significance.” We had 7 (7.7%) cases in group AUS/FLUS. AUS result has been reported in 1–18% of thyroid cases in other studies. TBSRTC suggests that the frequency of AUS interpretations should be in the range of approximately 7% of all thyroid FNA interpretations. This is a category of last resort and should not be used indiscriminately. Not much data exists in the literature to support the recommendation that the category should not exceed 7% of all thyroid categories.

Conclusion

FNAC is an invaluable tool in the management of thyroid lesions with a high degree of accuracy. It is minimally invasive, safe outpatient procedure without major complications and can be repeated due to patient acceptance. The six diagnostic categories in the Bethesda system for reporting thyroid cytopathology are well defined, morphologically distinct and ensure a uniform reporting system for thyroid FNA. This facilitates effective communication among cytopathologists, endocrinologist, surgeons, radiologist and other health care providers. The results of thyroid cytology must be assessed in conjunction with the clinical findings and other investigations like TFT and USG findings, in view of the possibility of false negative or false positive cytological diagnosis.

Financial Support: Nil.

Conflict of Interest: There is no conflict of interest.

References

- Shuja A. History of thyroid surgery. *Professional Med J*. 2008;15(2):295-7.
- Zimmermann MB. Research on Iodine Deficiency and Goiter in the 19th and Early 20th Centuries. *The Journal of Nutrition*. 2008;138:2060-3.
- Hegazy RA, Hegazy AA. FNAC and Cell-block Study of Thyroid Lesions. *Universal Journal of Medical Science*. 2013;1(1):1-8.
- Gritzmann N, Koischwitz D, Rettenbacher T. Sonography of the thyroid and parathyroid glands. In: Weber AL, editor. *The Radiologic Clinics of North America*. 3rd ed. New York: Elsevier; 2000. p. 1131-43.
- Pandit AA and Kinare SG. Fine needle aspiration cytology of thyroid. *Indian J Cancer*. 1986;23(1):54-8.
- Rani SM, Reddy DS, Rao SK. Cyto-histopathological and clinico-radiological evaluation of thyroid lesions. *Int J Med Sci Public Health*. 2016;5(7):1391-5.
- Esmaili HA, Taghipour H. Fine Needle Aspiration in the diagnosis of Thyroid Diseases: An Appraisal in our Institution. *ISRN Pathol*. 2012;2012:1-4.
- Cibas ES, Ali SZ. The Bethesda System for Reporting Thyroid Cytopathology. *Am J Clin Pathol*. 2009;132:658-65.
- Shobha SN, Amita K, Narendra BR. Evaluation of the Role of Fine Needle Aspiration Cytology in the Diagnosis of Follicular Patterned Lesions of Thyroid. *Indian Journal of Pathology and Oncology*. 2015;2(3):158-60.
- Bagga PK, Mahajan NC. Fine needle aspiration cytology of thyroid swelling: how useful and accurate is it?. *Indian J Cancer*. 2010;47(4):437-42.
- Royal College of Pathologists of Australia. Thyroid Cytology Structured Reporting Protocol. Sydney: RCPA, 2014. www.rcpa.edu.au/getattachment/b0545d63-2198-4d39-b190-9624ed686404/Protocolthyroid-FNA-cytology.aspx (accessed January 2016).
- The McGraw-Hill Companies, inc. photograph, viewed on 15 January 2016, http://www.mhhe.com/biosci/esp/2001_saladin/folder_structure/in/m5/s4/index.htm.
- Standring S. *Grays Anatomy, The Anatomical Basis of Clinical Practice*, 39th ed. Philadelphia: Elsevier, 2008:560-66.
- Bishop's Clinical chemistry, 6th edition. Photograph, viewed on 15 January 2016, <http://edusanjalbiochemist.blogspot.in/2012/12/how-thyroid-hormones-are-formed.html>.
- Frale WJ. Thin needle aspiration biopsy. In: Bennington JL, editor. *Major problems in pathology*. 14th vol. Philadelphia (PA): WB Saunders; 1983. p. 152-82.
- Kun M. A new instrument for the diagnosis of tumors. *Monthly J Med Sci*. 1846;7:853-4.
- Diagnostic Cytology: Its Origin and Principles. In: Koss LG, Melamed MR, editors. *Koss' Diagnostic Cytology and its Histopathologic Bases*. 5th ed. Philadelphia: Lippincott Williams & Wilkins; 2006. 3-20.
- Stewart FW. The Diagnosis of Tumors by Aspiration. *Am J Pathol*. 1933;9:801-12.3.
- Higgins J, Letourneau J. Percutaneous biopsy of abdominal masses. In: Casteneda-Zuniga W, eds. *Interventional radiology*. Philadelphia (PA): Williams & Wilkins; 1997.1691-718.
- Mehra P, Verma AK. Thyroid cytopathology reporting by the Bethesda system: a two-year prospective study in an academic institution. *Pathol Res Int*. 2015;2015:1-11.
- Handa U, Sukant G, Mohan H, Nagarkar N. Role of fine needle aspiraton cytology in diagnosis and management of thyroid lesions: A study on 434 patients. *J Cytol*. 2008;25(1):13-7.
- M. Mamatha, S. Chandra Sekhar, H. Sandhya Rani, S Sandhya Anil, G. Vandana. A comparative study between conventional system and the Bethesda system applied for reporting thyroid cytopathology. *IAIM*. 2015;2(3):87-95.
- Vinay Kumar R, Batra N, Parames, Kariappa T M. A Study of Fine Needle Aspiration Cytology of Thyroid Lesions with Histopathological Correlation. *IJCMAAS*. 2014;4(2):64-71.
- Nayar R, Ivanovic M. The Indeterminate Thyroid Fine-Needle Aspiration. *Cancer (Cancer Cytopathol)*. 2009;117:195-202.

25. Bukhari MH, Khan AA, Niazi S, Arshad M, Akhtar ZM, et al. Better Thyroid Cytopathology Reporting System May Increase the Clinical Management and Patients Outcome. *J Cytol Histol.* 2012;3(6):1-6.
26. Godinho-Matos L, Kocjan G, Kurtz A. Contribution of fine needle aspiration cytology to diagnosis and management of thyroid disease. *J Clin Pathol.* 1992;45:391-5.
27. Bamanikar S, Soraisham P, Jadhav S, Kumar H, Jadhav P, Bamanikar A. Cyto-histology and clinical correlation of thyroid gland lesions: A 3 year study in a tertiary hospital. *Clin Cancer Investig J.* [serial online] 2014 [cited 2016 Aug 27];3:208-12. Available from: <http://www.ccijournal.org/text.asp?2014/3/3/208/132112>

How to cite this article: Sushant Mohite, Rupali Yelave, Mane V. Study of FNAC in diagnosis of thyroid lesions: A prospective study. *Indian J Pathol Oncol.* 2018;5(4):574-579.