

A prospective randomized comparison between perivascular and perineural ultrasound guided axillary brachial plexus block for upper limb surgeries

Padmini¹, Sevagamoorthy², Rajaprabhu^{3,*}

^{1,2}Assistant Professor, ³Professor, Dept. of Anaesthesiology, Government Stanley Medical College, Chennai, Tamil Nadu, India

*Corresponding Author: Rajaprabhu

Email: rajaprabhu752@gmail.com

Received: 2nd June, 2018

Accepted: 14th August, 2018

Abstract

Introduction and Aims: ultrasound had revolutionized the nerve block by, increasing the reliability with less complications. This study evaluates the block characteristics and efficacy between perivascular and perineural ultrasound guided axillary brachial plexus block for upper limb surgeries.

Materials and Methods: 100 patients in the age group of 18-60 years belonging to ASA I,II physical status undergoing axillary block in upper limb surgeries were randomly allocated into Group PN- perineural (n=50) and Group PV- perivascular (n=50). In both the groups Musculocutaneous nerve block done with 6ml of local anaesthetic mixture. In perineural group, radial nerve, median nerve and the ulnar nerve were anaesthetized separately with 8ml of local anaesthetic mixture respectively. In perivascular group, the needle tip was then advanced dorsal to the artery, corresponding to 6'o clock position. 24ml of local anaesthetic mixture was incrementally injected. The primary objective was to assess the success rate of blockade for surgery. The secondary objectives were to assess the onset and duration of sensory and motor block and to study the incidence of adverse effects.

Results: There was no statistical significance in the success rate of blockade between the techniques (PN-98% and PV 96% with P value is 0.362).The sensory and motor onset time in PN group(6.98 min,10.22 min) is faster than PV group(10.96 min,13.50) with P value was<0.01.The mean duration of the blockade was significantly higher in the PN group.

Conclusion: we conclude that the USG guided perineural technique as more reliable than the USG guided perivascular technique of axillary block.

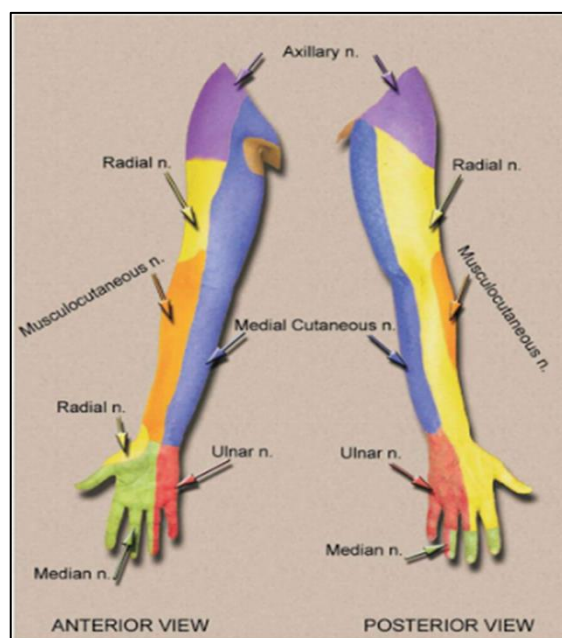
Keywords: Perivascular, Perineural, Ultrasound guided, Axillary brachial plexus block.

Introduction

Peripheral nerve block has become a popular method of anesthesia as it decreases not only the intraoperative concerns of the anaesthesiologists, but also because of its longer term perioperative & postoperative pain management. It leads to reductions in the stress response, opioid related side effects, systemic analgesic requirements, general anaesthesia requirements and possibly the development of chronic pain in addition to potent analgesia.

In clinical practice, blocking the brachial plexus for upper limb surgeries is one of the most popular method to be performed peripheral nerve block. The various approaches to brachial plexus block include 'interscalene, supraclavicular, infraclavicular and axillary'. Brachial plexus blockade provides anaesthesia of the shoulder, arms, forearms and hands depending upon the approach of blockade.

Axillary brachial plexus block is one of the preferred techniques in upper limb procedures, blocking brachial plexus at the level of ultimate branches, namely, median, ulnar, musculocutaneous and radial nerve. Blocking brachial plexus at the axillary level, avoids complications such as pneumothorax that can occur with other levels of approach.



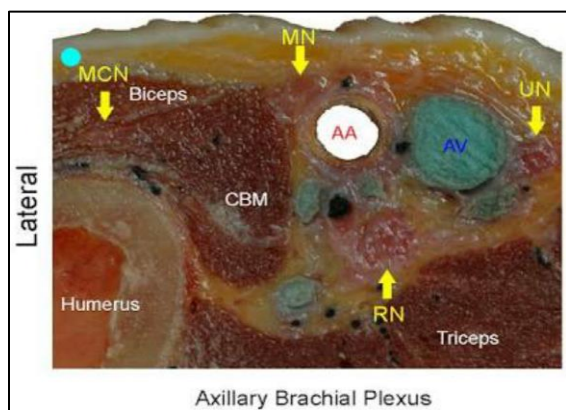
Ultrasound guidance, increases the reliability of the block, decrease onset time and lowers complications and hence became increasingly popular. Direct visualization of peripheral nerves and targeted drug injections has become possible with the help of ultrasound imaging.

With the PN technique the musculocutaneous, median, radial and ulnar nerves are identified and selectively anaesthetized. In PV technique, only the localization of the musculocutaneous nerve is required followed by the deposition of the local anaesthetic posterior to the axillary artery. Circumambient spread of the local anaesthetic around the axillary artery will ensure the blockade of median, radial and ulnar nerve.

The anatomical basis of single injection technique is that the septa divides the axillary sheath incompletely, because of which the instilled local anaesthetic solution advances by simple diffusion to all nerve compartments. However, complications such as accidental vascular puncture and paraesthesia may occur.

We hypothesize that PN technique has outcome of quicker onset as well as greater quality when compared to PV technique, as local anaesthetics is deposited very close to the nerves.

Axillary brachial plexus is placed lateral to the first portion of the axillary artery, it surrounds the second part of the artery, one cord lying medial to it, one lateral to it and one behind it; at the lower part of the axilla it gives off its terminal branches to the upper limb.



The axillary artery and vein are visualized in short axis view during the axillary nerve block using a high frequency linear array ultrasound transducer. The nerves are visualized accordingly more precise. The only disadvantage is high cost of the equipment. The Inplane technique of needle approach provides better visualization.

Materials and Methods

After getting approval of the institutional ethical committee, the study was done in a Multispecialty hospital. This randomized, prospective clinical trial was conducted on 100 patients undergoing surgeries on forearm, wrist and hand in a duration of four months.

Adult patients in age group of 18-60 years belonging to ASA I, ASA II physical status of both sexes undergoing axillary block in upper limb surgeries were included in the study. Patients who had bleeding disorders, Infection at the axillary area of the surgical

limb, allergy to local anaesthetics, pregnancy or breast feeding females, severe obesity (BMI>35 KG/M2), Psychiatric disorders, neurological disorders and previous surgeries in axilla were excluded in the study.

The patients were randomly allocated into 2 groups PN and PV of 50 each. Group PN- perineural (n=50) and Group PV- perivascular (n=50). Serial numbers from 1 to 100 were listed in lots and preparation of coding sheet allotting each number randomly to a group was done. The observer, evaluating the brachial plexus block, is allowed to take a lot and the number selected was marked in the proforma. The observer was blinded to the injection techniques.

Written informed consent was obtained. The patients were shifted to the theatre and following monitors were connected: Pulse oximetry, Electrocardiography and Non-invasive arterial blood pressure.

Intravenous (IV) access was secured on the non-surgical limb with 18-G canula. 30ml of local anaesthetic mixture was prepared with 10ml of 2% lignocaine with adrenaline, 10ml of 0.5% bupivacaine and 10ml of distilled water.

Patient was positioned supine with head tilted towards the other side. The surgical arm which to be anaesthetized was abducted with the forearm supination and the elbow flexed with hand above head. Preparation of axillary area with betadine solution was done and area was draped with sterile towels.

Ultrasound machine, placed by side of the patient and high frequency (18 MHz) linear probe, after applying ultrasound gel was covered with sterile dressing, was kept ready. After in alignment with patient and ultrasound machine, the probe is placed transversely across the axilla immediately distal to that point at 90 degree to the axis of the arm, in the junction of Biceps brachii and Pectoralis muscles approximately. After placing the transducer, sliding across the axilla brought the axillary artery and brachial plexus into view. "Structures [vascular structures – anechoic, nerves- hyperechoic surrounding the artery] such as the axillary artery, axillary vein, nerves [median nerve was seen at 9-11'o clock position; ulnar nerve at 2'o clock position and radial nerve at 5-6'o clock position relative to the axillary artery] and muscles were identified".

In both the techniques, the musculocutaneous nerve was initially located as a triangle shaped within the Coracobrachialis muscle a few centimeters away from axilla and block was done with 6ml of local anaesthetic mixture with inplane technique.

Perineural Group: The radial nerve (5-6'o clock to the axillary artery), median nerve (9-11'o clock to the axillary artery) and the ulnar nerve (2'o clock to the axillary artery) were anaesthetized separately with 8ml of local anaesthetic mixture respectively.

Schematic Representation of Block in Perineural Group

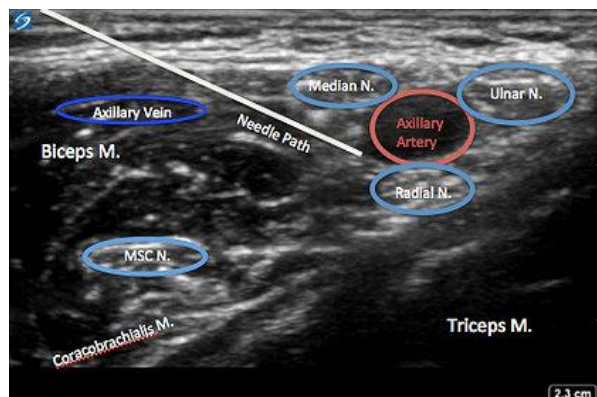


Fig. 1: Needle position for radial nerve block

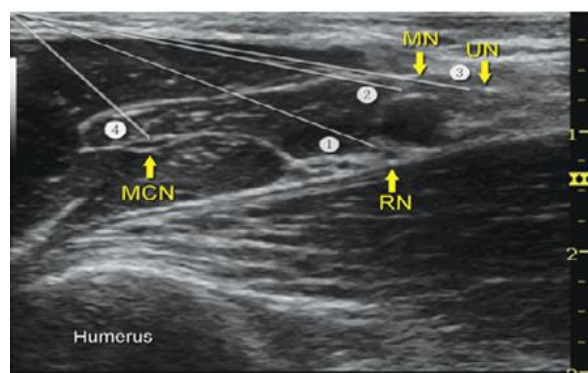


Fig. 2: Arrangement of nerves around the axillary artery

For Perivascular Group: Advancement of the needle tip done dorsal to the artery was done as close as possible, corresponding to 6'o clock position. And 24ml of local anaesthetic mixture was incrementally injected such that it ensures the circumferential spread of local anaesthetic mixture around each nerve.

Schematic Representation of Block in Perivascular Group

After completion of the procedure, brachial plexus blockade was measured as follows for every 3 minutes post completion of drug injection till the onset of the blockade and vital parameters noted every 15 minutes.

Sensory block of the median, musculocutaneous, ulnar and radial nerves was analyzed by pin prick method: Grade 0 = sharp pain, Grade 1= dull sensation (analgesia), Grade 2 = no sensation (anaesthesia) Sensory blockade of each nerve was assessed in the sites as follows:

1. Muscularocutaneous nerve – lateral aspect of the forearm
2. Radial nerve – lateral aspect of the dorsum of hand
3. Ulnar nerve – palmar aspect of 5th finger
4. Median nerve – palmar aspect of thumb

Assessment of the motor blockade was done by the Modified Bromage scale: Grade 0 = full extension of elbow, wrist and fingers with normal motor function, Grade 1 = decreased motor function with ability to move fingers or wrist only, Grade 2 = inability to move fingers with complete motor blockade.

Motor assessments of individual nerves were assessed as follows:

1. Muscularocutaneous nerve – elbow flexion
2. Radial nerve – wrist extension
3. Ulnar nerve – thumb adduction
4. Median nerve – thumb opposition

Maximal composite score of 16 was taken. Blockade was considered successful with a composite score of ≥ 14 . (With minimum sensory blockade score of ≥ 7). The block was considered failure, when the composite score of 14 is not achieved even after 30 minutes of drug administration. If any of the nerve territory was spared, the particular nerve was blocked at the level of elbow. If pain persists, 2mcg/kg of fentanyl were given.

Intraoperatively, vital parameters was monitored every 15 minutes and postoperatively, every 30 minutes till block wore off. Complications if any during intraoperative period and post-operative period was noted.

Duration of sensory blockade: Time interval between completion of drug administration and resumption of sensation of pain in the surgical limb.

Duration of motor blockade: Time interval between completion of drug administration and resumption of full motor power in the surgical limb.

There were a total of five failure cases of effective surgical blockade. In all the five cases, ulnar nerve was found to be spared, which was then blocked with landmark technique of ulnar block at wrist level.

Results

The demographic profile was analyzed and distribution of the age, sex and weight of the patients in both the groups was compared. The results of which showed both of the groups were comparable (Table 1) Student t test.

1. Mean onset of radial nerve sensory block was 5.76 and 6.12 in PN and PV groups respectively. (P value =0.428 not significant)
2. Mean onset of musculocutaneous nerve sensory block was 4.80 and 4.38 in PN and PV groups respectively. (P value =0.241 not significant)
3. Mean onset of ulnar nerve sensory block was 6.98 and 10.89 in PN and PV groups respectively. (P value= <0.01 significant)
4. Mean onset of median nerve sensory block was 6.12 and 8.40 in PN and PV groups respectively. (P value= <0.01 significant)
5. The overall sensory onset time in perineural group is 6.98 minutes. The overall sensory onset time in

perivascular group is 10.96 minutes .(P value= <0.01 significant)

Motor Blockade

1. Mean onset of radial nerve motor block was 7.38 and 8.34 in PN and PV groups respectively. (P value =0.071 not significant)
2. Mean onset of musculocutaneous nerve motor block was 5.28 and 5.46 in PN and PV groups respectively. (P value =0.614 not significant)
3. Mean onset of ulnar nerve motor block was 10.22 and 13.50 in PN and PV groups respectively. (P value <0.01 significant)
4. Mean onset of median nerve motor block was 7.32 and 9.84 in PN and PV groups respectively. (P value <0.01 significant)

Overall Motor Onset Time: The overall motor onset time in perineural group is 10.22 minutes. The overall motor onset time in perivascular group is 13.50 minutes. The P value is <0.01 , statistically highly significant.

PN group had successful blockade with block percentage of 98% (49 patients) whereas only 46 patients in PV group had successful blockade with block percentage of 92%. P value is 0.362 which shows there is no statistical significance between the blockade techniques.

Duration of Sensory Blockade: The mean duration of sensory blockade in PN group was 446 minutes and that in PV group was 406 minutes. Measured P value is <0.01 and hence there exists highly significant statistical

difference between the two groups in regards the duration of the sensory blockade.

Duration of Motor Blockade: The mean duration of motor blockade in PN group was 389.70 minutes and that in PV group was 355.92 minutes. Measured P value is <0.01 and hence there exists highly significant statistical difference between the two groups in regards the duration of the motor blockade.

Table 1: Distribution of demographic profile (stats)

	PN	PV	p Value
Age	29.74	31.72	0.370
Gender			
Male	36	41	0.235
Female	14	9	
Weight	61.88	61.02	0.598

Table 2: Onset of sensory blockade (stats)

Nerve	Group	Total	Mean	P value
Radial	PN	50	5.76	0.428
	PV	50	6.12	
MCN	PN	50	4.80	0.241
	PV	50	4.38	
Ulnar	PN	50	6.98	<0.01
	PV	46	10.89	
Median	PN	50	6.12	<0.01
	PV	50	8.40	

Table 4: Onset of motor blockade

Nerve	Group	Mean	Total	P value
Radial	PN	7.38	50	0.071
	PV	8.34	50	
MCN	PN	5.28	50	0.614
	PV	5.46	50	
Ulnar	PN	10.22	50	<0.01
	PV	13.50	46	
Median	PN	7.32	50	<0.01
	PV	9.84	50	

	PN	PV	P value
Overall motor onset time	10.22	13.50	
Overall Sensory onset time	6.98	10.96	
Duration of sensory block	446	406	
Duration of Motor block	389.7	355.92	

	PN	PV
Vascular puncture	8	5
Paraesthesia	7	6

Complications

Incidence of accidental vascular puncture was 8 in PN group and 5 in PV group. Measured P value was 0.372 showing nil statistical significance existing between the two groups.

7 patients in PN group experienced paraesthesia and 6 patients in PV group experienced paraesthesia. Measured P value was 0.766 and hence no statistical difference exists between the two groups.

Discussion

Brachial plexus block is one of the most commonly performed peripheral nerve block. Brachial plexus blockade provides anaesthesia of the shoulder, arms, forearms and hands depending upon the approach of blockade. The various approaches to brachial plexus block includes interscalene, supraclavicular, infraclavicular and axillary. On account of its ease technique and higher success rate, axillary brachial plexus block is one of the preferred techniques in upper limb procedures.

In recent years, the introduction of ultrasound in performing the peripheral nerve block has become a boon to anaesthesiologists. Regional blocks under ultrasound guidance increases the effectiveness of the blockade, reduces onset time and reduces the rate of complications. Direct visualization of peripheral nerves and targeted drug injections has become possible with the help of ultrasound imaging.

Various injection techniques under ultrasound guidance for axillary brachial plexus block had been studied and described. Perineural, single or double perivascular injection techniques; multiple injection techniques under ultrasound guidance were few of them. Past studies have shown that perivascular technique can be a simple alternative to perineural technique as both have equal efficacy in terms of successful blockade as well as adverse effects. In our institute, the commonly practiced is perineural technique.

Cho S et al study compared perineural and single and double perivascular injection techniques for axillary block under ultrasound guidance in 78 patients of ASA I & II undergoing surgery of the upper limb. In their study PN group (n=26) received injections at the median, ulnar, and radial nerve with 8 mL for each nerve. The PV1 group (n=26) received a single injection of 24 mL at 12-o'clock position of the axillary artery. The PV2 group (n=26) received two injections of 12 mL each at 12-o'clock and 6-o'clock position. For all groups, musculocutaneous nerve was blocked separately. They showed that there was no differences in onset time. Which was contradictory to our study which showed significant early onset of sensory block especially in median and ulnar nerves. The average induction time was longer in PN group (673.4±149.6 sec) than PV1 (557.6±194.9 sec) and PV2 (561.5±129.8 sec). There were no differences in the success rate (89.7% vs. 86.2% vs. 89.7%). They had concluded that the PV technique is an alternative method to PN that may be used in busy clinics or for difficult cases.

In the study, Uday Ambi et al, "a prospective and randomized comparison between perineural and perivascular techniques under ultrasound guidance using levobupivacaine for axillary block" was done. Success rates [PN – 96.66% PV – 93.33%], motor onset, sensory onset and the total duration of anaesthesia were the same in both perivascular and the

perineural groups. Hence this study concluded that the perivascular technique was a simple alternative to the perineural technique.

In our study, calculated sample size was 100 based on the previous literature. The demographic profile was comparable.

On analyzing the primary outcome of this study, that is success rate of the blockade, success rate of the blockade in the perineural group was found to be 98% and in the perivascular blockade was 92%. The measured P value was 0.117 showing no statistical significance between the blockade techniques.

On analyzing the secondary outcome, the overall onset of sensory blockade and motor blockade was 6.96 minute and 10.26 minutes in perineural group and 11.02 minutes and 13.57 minutes in perivascular group respectively. The measured P value was < 0.01 showing highly significant difference between the two groups regarding the onset of sensory blockade and onset of motor blockade. The duration of sensory and motor blockade was 446 minutes and 389.70 minutes in perineural group and 406 minutes and 355.92 minutes in perivascular group respectively. The measured P value was < 0.01 showing highly significant difference between the two groups regarding the duration of sensory blockade and duration of motor blockade.

Complications such as incidence of accidental vascular puncture was 16% in perineural group and 10% in perivascular group with measured P value 0.372 showing statistically no significance existing between the two groups. 14% of patients experienced paraesthesia in perineural group and 12% of the patients experienced paraesthesia in perivascular group with measured P value of 0.766 which shows no significant statistical difference existing between the two groups.

The difference in the onset time of sensory and motor blockade of individual nerves in the perineural group can be attributed to the fact that sequential block of the individual nerve is in order of musculocutaneous, radial, median and ulnar nerves.

Conclusion

Ultrasound guided perineural technique of axillary block has relatively faster onset of blockade, longer duration of blockade and increased success rates compared to perivascular technique of ultrasound guided brachial plexus block. We conclude ultrasound guided perineural technique as more reliable than ultrasound guided perivascular technique of axillary block.

Financial Support and Sponsorship: Nil.

Conflicts of Interest: None.

References

1. Tran QH, Clemente A, Doan J, Finlayson RJ. Brachial plexus blocks: "A review of approaches and techniques". *Can J Anaesth*. 2007;54:662–674.
2. Bernucci F, Gonzalez AP, Finlayson RJ, Tran DQ. "A prospective, randomized comparison between perivascular and perineural ultrasound guided axillary brachial plexus block". *Reg Anesth Pain Med*. 2012;37:473–477.
3. Imasogie N, Ganapathy S, Singh S, Armstrong K, Armstrong P. "A prospective, randomized, double-blind comparison of ultrasound-guided axillary brachial plexus blocks using 2 versus 4 injections". *Anesth Analg*. 2010;110:1222–1226.
4. Serradell A, Herrero R, Villanueva JA, Santos JA, Moncho JM, Masdeu J. "Comparison of three different volumes of mepivacaine in axillary plexus block using multiple nerve stimulation". *Br J Anaesth*. 2003;91:519–524.
5. Aveline C. "Ultrasound-guided axillary perivascular approach: Efficacy and safety remain to be proved". *Reg Anesth Pain Med*. 2013;38:74.
6. Alakkad H, Chin KJ. "The importance of good needling technique in ultrasound-guided axillary block". *Reg Anesth Pain Med*. 2013;38:166.
7. Wong MH, George A, Varma M. "Ultrasound-guided perivascular axillary brachial plexus block": Not so simple. *Reg Anesth Pain Med*. 2013;38:167.
8. Swami SS, Keniya VM, Ladi SD, Rao R. "Comparison of dexmedetomidine and clonidine (α_2 agonist drugs) as an adjuvant to local anaesthesia in supraclavicular brachial plexus block": A randomised double-blind prospective study. *Indian J Anaesth*. 2012;56:243–249.
9. Tran DQ, Pham K, Dugani S, Finlayson RJ. "A prospective, randomized comparison between double-, triple-, and quadruple-injection ultrasound guided axillary brachial plexus block". *Reg Anesth Pain Med*. 2012;37:248–253.
10. Pfeiffer K, Weiss O, Krodel U, Hurtienne N, Kloss J, Heuser D. "Ultrasound-guided perivascular axillary brachial plexus block. A simple, effective and efficient procedure". *Anaesthesist*. 2008;57:670–676.
11. González AP, Bernucci F, Pham K, Correa JA, Finlayson RJ, Tran DQ. "Minimum effective volume of lidocaine for double-injection ultrasound-guided axillary block". *Reg Anesth Pain Med*. 2013;38:16–20.
12. O'Donnell BD, Iohom G. An estimation of the minimum effective anesthetic volume of 2% lidocaine in ultrasound-guided axillary brachial plexus block. *Anesthesiol*. 2009;111:25–29.
13. Cho S, Kim YJ, Kim JH, Baik HJ. "Double-injection perivascular ultrasound-guided axillary brachial plexus block according to needle positioning: 12 versus 6 o'clock position of the axillary artery". *Korean J Anesthesiol*. 2014;66:112–119.
14. Sites BD, Taenzer AH, Herrick MD, Gilloon C, Antonakakis J, Richins J, et al. "Incidence of local anesthetic systemic toxicity and postoperative neurologic symptoms associated with 12,668 ultrasound-guided nerve blocks: An analysis from a prospective clinical registry". *Reg Anesth Pain Med*. 2012;37:478–482.
15. Tran DQ, Bernucci F, González AP, Finlayson RJ. Reply to Dr Aveline. *Reg Anesth Pain Med*. 2013;38:75.

How to cite this article: Padmini, Sevagamoorthy, Rajaprabhu. A prospective randomized comparison between perivascular and perineural ultrasound guided axillary brachial plexus block for upper limb surgeries. *Indian J Clin Anaesth*. 2018;5(4):512-517.