

## Enigma to the endodontist: A case report of mandibular first premolar with two roots and root canals

Shalini Singh<sup>1</sup>, Nitin Mirdha<sup>2</sup>, Rahul VC Tiwari<sup>3,\*</sup>, Kritika Sehrawat<sup>4</sup>, Yesh Sharma<sup>5</sup>

<sup>1,4,5</sup>PG Student, <sup>2</sup>Associate Professor, <sup>3</sup>Fellow, <sup>1,2,5</sup>Dept. of Endodontics, <sup>3,4</sup>Dept. of Oral & Maxillofacial Surgery, <sup>1,2</sup>Vyas Dental College Jodhpur, Rajasthan, <sup>3</sup>Jubilee Mission Medical College & Research Centre, Thrissur, Kerala, <sup>4</sup>Sudha Rustagi College of Dental Sciences & Research, Faridabad, Haryana, <sup>5</sup>Maharaja Ganga Singh Dental College & Research Centre, Ganga nagar, Rajasthan, India

**\*Corresponding Author:**

Email: drrahulvctiwari@gmail.com

### Abstract

Mandibular first premolar is often considered as enigma to endodontist. Though most frequent type of tooth configuration reported is the presence of one root and root canal. This case report enlightens the prime aspects of diagnosis and endodontic management of an aberrant configuration with respect to mandibular first premolar. A variation in number of roots as well as canal morphology is not scarce. According to various studies on anatomic configuration 1.8% of mandibular first premolar showed two roots. Root canal morphology can be unpredictable and requires cautious assessment for root canal therapy. This article reports a clinical case of mandibular first premolar with two roots and root canals treated successfully with endodontic therapy.

**Key words:** Mandibular first premolar, Aberrant morphology, Endodontic management.

### Introduction

Slowly in a study reported mandibular premolars as “endodontist’s enigma”, may present the utmost difficulty of all teeth to execute successful endodontic treatment.<sup>1</sup> A detailed knowledge of root canal system and its variations, intensive chemo-mechanical planning followed by 3D obturation of root canal system is required for effective treatment.<sup>2</sup> In a study on Indian population a higher occurrence of two canals in mandibular first premolars was accounted in several populations, which when reported was upto 50%.<sup>3</sup> In studies on anatomical and morphological configurations of mandibular first premolars it was reported that 23-30% are more prone to bifurcation of canals and 15-20% terminating in multiple apical foramina.<sup>4</sup>

### Case Report

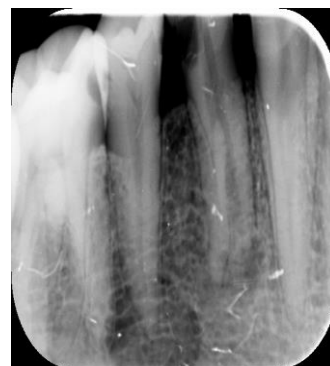
A 35 year old male patient reported to Department of conservative dentistry and endodontics with chief complaint of pain in lower right back region of teeth since 10 days. Clinical examination suggested deep carious lesion with tooth no. 44. Electric pulp testing suggested the tooth to be non-vital. Radiographic assessment revealed carious lesion extending to pulp with an aberrant root anatomy i.e. two roots (mesial and distal) with no periapical changes (Fig. 1).

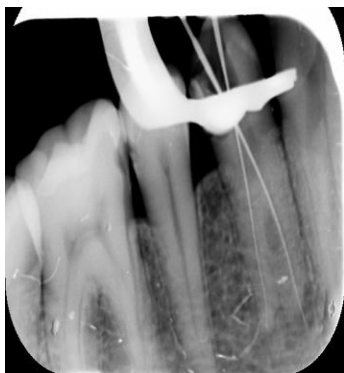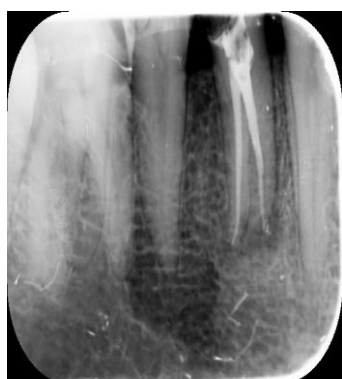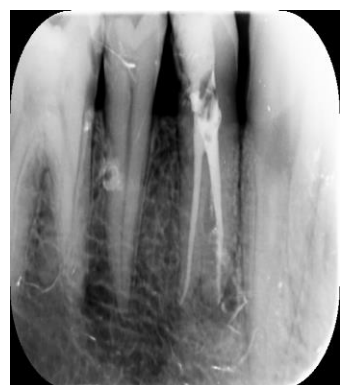
On examination diagnosis of irreversible pulpitis with tooth no. 44 was made necessitating endodontic treatment.

Pre-endodontic buildup using composite restoration was done. Isolation of tooth was done using rubber dam. Endodontic access cavity was prepared using endo access bur. A sharp DG16 explorer was utilized to locate the canal orifices, and the access was

modified accordingly. Pulp extirpation was done and canal patency was maintained, size 10k system (Dentsply-Maillefer) files were inserted and working length determined using radiograph and affirmed utilizing Propex II apex locator (Fig. 2).

Chemo-mechanical preparation was performed using ProTaper Gold File system (Dentsply-Maillefer). Irrigation was done alternatively after every instrument change using 5% sodium hypochlorite solution and 17% EDTA (Ethylenediaminetetraacetic acid). Apical preparation for both the canals was done till F1 size for, closed dressing was given after completion of chemo-mechanical preparation and patient was reappointed after three days for obturation. In follow-up appointment as the tooth was completely asymptomatic master cone radiograph was taken. The canals were dried by paper point. Obturation was done using corresponding ProTaper F1 cones; sealapex sealer (Kerr, SybronEndo). Radiograph after obturation is taken (Figure 3). Post-obturation restoration was done using composite (Filtek Z250, 3M, ESPE) and post-operative radiograph was taken (Fig. 4).



**Fig. 1: Pre-operative diagnostic radiograph****Fig. 2: Working length determination radiograph****Fig. 3: Radiograph after obturation****Fig. 4: Radiograph with post-obturation restoration****Table 1: Incidence (%) of number of roots in the mandibular second premolar**

Anatomic Studies	1 Root (%)	2 Roots (%)	3 Roots (%)
Barrett (1925)	100	-	-
Zilich and Dowson (1973)	96.6	-	0.4
Vertucci (1978)	100	-	-
Geider et al (1989)	97.6	0.4	-
Zaatar et al (1997)	95.6	4.7	-
Sert and Bayiril (2004)	100	-	-

### Conclusion

It is a well established undeniable fact that the presence of additional roots and root canals in these teeth could also be much more than one can expect.

### Discussion

Missed roots and root canals are the foremost important reason for endodontic failure is due to the presence of variant anatomy. The occurrence of additional roots or canals in mandibular premolars is certainly an endodontic challenge.<sup>5</sup> Scott and Turner in a study illustrated the presence of accessory root of mandibular first premolar as TOME'S ROOT.<sup>6</sup>

As indicated by the study done by Green et al. frequency of two roots, two foramina is reported to be 4%.<sup>7</sup> Radiographic evaluation should be done carefully to check for the shape, position, and relative root outline of the teeth. Multiple radiographs taken from different angulations will uncover the genuine measurements and variations of root canals, tooth that shows broad, flat roots probably have multiple canals and intracanal ramifications. A sudden radiographic vanishing of a canal can be an expectation of a dividing canal. The elucidation of the periodontal ligament space may propose the presence of an extra root or canal.<sup>8</sup> X-ray angle deviation from the vertical axis of 15°-30° was efficient in the mandibular first premolar in helping to visualize canal anatomy. Sudden narrowing of the primary canal on the radiograph was a descent criterion to judge root canal multiplicity was demonstrated in a study by Yoshioka et al.<sup>9</sup>

Previous studies on anatomy of tooth that included 4019 teeth report on data for the number of roots in the mandibular second premolar (Table 1).

Undoubtedly, these findings are clinically essential as in a study by Ingle JI in 2003 at the University of Washington evaluating the consequences of endodontic treatment, out of all the types of teeth present in oral cavity the mandibular first and second premolars reported to have a failure rate of 11.45 and 4.54% respectively.<sup>10,11</sup> Conceivably, these findings could be attributable to the complex anatomy and morphology of a large number of these teeth. Inability to recognize the presence of additional root or canals can typically source failure of endodontic treatment.<sup>12</sup>

Careful elucidation of the radiograph, thorough clinical inspection of the floor of the chamber and proper modification of the access opening, the position, and angulations of the file in the canal in addition hints

regarding the presence of extra canal and are essential for a successful treatment outcome. Dental loupes operating microscope and CBCT can also be used as adjunct for identification of additional root and root canal.

## References

1. Ingle JI. A standardized endodontic technique utilizing newly designed instruments and filling materials. *Oral Surg Oral Med Oral Pathol* 1961;14:83-91.
2. De Deus QD. Frequency, location, and direction of the lateral, secondary, and accessory canals. *Endod J* 1975; 1(11):361-6.
3. Sandhya R, Velmurugan N, Kandaswamy D. Assessment of root canal morphology of mandibular first premolars in the Indian population using spiral computed tomography: an in vitro study. *Ind J Dent Res* 2010;21(2):169-73.
4. Jojo Kottoor, Denzil Albuquerque, Natanasabapathy Velmurugan, Jacob Kuruvilla. Root Anatomy and Root Canal Configuration of Human Permanent Mandibular Premolars: A Systematic Review. *Anat Res Int* 2013;254250.
5. Messer HH. Clinical judgment and decision making in endodontics. *Aust Endod J* 1999;25(3):124-32.
6. Scott R, Turner C. The anthropology of modern human teeth. Cambridge: Cambridge university press, 2000.
7. Kishore Raju Kothapalli. Two-rooted mandibular first premolar: case report. *Ann Essences Dent* 2010, II(3).
8. Hulsmann M. Mandibular first premolar with three root canals. *Endod Dent Traumatol* 1990;6:189-91.
9. Cleghorn BM1, Christie WH, Dong CC. The root and root canal morphology of the human mandibular first premolar: a literature review. *Endod J* 2007;33(5):509-16.
10. Barrett M. The internal anatomy of the teeth with special reference to the pulp and its branches. *Dent Cosmos* 1925;67:581-92.
11. Vertucci FJ. Root morphology of mandibular premolars. *J Am Dent Assoc* 1978;97(1):47-50.
12. Zilich R, Dowson J. Root canal morphology of mandibular first and second premolars. *Oral Surg Oral Med Oral Pathol* 1973;36(5):738-44.