

External fixator and K wire- A versatile tool in distal end radius fractures

Kaushal Anand¹, Hriday Acharya^{2*}, Satvik Patel³, Shalin Shah⁴

¹Assistant Professor, ²⁻⁴Resident, Dept. of Orthopaedics, ¹⁻³Civil Hospital Ahmedabad, ⁴Surat Municipal Institute of Medical Education and Research, Surat, Gujarat, India

***Corresponding Author**

Email: hridayacharya21@gmail.com

Abstract

Introduction: Distal end of the radius fractures are common injuries and are the commonest bony injury around the wrist. The logical treatment need to be planned based on specific fracture configuration, the extent of displacement, degree of articular disruption, stability and many other factors. The present study is intended to assess results of closed reduction, K wiring and external fixator in Fractures of Lower end Radius/ulna in 40 patients classified according to Frykman's classification.

Materials and Methods: This is a retrospective study of 40 cases of distal end radius fractures selected randomly over a period one year from March 2016 to March 2017.

Observation and Results: Out of 40 patients in the study most of them were male with the mean age of patients being 44.72. Injury was commonly due to fall on out stretched hand with no associated injuries signifying it is caused by low energy trauma. Most of the patients were of Frykman type III and IV. The average period for intermittent mobilization is between 6 to 7 weeks. 90% patients have 10-22 degrees of range of radial inclination. Most patients developed a good range of movement post-op. Few complications were reported with pin tract infection being present in 5% cases.

Conclusion: We have studied 40 patients of distal end radial fracture treated with external fixator and K wires. It is simple and inexpensive implant. Technique is less demanding for surgery. It causes minimal soft tissue interference. Elbow and fingers can be mobilized immediate post operatively. It maintains reduction and provides stability to fracture fixation. Period of immobilization was short. Complication rates are comparatively low in our study. Most patients had excellent to good results. Its ease of use and successful results make external fixator and K wire versatile tool for treatment of these fractures.

Keywords: Distal end radius, External fixator, K wires.

Introduction

Having been recognized for nearly two centuries, distal end of the radius are common injuries and are the commonest bony injury around the wrist, the most effective method for the fixation of an intra-articular distal radial fracture has not been established. Fractures of the distal radius recently have become the focus of interest regarding optimal management. Formerly consider injuries occur principally in the elderly. These fractures are now acknowledged as serious disruptions of wrist anatomy, with a considerable incidence of complications that affect a much larger segment of the populations. Increased awareness of distal radius fractures has led to the emergence of a substantial change in concepts that rational treatment should incorporate.

Prominent among these concepts is that functional recovery closely parallels the accuracy of anatomical restoration. Moreover for the most frequently occurring intraarticular and severely comminuted fractures and open injuries, preservation of distal radial articular contour in many cases can be achieved by k wiring and external fixation, is a prerequisite for successful recovery.

Residual joint incongruity of seemingly minimal extent is prone to the inevitable development of disabling arthritis. Furthermore it is increasingly evident that well convinced treatment for the diverse but now a day's incidence in young patients are increasing and spectrum of distal radius fractures is

reliable upon strict definition of specific fracture configuration. The extent to displacement, the degree of articular disruption, the stability and the reducibility of each fracture, as well as any concurrent injury to adjacent nerves, tendons or carpal structures must be assessed carefully in the planning of logical treatment. Clearly, optimal management requires an accurate recognition and repair of concomitant injuries and early rehabilitation in form of active and passive acceptable range of movement.

The present study is intended to assess results of closed reduction, K wiring and external fixator in fracture lower end radius/ulna in 40 patients classified according to Frykman's classification.

Table 1: Frykman classification of distal radius fracture

Fractures	Distal ulnar Fracture Absent	Distal Ulnar Fracture Present
Extra-articular	I	II
Intra-articular involving Radiocarpal joint	III	IV
Intra-articular involving Radioulnar joint	V	VI
Intra-articular involving Radiocarpal and radioulnar joints	VII	VIII

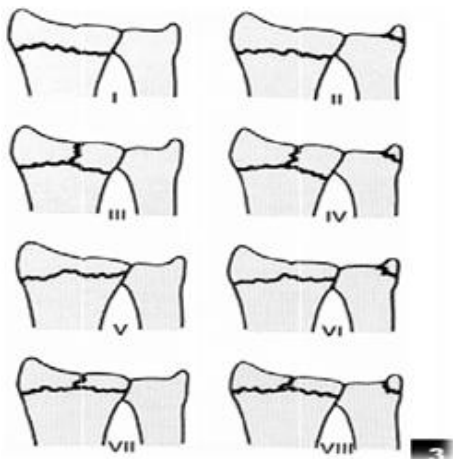


Fig. 1: Frykman Classification of fracture of distal end of radius

Normal anatomic relationships

Radial inclination: Averages 23 degrees (range, 13 to 30 degrees)

Radial length: Averages 12 mm (range, 8 to 18 mm)

Palmar (volar) tilt: Averages 11 to 12° (range, 0 to 28 degrees)

The 0-degree capitulunate angle: a straight line drawn down the third metacarpal shaft, capitate, lunate, and shaft of radius with wrist in neutral position

The 47-degree scapholunate angle (normal range, 30 to 70 degrees); less than 2 mm scapholunate space

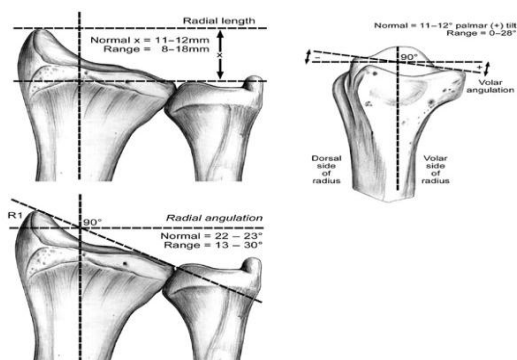


Fig. 2: Normal anatomical relationship

Aims and Objectives

1. To study fracture patterns of distal end radius fractures.
2. To study the results of closed reduction, K Wiring and external fixator in treatment of fracture distal end radius.
3. To evaluate treatment related complication.
4. To find out basis for selecting the method of treatment for fracture distal end radius.
5. Functional outcome

Materials and Methods

This is a retrospective study of 40 cases of distal end radius fractures selected randomly over a period one year from March 2016 to March 2017. All patients were followed up for a period 6 months post operatively.

Fracture patterns were classified on Frykman classification.

Inclusion Criteria

1. Skeletally mature patients
2. All patients of distal radius fracture with open/closed, extra articular/intra articular
3. Injury less than 2 weeks old

Exclusion Criteria

1. Skeletally immature
2. Pathological fractures other than osteoporosis
3. Uncooperative patients
4. Patients no willing for the surgery

Techniques used

External Fixation: Limited open surgical approached for prevention of damage to delicate soft tissues are present in forearm and hand.

On simple table, arm rest, supine position under anesthesia. Tourniquet not required. Painting and draping had done. Closed reduction done under C-Arm and fixed with 2 to 3 percutaneous K wire from the tip of radial styloid and anchored into the ulnar side of more proximal shaft fragment. If required additional percutaneous K-wires were put through radial styloid fragment directly under subchondral bone to provide subchondral support. This technique involves two 0.5 cm (stab) incisions - one centered approximately 10cm proximal to the radial styloid overlying radial aspect of the forearm and one overlying dorsoradial aspect of the base of the 2nd metacarpal. After stab incision artery forceps used for blunt dissection upto the bone surface. With use of drill sleeve drilling has done with 2.5 mm drill bits. Two 3.5 mm schanz pins were inserted in radius approximately three fingers apart.

Two 2.5 mm Schanz pins were inserted one in base of second and third metacarpal bases and one in proximal shaft of second metacarpal alone.

After putting Schanz pins soft tissues were allowed to fall back and skin approximated with simple sutures if needed. Then distraction rod was applied. Prereduction was done and maintained before putting Schanz pins. After distraction the fixation device was locked and reduction was assessed under C-arm. Sterile dressing applied.

The fixation was further augmented with k-wires and infrequently using bone grafts as and when required.

Timing of Surgery: Surgery can be done within one week. After 21 days fibrous tissues develops and can compromise reduction. After that period open reduction may required and bone grafting/osteotomy can be needed.

Post-operative care and Rehabilitation: Immediate post op check x-ray should be done in both AP & Lateral view to confirm reduction.

Fingers, elbow and shoulder mobilization started on post-operative day. Patient advised exercise on discharge. Check for implant loosening or pin tract infection at follow up Check x ray done after 1.5 months and see for union. Follow up done at 1.5 month, 3 month & 6 month. Range of motion and deformity checked

Observation and Results

In this study 18 (%) patients are of older age group 51-70 year age group. In this study 17 (%) patients are of 20 to 40 years age group. Mean of age was 44.92. This study shows DER fractures are also becoming common in younger age group. Most of the patients are male, may be due to more outdoor work for earning. No difference was found between dominant or non-dominant extremity. 70% of the patients are injured due to fall on out stretched hand & 30% are due to RTA. 80% patients have no associated injuries and 20% have associated injuries. Signifies that this fractures caused by low energy trauma in elders. Most patients are of type III and IV. Type I and VII are less in numbers. For other type ratio are somehow same. Average period for intermittent mobilization of wrist with fixator and K wires in situ by dynamising fixator between 6 to 7 weeks. Average period for external fixator and K wires removal is around 9 weeks. Wrist and fingers mobilization exercises started. Follow up patients are done at every week until ROS, then every month for consecutive 3 months, then at 6 months were done. On each follow up, condition of fixator and possibilities of complication being checked. At 6 months clinical and radiological assessment was done. Radiological assessment of radial inclination, radial shortening and palmer tilt evaluated according to Sarmiento's modification of Lind Storm criteria. In this study 90% patients have 10-22 degrees of range of radial inclination. In our study total 85 % patients have found acceptable results for decrease radial height. In study total 77.5% patients have found excellent or good results for palmar tilt. According to Sarminto score 80% patients had excellent to good result, 15% had fair, and 5% had poor results. Average movements achieved in this study for palmar flexion was 72.62, dorsiflexion was 72.87, supination 77, pronation 77.62, radial deviation 11.35, ulnar deviation 20.95. 25% patients

have ulnar prominence.5% patients have pin tract infection. Only 1 patient had dinner fork deformity due to mal union. In this study 82.5% patients had excellent and good results. 17.5% patients had fair to poor results

Discussion

Distal end radius fractures are common injuries around wrist in upper limb. Effective method for the fixation of distal radial fractures is demanding due to complex fractures patterns. This study is essentially preliminary assessment. This study is only short term follow up with average of 6 month The aim of this study is to evaluate the results of external fixator and K wires for DER fracture. We have studied 40 patients of D/E/R fracture treated by k wire and external fixator device. In our study patients mean age is 44.92 and it ranges from 20 to 70 years with as compared with Aggrawal et al study was 45. In our study most patients were male and mode of injury was fall in 70% of patients. The results of mode of injuries are also comparable with Nagi et al (2004), which also had high incidence in males. In our study 2 (5%) of fractures were open injuries. Thus incidence of open injury for this fracture is low as compared to closed fractures. Associated injuries found to be 20% with this fractures, concluded that these injuries are not so high energy trauma were comparable with Gunaki RB et al (1999). Average period for immobilization was around 6 to 7 weeks, which is as compared to around 7.2 weeks advised by Nagi et al. We studied 40 patients in which Frykman type III and IV are around 35% and type 5 and 6 are around 10-15% and comparable with other studies. Radial length is crucial for good wrist function. Loss of 4-6 mm radial length may compromise DRUJ. In our study average loss of radial height was 3.084 mm. It is higher than the study by David Wei (2009) which was 2.13 mm. Average volar tilt in our study was 6.75 as compared to 8.4 in David Wei's (2009) study. Average radial inclination in this study was 16.27 compared to 17.5 in David Wei's study. Ranges of movements are also compared with other studies and approximately same results obtained. Dorsi flexion, palmar flexion, supination, pronation are higher in our study as compared to David wei. Functional results from Gartl and and Werely scoring system, our study results are approximately similar as compared to study of Cooney et al and Nagi et al.

Table 2: Classification of fractures

Frykman Classification	Our Study (%)	Cooney 1979 (%)	Nagi 2004 11 (%)	Aggrawal 2004 (%)	David Wie ¹⁸ 2009 (%)
I	0	51	0	0	0
II	12.5	7	0	1.08	0
III	30	5	0	20.6	8.5
IV	25	12	0	21.7	11.4
V	12.5	10	10	3.2	5.7

VI	10	13	16.6	4.3	2
VII	12.5	20	33.3	25	17.1
OVIII	2.5	28	40	24	57.1
Total Cases	40	60	30	92	35

Table 3: Comparison of range of Movement

Movements	Our study	David Wei (2004)	Minimal for function (Sarminto 1975)	Normal range
Palmar flexion	72.62	63	30	85
Dorsi flexion	72.87	66	45	85
Supination	77	68	50	90
Pronation	77.62	68	50	90
Radial deviation	11.35	11	10	15
Ulnar deviation	20.95	33	15	30

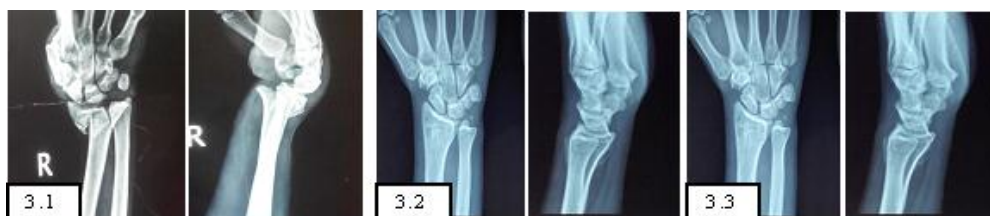Table 4: Comparison of functional results

Study group	Excellent to Good (%)	Fair to Poor (%)	Total no. of patients
Cooney et al	85%	15%	130
Nagi et al	74.28%	25.72%	35
Our study	82.5%	17.5%	40

Conclusion

We have studied 40 patients of distal end radial fracture treated with external fixator and K wires. It is simple and inexpensive implant. Technique is less demanding for surgery. It causes minimal soft tissue interference. Elbow and fingers can be mobilized immediate post operatively. It

maintains reduction and provides stability to fracture fixation. Period of immobilization was short. Complication rates are comparatively low in our study. Most patients had excellent to good results. Its ease of use and successful results make External Fixator and K wire versatile tool for treatment of these fractures.

Case 1: 25 year male patient had history of RTA**Fig 3.1: Preopxray****Fig 3.2: Post-op xray****Fig. 3.3-6: Month follow up****Fig 3.4: Clinical photographs****References**

- Colles, A.: On the Fracture of the Carpal Extremity of the Radius. *Edinburgh Med. And Surg. J.*, 10:182-186,1814.
- Gartland Jj Jr, Werley Cw. Evaluation of Healed Colles' Fractures. *J Bone Joint Surg Am.* 1951;33:895-907.
- Bohler, Lorenz: Treatment of Fractures. Ed. 4. Baltimore, William Wood and Co., 1929.
- Anderson, Roger, and O'Neil, Gordon: Comminuted Fractures of the distal end of the Radius. *Surg., Gynec. And Obstet.*, 78:434-440, 1944.
- De Palma, A. F.: Comminuted Fractures of the Distal end of the Radius Treated by Ulnar Pinning. *J. Bone and Joint Surg.*, 34-A:651-662, July 1952.
- Cooney, W. P., Iii; Linscheid, R. L.; and Dobyns, J. H.: External Pin Fixation for Unstable Colles' Fractures. *J. Bone and Joint Surg.*, 61-A:840-845, Sept.1979.

7. Clyburn Ta. Dynamic External Fixation for Comminuted Intra-Articular Fractures of the Distal end of the Radius. *J Bone Joint Surg Am.* 1987;69:248-54.
8. K.-D. Werber, Md, F. Raeder, Md, R.B. Brauer, Md, and S. Weiss, Md: External Fixation of Distal Radial Fractures: Four Compared with Five Pins the *Journal of Bone & Joint Surgery: Jbjs.Org* Volume 85-A Number 4 April 2003.
9. Kapoor H, Agarwal A, Dhaon Bk. Displaced Intra-Articular Fractures of Distal Radius: A Comparative Evaluation of Results Following Closed Reduction.
10. External Fixation and Open Reduction with Internal Fixation. *Injury.* 2000;31:75-9.
11. Akmaz I, Pehlivan O, Kiral A, Short Term Results of External Fixation of Unstable Distal Radius Fractures. *Acta Orthop Traumatol Turc.*2003; 37(2):126-132.
12. Nagi On, Dhillon Ms, Aggrawal S, External Fixators for Intra Articular Distal Radius Fractures. *Indian Journals of Orthopaedics,* 2004;38:19-22.
13. Arora J, Kapoor H. Closed Reduction and Plaster Cast Immobilization Vs External Fixation in Comminuted Intra Articular Fractures of Distal Radius. *Indian Journals of Orthopaedics* 2004;38:113-117.
14. Atroshi I, Brogren E, Larsson Gu, Kloow J, Hofer M, Berggren Am. Wrist Bridging Versus Non-Bridging External Fixation for Displaced Distal Radius Fractures: A, Randomized Assessor-Blind Clinical Trial of 38 Patients followed for 1 Year. *Acta Orthop.* 2006; 77: 445-53.
15. Cooney Wp, Bussey R, Dobyns Jh, Linscheid Rl. Difficult Wrist Fractures. Perilunate Fracture-Dislocations of the Wrist. *Clin Orthop Relat Res.* 1987;214:136-47.
16. Frykman. G.: Fracture of the Distal Radius Including Sequelae - Shoulder. Hand Finger Syndrome, Disturbance of the Distal Radio-Ulnar Joint and Impairment of Nerve Function. A Clinical and Experimental Study. *Acta Orthop. Scandinavica, Supplementum* 108.1967.