

Analysis of Functional Outcome of Conservative versus Surgical Management by Plating in Mid-Third Clavicle Fractures

Biswajit Sahu^{1,*}, B.N.Mohapatra², Dillip Kumar Chand³

^{1,2}Associate Professor, ³Junior Resident, Dept. of Orthopaedics, VIMSAR, Burla, Odisha

***Corresponding Author:**

Email: drbiswasahu@yahoo.com

Abstract

Displaced middle third clavicle fractures have always posed a therapeutic challenge to the orthopaedic surgeons. Incidence of these fractures varies from 2.6–4% in adults. Majority (about 80%) of the clavicle fractures occurs in middle third. Despite this high numbers, proper treatment is still controversial. The aim of this study is to evaluate the rate of union in mid-third fractures of the clavicle treated by non-operative methods and by clavicular plating, to determine the complications and to Compare the functional outcomes of displaced fracture of the middle third of clavicle treated with non-operative and surgical management by plating. This is a prospective study in which 50 cases of displaced mid-shaft fractures of clavicle were treated randomly. 25 cases were operated with internal fixation by plate osteosynthesis and 25 patients were followed with conservative management. Functional evaluation was conducted at regular interval with the use of the constant murley scores. Union was evaluated clinically and radio graphically. In the non-operative group 21 cases (84%) united, while 4 cases (16%) went on to non-union and the mean constant score was 84.48 ± 7.8 . In the Operative group, 96% union rate was found and the mean constant score was 93.72. To Conclude, Excellent functional outcomes, earlier return to daily activities, decrease incidence of nonunion can be achieved with surgical management of displaced clavicle fractures compared with non-operative treatment.

Keywords: Clavicle, ORIF, Constant and Murley Score, Plating.

Introduction

Clavicle fracture is one of the most common bony injury. Incidence of these fractures varies from 2.6–4% in adults. Majority (about 80%) of the clavicle fractures occurs in middle third because thinnest part of bone, junction of two curves of shaft and site of entrance of nutrient artery. Despite these high number of fractures proper treatment is controversial and is a debatable issue. Most of clavicle fractures have traditionally been treated non-operatively by figure of -8- bandage or by sling. The traditional conservative protocol provides good results in more than 90% of the patients. However recent literature have shown the increase risk of nonunion and malunion. Operative management of clavicle fracture includes osteosynthesis with plate and screw or intramedullary fixation. Operative treatment results in accurate anatomical reduction, quick pain relief, early mobilization and good functional outcome.

The aim of our study is to:

1. To analyse the result of conservative management of displaced mid shaft clavicle fracture.
2. To analyse the result of surgical treatment by plating.
3. To compare the functional outcomes of displaced fracture of the middle third of clavicle treated with non-operative and surgical management by plating.

Materials and Methods

This prospective study was conducted in the PG Department of Orthopaedics, VIMSAR, Burla. Patients were selected randomly from patients attending outpatient department and emergency Department of Orthopaedics from November 2014 to October 2016. Out of the 50 cases of displaced middle third fractures

of clavicle, 25 cases were operated with internal fixation with plate (Plate group), and 25 patients were followed with conservative treatment. (Cons. group)

Inclusion criteria:

1. Age <60 years and >18 years
2. Isolated displaced middle third fracture of clavicle
3. Medically fit for surgery

Exclusion criteria:

1. Age >60 yrs and <18 yrs
2. Medial and lateral third clavicle fracture
3. Undisplaced fracture of clavicle,
4. Open fracture and comminuted fracture
5. Pathological fracture
6. Medically unfit for surgery
7. Poly trauma patient
8. Medical comorbid conditions
9. Patients with neurovascular injury

Surgical Approach: With the patient in supine position, a sand bag was placed between the medial border of the scapula and the spine. Surgery was done under general anesthesia. An incision was made in the anterior part over clavicle centering on the fracture site. The skin, subcutaneous tissue, platysma, and overlying fascia, were separated. Fractures fragments identified and reduced under vision. The pre contoured clavicular plate was applied over the superior aspect of the clavicle taking care not to injure the underlying neurovascular structures. The plate was fixed with three 3.5 mm screws each in the medial and lateral fragment. Any large fragments were temporarily reduced with clamps or K-wires. Comminuted fragments secured with lag screws wherever possible. The wound was closed in layers after putting the negative suction drain. Stitches were removed in 12th days after surgery.

Pendulum range of motion exercises were started as soon as pain allowed, usually after 3-4 days, with limb supported in arm sling. Passive motion exercises were initiated within 6 weeks.

Conservative versus Surgical treatment: Non-surgical management with sling or figure-of-8 bandage is appropriate for nearly all clavicle fractures in children because of their excellent healing and remodeling capability. In 1960 Neer et al, Rowe et al showed that non-operative treatment gives good result in terms of nonunion <1% compared to operative treatment (non-union approx.=4%). However some recent studies found nonunion and malunion upto 20% in conservative treated group. The advantage of ORIF and early mobilization of displaced clavicle fracture gives quick pain relief and prevents the shoulder stiffness, symptomatic mal-union, and nonunion, thus, resulting in better functional outcome.

Follow up and functional outcome: Patients were regular follow up at 3 week, 6week, 3 month, 6 month, 1 year. Shoulder range of movement (pendulum exercises) were advised to each patients. In each visit X- ray was taken. Functional outcome was evaluated using the Constant Shoulder Score, ranging from 0 - 100, with a lower score representing a higher level of functional disability.

Constant Shoulder Score:

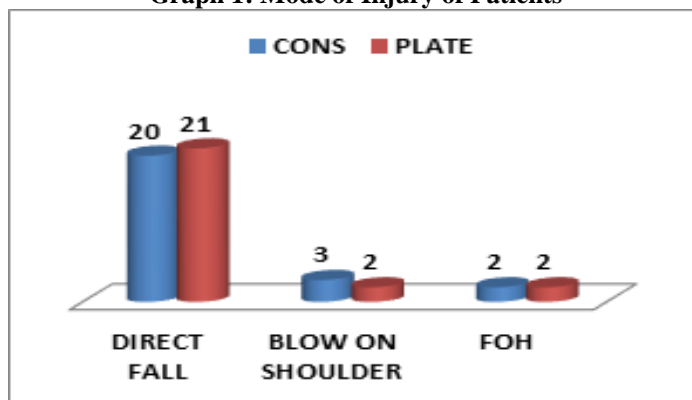
Total score Outcome	
90-100	Excellent
80-89	Good
70-79	Fair
0-70	Poor

Results

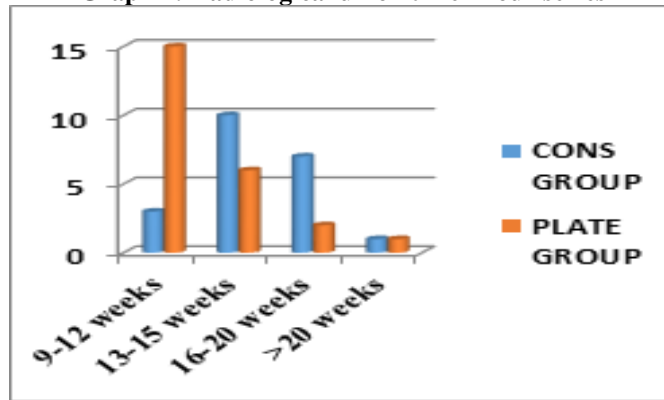
Non-operatively Managed Group (Cons group): There were 18 male patients and 7 female patients (Cons. group) in between age 20 to 60 years and the mean age is 33.28±10.73 years. Left side is affected in 76% of cases. 80% of fracture are due to direct fall on the shoulder, 15% are due to direct blow to the clavicle and 5 % had a fall on the outstretched hand (Fig. 1). The fractures were treated by clavicular brace and followed by serial x-rays. Clinically and radiologically union was noted in 84% cases while 16% went on to non-union. Pain on activity complained by 20% patients, 10% complained of transient paresthesia. Functional outcome were assessed by constant and murley score.

Operated Group (Plate group): There were 18 males and 7 females age in between 20 to 60 years and the mean age is a 34.76±11.87 years. Left side (52%) affected more than the right side (48%). Mechanism of fracture of 90% patients are due to direct fall on the shoulder, 5 % due to direct blow on the clavicle and 5% have a fall on the outstretched arm (Graph 1). Both radiological and clinical union was found in 96% of cases. Patients were followed with serial x-rays at regular interval. One case (4%) develop non-union which is treated by iliac crest bone grafting. 16% of patients complained of pain during activity, 8% had superficial wound infection which subsided with brodspectrum antibiotics after culture and sensitivity. Two cases (8%) complained of hardware irritation and 12% had hypertropic scar. Functional assesment were done by constant and murley scores. 76% patients shows excellent results and 16% shows poor results.

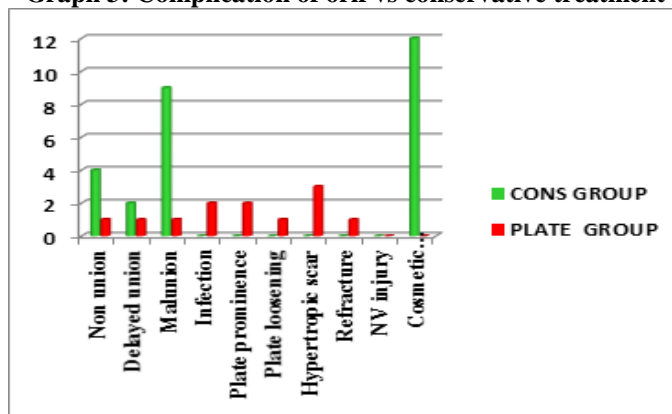
Graph 1: Mode of Injury of Patients



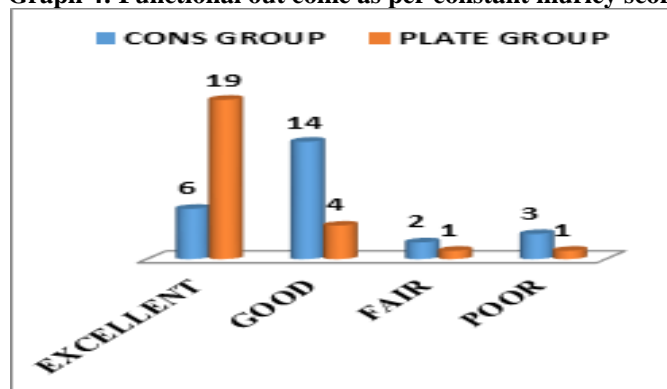
Graph 2: Radiological union time in our series



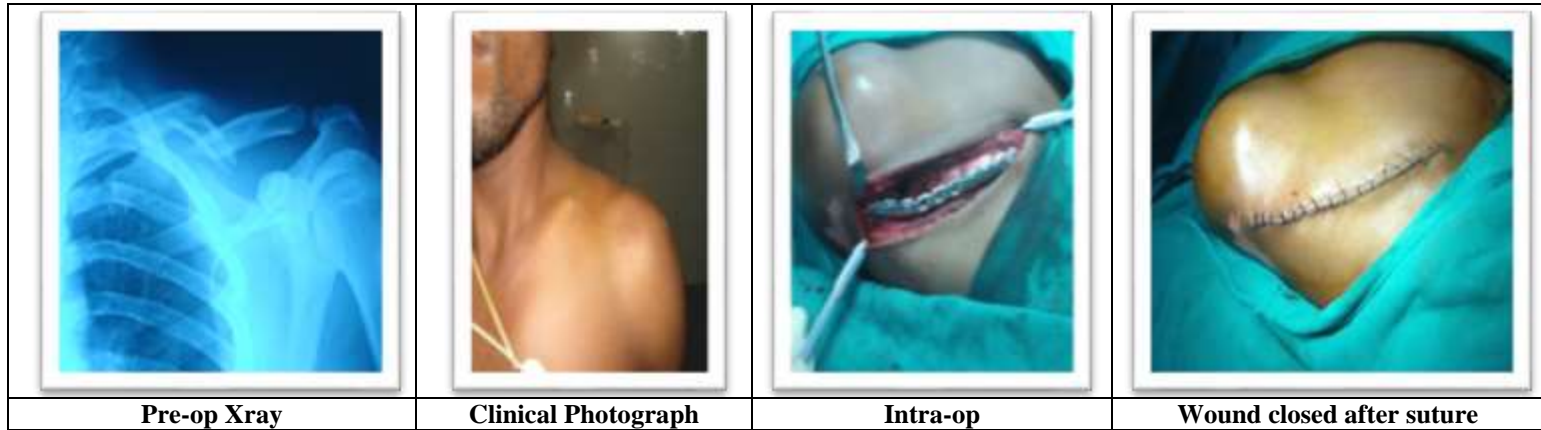
Graph 3: Complication of orif vs conservative treatment



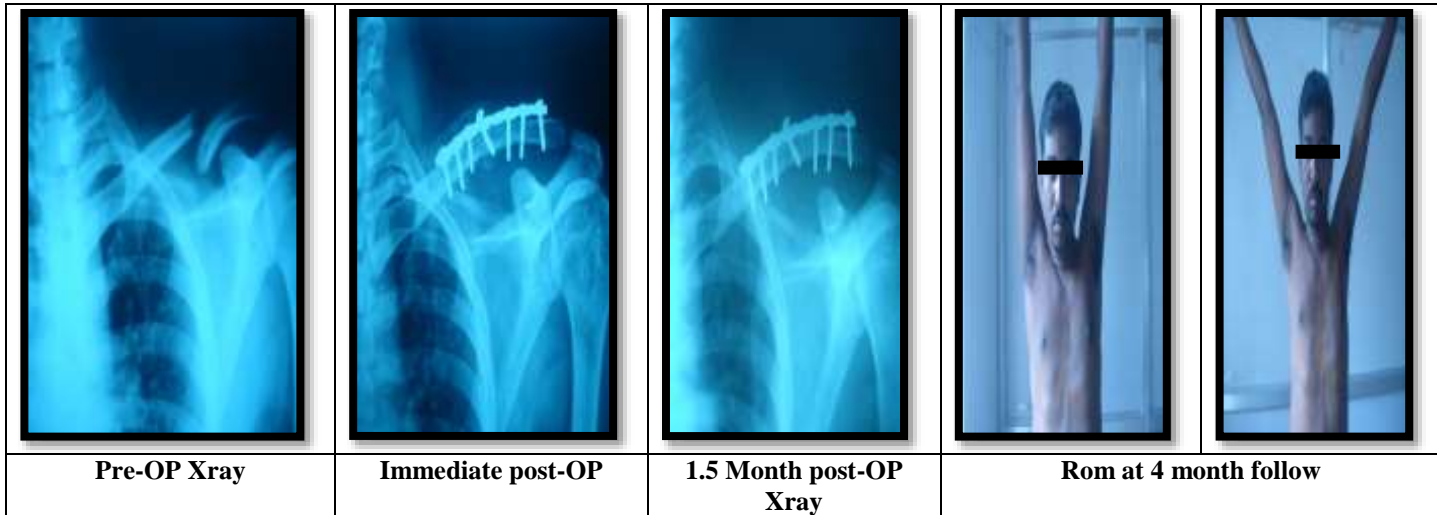
Graph 4: Functional out come as per constant murley score













Case 1

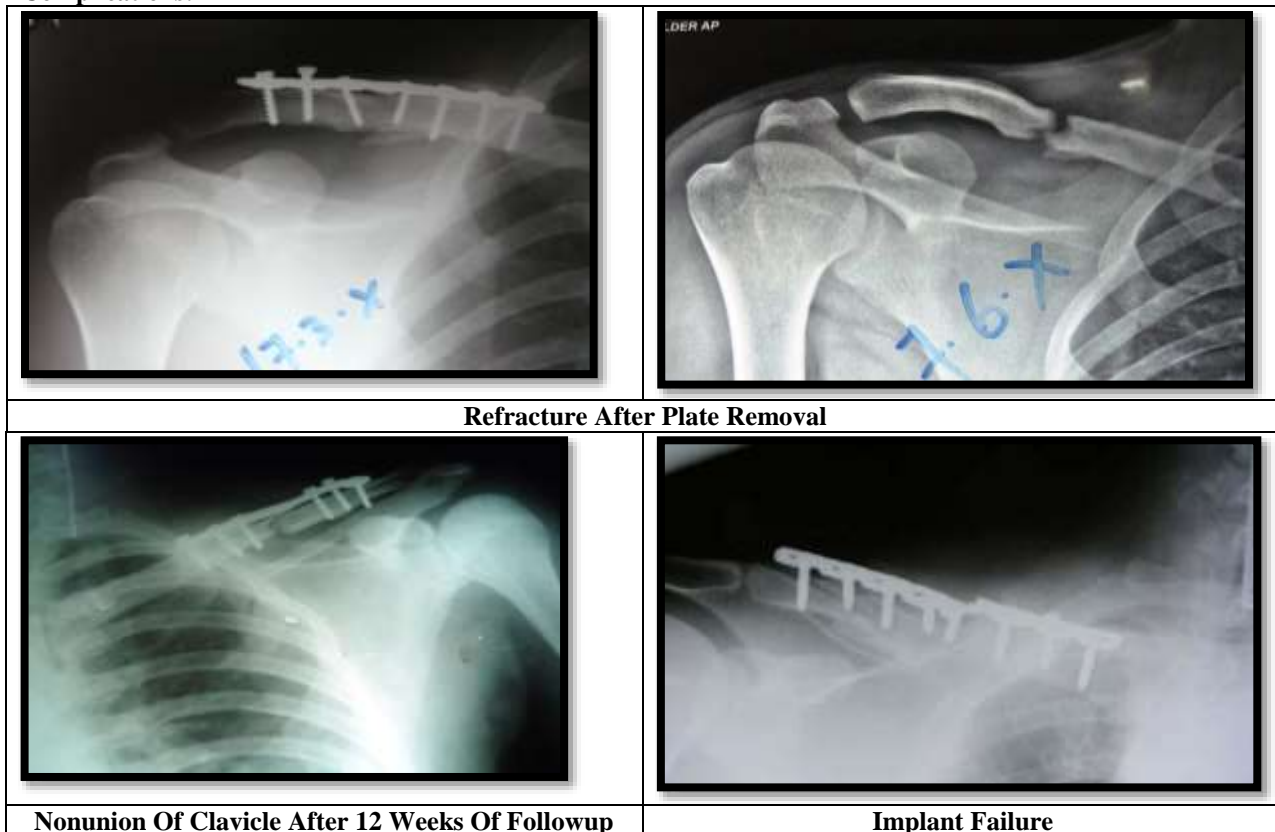


Case 2



Case 3

							
Pre-OP Xray		Immediate post OP		6 Weeks follow up Xray		Good union-10 weeks	
							
Flexion	Extension	Abduction	Adduction	Int. rotation	Ext. Rotation		

Complications:**Discussion**

Clavicle fractures are considered as benign injuries with a satisfactory outcome if treated conservatively. However, several reports challenge this view and there has been a resurgence of interest in operative treatment for fractures of the clavicle that display significant shortening, which may result in shoulder pain and weakness. Possible complications resulting from conservatively treated clavicle fractures are cosmetically displeasing end-results, delayed union, persisting non-union, chronic shoulder pain and impaired shoulder function. This may lead to low patient satisfaction rates and late return to sports activities. The advantage of internal fixation of clavicle fractures, which includes early pain relief, early return of shoulder function and potentially early return to daily activities, make it an appealing option for the treatment of displaced fractures in active individuals.

Many different methods of operative fixation of midshaft clavicle fractures have been described. Intramedullary pinning (Steinmann pins, Knowles pins or elastic nails, Kirschner wires) and the use of screws and different plates. Intramedullary pinning techniques have been associated with a high number of complications, such as pin migration and rotational instability and fixation with interfragmentary screws or wire sutures show insufficient immobilization. Intramedullary nailing with titanium elastic nail with medial entry is an attractive option, as it is minimally

invasive with good cosmetic and functional results. Many authors prefer rigid fixation with a plate. AO reconstruction plates, 3.5 mm limited contact dynamic compression plates (LCDCP), precontoured plates have been shown to provide superior fracture stability and excellent clinical results in the treatment of acute fractures and non-unions.

The present study of operative and non-operative modalities in patients with displaced middle third clavicle fractures yielded a better outcome in the operative group in terms of early and higher union, lower complication rates, and improved shoulder scores. The above finding of our study was supported by Bostman et al,⁽¹⁰⁾ Canadian Orthopaedic trauma society.⁽⁶⁾

In our study, majority of the middle third clavicle fracture in operative group united between 9 and 12 weeks that is, 15 patients (60%) compared to only 3 fractures (12%) in conservative group. The average duration of the union in operative group was 13.08 ± 3.6 weeks, and 15.14 ± 3.21 weeks in the non-operative group. According to Canadian orthopaedic trauma society⁽⁶⁾ time to radiographic union was decrease significantly from 28.4 weeks to 16.4 weeks in operative group. Shen et al operated on 251 freshly midthird clavicle fractures in adults the mean time to radiographic union was 10 weeks. McKee et al.⁽⁹⁾ described the mean time for fracture healing were 14-16

weeks for operated patients and 24-28 weeks for nonoperated patients.

The complications were more in the non-operative group like symptomatic malunion 9 cases (36%), nonunion 4 cases (16%), shortening 12 cases (48%), muscle wasting 4 cases (16%), pressure necrosis 1 case (4%). The complications noted in the operative group were incisional numbness 1 case (4%) and hardware irritation 2 cases (8%). Second surgery was done to remove irritating hardware. One of the operated patients had nonunion. McKee et al.,⁽⁹⁾ Robinson et al.,⁽²⁾ Zlowodzki et al.⁽⁵⁾ reported the rate of nonunion in the nonoperated patients more than 15%, and <4% in the operated group. Our study also shows the similar results as per the above literature.

Iatrogenic neurovascular vascular injury is a dangerous complication if proper operative techniques are not followed. Because major neurovascular structures like subclavian vein, subclavian artery and brachial plexus are near to the surgical field.

Postoperative wound infection is one of the major complications in plate fixation. Bostman et al.⁽¹⁰⁾ reported an infection rate of 7.8% in their series of operatively treated clavicle fractures. Zlowodzki et al.⁽⁵⁾ reported a superficial infection rate of 4.4% and deep infection rate 2.2% following clavicle fracture fixation. Canadian trauma society⁽⁶⁾ patients with clavicle fracture show infection rate 4.4% after fixation by plate. In our study infection rate found to be 8% which is very close to the literature finding. The functional outcome found to be higher in operative group described by Constant and Murley.⁽¹²⁾ This present study also found the same result. (Operative group=93.72±7.88 and Non operative group=84.48±7.87). McKee et al.⁽⁶⁾ also found that average higher constant score in operative group in displaced mid shaft fracture of the clavicle.

Conclusion

Non operative treatment is suitable for simple and undisplaced type of clavicle fractures, whereas plating should be considered for complex, comminuted, displaced type of clavicle fractures. Excellent functional outcomes and earlier return to daily activities can be achieved with surgical management of displaced clavicle fractures. However, patients and families must be counselled regarding the known complications associated with surgical fixation. The limitation of our study is small sample size and short term follow up. A large multicentered study is required to know the better functional outcome of the patients.

References

1. Rowe CR, "An atlas of anatomy and treatment of midclavicular fractures". Clin Orthop (1968);58:29-42.
2. Robinson CM, "Fractures of the clavicle in the adult. Epidemiology and classification." J Bone Joint Surg Br. (1998) May; 80(3):476-84.
3. Neer CS "Nonunion of the clavicle". JAMA (1960)172:1006-1011.

4. Hill JM, McGuire MH, Crosby LA "Closed treatment of displaced middle-third fractures of the clavicle gives poor results". J Bone Joint Surg Br(1997)79B:537-539.
5. Zlowodzki M, Zelle BA, Cole PA et al " Treatment of midshaft clavicle fractures: systemic review of 2144 fractures". J Orthop Trauma (2005)19:504-507.
6. Canadian Orthopaedic Trauma Society (MD McKee, principal investigator). "Plate fixation versus nonoperative care for acute, displaced midshaft fractures of the clavicle". J Bone Joint Surg(2007) 89A:1-11.
7. Nordqvist A, Petersson C, "The incidence of fractures of the clavicle". Clin Orthop Relat Res(1994) 300:127-132 .
8. Stanley D, Trowbridge EA, Norris SH. "The mechanism of clavicular fracture. A clinical and biomechanical analysis." J Bone Joint Surg Br(1988);70:461-464.
9. McKee MD, Pedersen EM, Jones C, Stephen DJ, Kreder HJ, Schemitsch EH et al. "Deficits following nonoperative treatment of displaced midshaft clavicular fractures". J Bone Joint Surg Am.(2006);88(5):35-40.
10. Bostman O, Manninen M, Pihlajamäki H, "Complications of plate fixation in fresh displaced midclavicular fractures". J Trauma (1997);43:778-83.
11. Brinker MR, Edwards TB, O'Connor DP, "Estimating the risk of nonunion following nonoperative treatment of a clavicular fracture". J Bone Joint Surg Am. (2005);87:676-677.
12. Constant CR, Murley AH, "A clinical method of functional assessment of the shoulder". Clin Orthop Relat Res (1987)214:160-16.