

Evaluation of antiurolithiatic activity of *Chlorophytum borivillianum* extract using experimental animals

Timir Patel^{1*}, Samir Shah² and Jigar Patel²

*¹Research scholar, C. U Shah University, Wadhwan City - 363 030, Dist-Surendranagar, Gujarat, INDIA & Asst. Professor, Sardar Patel College of Pharmacy, Bakrol – 388315, Dist – Anand, Gujarat, INDIA.

²Department of Pharmacology, Sardar Patel College of Pharmacy, Bakrol-388315, Dist-Anand, Gujarat, India.

Received: 11th September 2014 Accepted: 2nd November 2014/ Published: 10th November 2014



Greentree Group

©International Journal of Ayurveda and Pharmaceutical Chemistry, 2014

Timir et al

✉ timirbpatel@gmail.com

Int J Ayu Pharm Chem Vol. 1, Issue 2, 2014

Abstract

Urolithiasis, the most painful urologic disorder, refers to calculi or stone formation in the kidneys, ureter, and urinary tract due to imbalance between promoters and inhibitors of crystallization in urine. The worldwide incidence of urolithiasis is quite high and in spite of tremendous advances in the field of medicine there is no truly satisfactory mode of treatment available for treating renal calculi. For the management of urolithiasis, combination of surgical and medical approach using percutaneous nephrolithotomy (PCNL), extracorporeal shock wave lithotripsy (ESWL) and antibiotics are employed. But these treatment causes undesirable side effects such as traumatic effects, residual stone fragments persisted, infection, acute renal injury, a decrease in renal function, hemorrhage and hypertension. Ayurveda, an indigenous system of Indian medicine, offers vast scope for the successful treatment of urolithiasis. In Indian traditional system of medicine, Ayurveda, many plants including *Chlorophytum borivilianum* has been claimed to be useful in of urinary tract infections and in kidney and bladder stones. In light of above findings our aim of present study was to evaluate the antiurolithiatic activity of *Chlorophytum borivilianum* extract (CBE) using experimental animals.

Keywords

Urolithiasis, Ethylene glycol, *Chlorophytum borivilianum*

INTRODUCTION

Urolithiasis is one of the common and painful ailments of urinary tract disorder occurring in human since centuries [1]. Approximately, 80% of kidney stones are composed of calcium oxalate (CaOx) and calcium phosphate (CaP); 10% of struvite (magnesium ammonium phosphate produced during infection with bacteria that possess the enzyme urease) and 9% of uric acid (UA); and the remaining 1% are

composed of cystine or ammonium acid urate or are diagnosed as drug-related stones[2].

Stones larger than 5 mm or stones that fail to pass through must be intervened by procedures such as extracorporeal shock wave lithotripsy (ESWL), ureteroscopy (URS), or percutaneous nephrolithotomy (PNL). Unfortunately, the propensity for

stone recurrence is not altered by removal of stones with ESWL and stone recurrence is still about 50 %. In addition, ESWL might show some significant side effects such as renal damage, ESWL induced hypertension or renal impairment^[3]. The overall outcome gives clear indication for exploration of new remedy for removal of stone. In the Indian traditional systems of medicine including Ayurveda, most of the remedies are derived from plants and their traditional applications are proved to be useful in urolithiasis without causing any potential side effects^[1].

A large number of plants have been used in India since ancient times, which claim the efficient cure of urinary stone. *Chlorophytum borivilianum* popularly known as *Safed musali*, belonging to family Liliaceae is considered to be a wonder drug in Indian System of medicine. *Chlorophytum borivilianum* is diuretic and useful in cough, asthma and impotency^[4]. It has been reported that the plant which contain lupeol and stigmasterol show antiurolithiasis activity^[5]. *Chlorophytum borivilianum* contains stigmasterol⁴. Traditionally, *Chlorophytum borivilianum* roots were well known for their treatment in urinary diseases and renal calculi^[6,7]. Antiurolithiatic activity of *Chlorophytum borivilianum* has been not reported Greentree Group

scientifically. Hence, the present study was intended to evaluate the scientific rationality of the antiurolithiatic activity of *Chlorophytum borivilianum* extract (CBE) in rats.

MATERIALS AND METHODS

Plant materials

Roots of *Chlorophytum borivilianum* were collected from Anand Agriculture University, Anand and authenticated by Medicinal Plants Survey and Collection Unit, Anand Agriculture University, Anand, India.

Extraction of plant materials

The roots were dried at room and subjected to size reduction to get a coarse power. The powder was then passed through sieve no. 40 to get a uniform powder. Weighed 500 g of powder was subjected for soxhlet extraction with 90% ethanol for 3 hrs with mild heating. After extraction solvent was distilled off and extract was concentrated on water bath to a dry residue^[8].

Experimental Animals

Curative and preventive regimens were designed to evaluate antiurolithiatic activity of *Chlorophytum borivilianum* on ethylene glycol induced urolithiasis in rats. Male rats of body weight range between 150-200g were used for induction of urolithiasis. Experiment was conducted according to the

CPCSEA guidelines and the study was approved by the Institutional Animal Ethics Committee (IAEC) (Registration No. SPCP/IAEC/RP-019/2013).

Ethylene glycol induced urolithiasis

In this study, a total of 42 male rats were used. Ethylene glycol (0.75% v/v) in drinking water was fed to all groups except normal control (NC) for induction of renal calculi till 28th day [9]. The rats were randomly divided into seven groups of six animals each. Group I served as a normal control (NC). All remaining group received calculi inducing treatment for 28 days which comprised of 0.75% v/v ethylene glycol in drinking water *ad libitum*. Group II which received ethylene glycol only, served as model control (MC) for 28 days. Group III and IV served as curative regimen (CR) groups received CBE orally at doses of 250 & 500 mg/kg, respectively from 15th day to 28th day. Group V and VI served as preventive regimen (PR) groups received CBE orally at doses of 250 & 500 mg/kg respectively from 1st day to 28th day. Group VII served as standard group and received CYSONE 750 mg/kg (The Himalya Drug Company, India) for 28th day.

Biochemical parameters

Collection and analysis of urine

All animals were kept in individual metabolic cages and 24 h urine sample were collected on 28th day. The volume and pH of urine were determined. Urine was acidified with a drop of concentrated HCl and stored at -20 °C for determination of calcium, phosphate and oxalate estimation. The calcium and phosphate in urine were estimated using Kit of Beacon Diagnostics Pvt. Ltd., India. The Urine oxalate level was measured using the methods of Hodgkinson [10].

Serum analysis

After the experimental period of 28th day, blood was obtained from the retro-orbital sinus under anesthetic condition and animals were sacrificed by cervical decapitation. Serum was separated by centrifugation at 1500 rpm for 10 min using refrigerated research centrifuge (Remi centrifuge instrument, Mumbai) and used for the estimation of serum creatinine, urea and uric acid using commercially available diagnostic kits.

Kidney homogenate analysis

The abdomen was cut open to remove both the kidneys from each animal. Isolated kidney was cleaned off extraneous tissue, rinsed with ice-cold normal saline and preserved in 10% neutral formalin. The left kidney was finely minced and 20% homogenate was prepared in Tris-HCl

buffer (pH 7.4). Total kidney homogenate was used for assaying tissue calcium^[11], phosphate^[12] and oxalate^[13].

Histopathological analysis

The right kidney was fixed in 10% neutral formalin. The tissue was embedded in paraffin and a section of 5 µm were taken and stained with xylene and eosin and subsequently embedded in paraffin. The slides were examined for renal tubular necrosis and presence of calcium oxalate crystals under binocular microscope.

Statistical analysis

All the results were expressed as mean ± SEM. Statistical analysis was performed by one-way analysis of variance (ANOVA) followed by Dunnett's comparison test. P-value was calculated against normal control and model control groups and $P < 0.05$ was considered as significant.

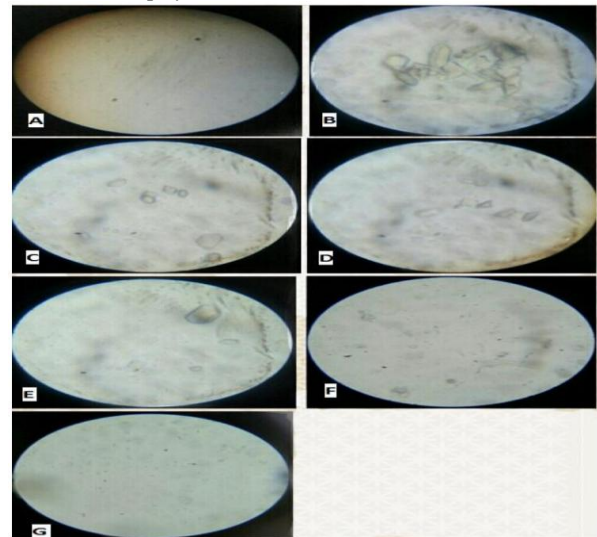
Table 1 Effects of *Chlorophytum borivilianum* extract on urine volume and pH in ethylene glycol induced urolithiasis

Treatment	Urine Volume (ml/24 hrs)	Urine pH
Normal control (NC)	9.27 ± 0.39 [#]	6.25 ± 0.15
Model control (MC)	14.96 ± 0.67 [*]	6.01 ± 0.17
CR - CBE (200 mg/kg, p.o.)	19.20 ± 0.74 [#]	6.34 ± 0.19

CR - CBE (200 mg/kg, p.o.)	21.22 ± 0.96 [#]	6.42 ± 0.11
PR - CBE (200 mg/kg, p.o.) PR	20.79 ± 0.67 [#]	6.39 ± 0.13
PR - CBE (200 mg/kg, p.o.) PR	22.26 ± 0.79 [#]	6.48 ± 0.17
STD - Cystone (750 mg/kg, p.o.)	23.04 ± 0.84 [#]	6.98 ± 0.15 [#]

All values are expressed as Mean ± SEM for each group (n=6). One way ANOVA followed by Dunnett's test. * $P < 0.05$ Model control Vs Normal control, [#] $P < 0.05$ Treatment groups Vs Model control. CBE; *Chlorophytum borivilianum* extract, CR; Curative regimen, PR; preventive regimen

Fig 1 Representative microscopic images (100x) of fresh urine. A=Normal control, B=Model control, C= CR - CBE (200 mg/kg, p.o.), D= CR - CBE (400 mg/kg, p.o.), E= PR - CBE (200 mg/kg, p.o.), F= PR - CBE (400 mg/kg, p.o.), G=STD. CR; Curative regimen, PR; Preventive regimen, CBE; *Chlorophytum borivilianum* extract



RESULTS

The microscopic examination of urine of normal control rats showed the absence of crystal or similar structure, while in case of model control group, the urine sample showed abundant, large crystals of CaOx. Treatment with both doses of CBE (200 &

400 mg/kg; p.o.) in CR showed better dissolution of the performed crystal of CaOx. However, small fragments of crystals were seen in both the groups. While in PR, treatment with both doses of CBE (200 & 400 mg/kg; p.o.) clearly showed better prevention of stone formation along with the dissolution of performed stones. The Cystone treated animals showed very less or almost dissolved small crystals (Fig 1).

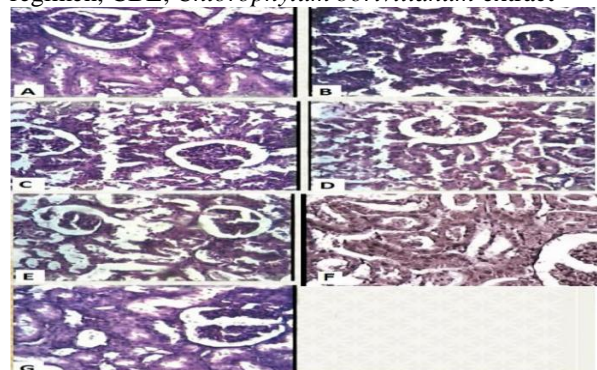
The urine output was found to increase significantly ($P < 0.05$) by stone-inducing treatment in MC rats as compared to NC rats. Treatment with both doses of *Chlorophytum borivilianum* (200 & 400 mg/kg; p.o.) in CR as well as PR regimen significantly ($P < 0.05$) increased urine output as compared to MC rats (Table 1). Calculi induced treatment changed urinary pH in untreated group and treated groups, but it was not to a significant extent in CR and PR effects of CBE (Table 1).

Table 2 Effects of *Chlorophytum borivilianum* extract on urine calcium, oxalate and phosphate in ethylene glycol induced urolithiasis.

Treatment	Calcium (mg/dl)	Oxalate (mg/dl)	Phosphate (mg/dl)
Normal control (NC)	3.18 ± 0.21	4.89 ± 0.27	5.25 ± 0.39
Model control (MC)	6.61 ± 0.32*	9.50 ± 0.33*	9.30 ± 0.25*
CR - CBE (200 mg/kg, p.o.)	5.13 ± 0.17 [#]	7.24 ± 0.32 [#]	7.61 ± 0.18 [#]
CR - CBE (400 mg/kg, p.o.)	4.46 ± 0.18 [#]	6.57 ± 0.29 [#]	6.97 ± 0.23 [#]
PR - CBE (200 mg/kg, p.o.)	4.10 ± 0.15 [#]	6.36 ± 0.15 [#]	6.75 ± 0.19 [#]
PR - CBE (400 mg/kg, p.o.)	3.75 ± 0.18 [#]	6.13 ± 0.29 [#]	6.53 ± 0.32 [#]
STD Cystone (750 mg/kg; p.o.)	3.51 ± 0.14 [#]	5.90 ± 0.31 [#]	6.28 ± 0.30 [#]

All values are expressed as Mean ± SEM for each group (n=6). One way ANOVA followed by *Dunnett's test*. * $P < 0.05$ Model control Vs Normal control, [#] $P < 0.05$ Treatment groups Vs Model control. CBE; *Chlorophytum borivilianum* extract, CR; Curative regimen, PR; preventive regimen.

Fig 2 Representative microscopic images (100x) of histopathology of kidney A=Normal control, B=Model control, C= CR - CBE (200 mg/kg, p.o.), D= CR - CBE (400 mg/kg, p.o.), E= PR - CBE (200 mg/kg, p.o.), F= PR - CBE (400 mg/kg, p.o.), G=STD.CR; Curative regimen, PR; Preventive regimen, CBE; *Chlorophytum borivilianum* extract



Administration of ethylene glycol (0.75% v/v in drinking water) to male rats produced increase in calcium, phosphate and oxalate concentration in urine of urolithiatic animals (Group II) resulted in Hypercalciuria hyperphosphaturia and hyperoxaluria respectively. The calcium, phosphate and oxalate concentration were significantly increased in MC animals as compared to the NC animals. However, treatment with both doses of CBE (200 & 400 mg/kg; p.o.) in CR as well as PR and CYSTONE (750 mg/kg; p.o.) significantly reduced calcium, phosphate and oxalate concentration in urine as compared to MC animals (Table 2).

Serum creatinine, urea, and uric acid concentration were increased significantly ($P < 0.05$) in MC rats as compared to NC rats. Treatment with both doses of *Chlorophytum borivilianum* (200 & 400 mg/kg; p.o.) in both CR and PR regimen significantly decreased the elevated level of serum creatinine, urea and uric acid concentration as compared to MC rats (Table 3).

Stone-inducing treatment to animal's significantly increased of calcium, oxalate and phosphate levels in the kidney tissue homogenate. Treatment with both doses of CBE (200 & 400 mg/kg; p.o.) in both curative and preventive regimen significantly decreased the kidney levels of

calcium, oxalate and phosphate as compared to MC rats (Table 4).

Histopathological analysis revealed no calcium oxalate deposits or other abnormalities in the nephron segment of vehicle tissue of urolithiatic rats. On the other hand, many calcium deposits inside the tubules and dilation of the proximal tubules along with interstitial inflammations were observed in the renal tissue of urolithiatic rats. Whereas, histopathological examination of kidney showed reduced renal damage as suggested by less degeneration of epithelial lining and tubular dilatation in all CBE treated rats (Fig 2).

DISCUSSION

The basis of calcium stone formation is urine supersaturation with stone-forming calcium salts. A number of dietary factors and metabolic abnormalities, namely hypercalciuria, hypocitraturia, and hyperoxaluria, can change the composition or saturation of the urine and therefore enhance stone-forming propensity^[14]. On administration, EG gets absorbed rapidly and metabolized into glycolic acid, glyoxylic acid, and finally converted in to glycolate and oxalate by coupling of oxidation-reduction reaction leading to hyperoxaluria^[15]. Oxalate is attracted to

cations to form insoluble CaOx. Calcium oxalate crystals and high oxalate levels in nephrons damages epithelial cells, inducing heterogeneous crystal nucleation and causing aggregation of crystals^[16].

Table 3 Effects of *Chlorophytum borivilianum* extract on serum creatinine, urea and uric acid in ethylene glycol induced urolithiasis.

Treatment	Creatinine (mg/dl)	Urea (mg/dl)	Uric acid (mg/dl)
Normal control (NC)	0.41 ± 0.07	32.29 ± 1.26	1.82 ± 0.13
Model control (MC)	1.52 ± 0.16*	37.20 ± 1.81*	3.74 ± 0.21*
CR - CBE (200 mg/kg, p.o.)	0.84 ± 0.09 [#]	35.78 ± 1.68 [#]	3.16 ± 0.18 [#]
CR - CBE (200 mg/kg, p.o.)	0.70 ± 0.07 [#]	34.98 ± 1.46 [#]	2.61 ± 0.17 [#]
PR - CBE (200 mg/kg, p.o.)	0.73 ± 0.06 [#]	34.23 ± 1.92 [#]	2.48 ± 0.20 [#]
PR - CBE (200 mg/kg, p.o.)	0.59 ± 0.04 [#]	33.71 ± 2.24 [#]	2.17 ± 0.11 [#]
STD - Cystone (750 mg/kg; p.o.)	0.51 ± 0.06 [#]	33.02 ± 1.94 [#]	1.93 ± 0.11 [#]

All values are expressed as Mean ± SEM for each group (n=6). One way ANOVA followed by *Dunnett's test*. **P*<0.05 Model control Vs Normal control, [#]*P*<0.05 Treatment groups Vs Model control. CBE; *Chlorophytum borivilianum* extract, CR; Curative regimen, PR; preventive regimen.

Male rats were selected to induce urolithiasis because the urinary system of male rats resembles that of humans and earlier studies shown that the amount of stone deposition in female rats was significantly less^[17].

Table 4 Effects of *Chlorophytum borivilianum* extract on kidney homogenate calcium, oxalate and phosphate in ethylene glycol induced urolithiasis.

Treatment	Calcium (mg/dl)	Oxalate (mg/dl)	Phosphate (mg/dl)
Normal control (NC)	3.21 ± 0.16	1.65 ± 0.12	2.40 ± 0.11
Model control (MC)	4.76 ± 0.15*	5.75 ± 0.97*	3.80 ± 0.17*
CR - CBE (200 mg/kg, p.o.)	4.26 ± 0.13 [#]	5.02 ± 0.14 [#]	3.38 ± 0.18 [#]
CR - CBE (200 mg/kg, p.o.)	3.80 ± 0.18 [#]	4.49 ± 0.20 [#]	3.20 ± 0.14 [#]
PR - CBE (200 mg/kg, p.o.)	3.33 ± 0.16 [#]	4.20 ± 0.18 [#]	3.10 ± 0.21 [#]
PR - CBE (200 mg/kg, p.o.)	3.17 ± 0.17 [#]	4.05 ± 0.16 [#]	2.98 ± 0.13 [#]
STD - Cystone (750 mg/kg; p.o.)	3.02 ± 0.14 [#]	3.09 ± 0.23 [#]	2.60 ± 0.16 [#]

All values are expressed as Mean ± SEM for each group (n=6). One way ANOVA followed by *Dunnett's test*. **P*<0.05 Model control Vs Normal control, [#]*P*<0.05 Treatment groups Vs Model control. CBE; *Chlorophytum borivilianum* extract, CR; Curative regimen, PR; preventive regimen.

Previous studies have been indicated that on 14th day administration of ethylene glycol to the young albino rats resulted into the formation of renal calculi composed mainly of calcium oxalate^[18]. Following the induction of lithiasis the urinary volume and composition were found to be altered. Treatment with CBE urine output was increased significantly as compare to MC group which may resulted due to intrinsic diuretic activity of CBE (Table 1). The diuretic activity of CBE may prevent urine stagnation and the formation of symptomatic calculi. Moreover, dilute

urine alters the supersaturation of stone components and reduces stone formation.

Earlier, it was reported that ethylene glycol causes hypercalciuria, hyperoxaluria, and hyperphosphaturia leading to urolithiasis^[19]. Since hyperoxaluria is a far more significant risk factor, the changes in urinary oxalate levels are comparatively much more imperative than those of calcium. It has been reported that oxalate play an important role in stone formation and has about 15-fold greater effect than urinary calcium^[20]. Increased urinary and kidney calcium is a factor stimulating the nucleation and precipitation of calcium oxalate or apatite (calcium phosphate) from urine and following crystal growth^[21]. In the present study lithogenic treatment increased urinary calcium and oxalate excretion. However, treatment with CBE in both CR and PR and Cystone, restored calcium and oxalate in urine and kidney homogenate as compared to model control group (Table 1 & 3). The reduction in oxalate excretion was observed on *Chlorophytum borivillianum* extract treatment. This decreased excretion of oxalate may be due to the inhibition of some steps of oxalate synthesis from ethylene glycol by the plant extract.

An increase in urinary phosphate excretion was observed on stone-induced rats. Greentree Group

Previous studies showed that increased urinary phosphate excretion along with oxalate stress seems to provide an environment appropriate for stone formation by forming calcium phosphate crystals, which induces calcium oxalate deposition^[22]. The rate of urinary phosphate excretion was decreased by *Chlorophytum borivillianum* treatment and thereby reduced the risk of stone formation. The glomerular filtration rate decreases because of stones in the urinary system obstructing urine outflow in urolithiasis. This leads to the accumulation of waste products in the blood, particularly nitrogenous substances such as creatinine, urea, and uric acid^[23]. In calculi-induced rats (MC), marked renal damage was seen by the elevated serum levels of creatinine, uric acid and Urea. This suggests that EG causes renal tubular damage and decreases GFR. However, treatment with CBE in CR and PR restored the elevated level of serum creatinine, uric acid and urea which indicates treatment with CBE significantly decreases the nephrotoxicity. Microscopic examination of the kidney section of ethylene glycol induced urolithic rats showed severe damage to the glomeruli, tubules and heamorrhage. However, treatment with extract of *Chlorophytum borivillianum* prevented EG induced damage to the tubules and calyces. Antiurolithiatic

activity of *Chlorophytum borivillianum* is mediated possibly through inhibition of CaOx crystal formation and its effect on urinary concentration of stone-forming constituents and urolithiasis inducing factors and this study rationalizes its medicinal use in urolithiasis. The study suggest that antioxidants, saponins of *Chlorophytum borivillianum* is therapeutically effective for treatment of calcium oxalate stones, exhibiting effect through a combination of diuretic, antioxidant and anti- inflammatory action, which could be responsible for its antiurolithiatic activity.

- [1] Baheti DG, Kadam SS, Antiurolithiatic activity of a polyherbal formulation against calcium oxalate induced urolithiasis in rats, *J. Adv. Pharm. Edu. & Res.* 3, (2013), 31-41.
- [2] Vyas AS, Patel MB, Patel AI, Joshi NR, Evaluation of Polyherbal Formulation in Renal Stone Disease, *Int. J. of pharma. & Res.* 3, (2012), 2820-2830.
- [3] Butterweck V, Khan SR, Herbal Medicines in the Management of Urolithiasis: Alternative or Complementary, *Planta Med.* 75, (2009), 1095–1103.
- [4] Kurian A, Sankar MA, Medicinal plants, New India Publishing Agency, New Delhi, 2007.
- [5] Manjula K, Rajendra K, Eevera T, Kumaran S, Effect of *Costus Igneus* stem extract on calcium oxalate urolithiasis in albino rats, *Urol. Res.* 40, (2012), 499-510.
- [6] Lokhande R, Singare P, Andhale M, Study on Mineral content of Some Ayurvedic Indian Medicinal Plants by Instrumental Neutron Activation Analysis and AAS Techniques, *Health Science journal.* 4, (2010), 157-168.
- [7] Pullaiah T, Encyclopedia of world medicinal plants, Regency Publication, New Delhi, 2006.
- [8] Deore SL, Khadabadi SS, Screening of Antistress Properties of *Chlorophytum Borivilianum* Tuber, *Pharmacology online.* 1, (2009), 320-328.
- [9] Pawar AT, Gaikwad GD, Metkari KS, Tijore KA, Ghodasara JV, Effect of *Terminalia chebula* fruits extract on ethylene glycol induced urolithiasis in rats, *Biomedicine Aging Pathology.* 2, (2012), 99-103.
- [10] Hodgkinson A, Determination of oxalic acid in biological material, *Clin. Chem.* 16, (1970), 547-57.
- [11] Mustafa MA, Medeiros DM, Proximate Composition, Mineral Content and Fatty Acid of Catfish For different seasons and Cooking Methods, *J. Food Sci.* 50, (1985), 585-588.
- [12] Fiske CH, Subbarow Y, The colorimetric determination of phosphate, *J. of Biological Chem.* 66, (1925), 375-381.
- [13] Hodgkinson A, Williams A, An improved colorimetric procedure for urine oxalate, *Clinica Chimica Acta.* 36, (1972), 127-132.
- [14] Abolfazl K, Mousa-Al-Reza H, Ziba R, Nema M, Saleh V, Mehdi S, The Beneficial Effect of *Cynodon Dactylon* Fractions on Ethylene Glycol-Induced Kidney Calculi in Rats, *Urol.* 8, (2011), 179-84.

- [15] Shukla AB, Mandavia DR, Barvaliya MJ, Tripathi CR, Evaluation of anti-urolithiatic effect of aqueous extract of Bryophyllum pinnatum (Lam.) leaves using ethylene glycol-induced renal calculi, *Avic J of Phyto.* 1, (2013), 1-6.
- [16] Pawar AT, Gaikwad GD, Metkari KS, Tijore KA, Ghodasara JV, Effect of Terminalia chebula fruit extract on ethylene glycol induced urolithiasis in rats, *Biomedicine & aging Pathology.* 2, (2012), 99-113.
- [17] Githrota UK, Crishtina AJ, Effect of Rotula aquatic lour. On ethylene glycol induced urolithiasis in rats. *Int. J of Drug Dev and Res.* 3, (2011), 273-280.
- [18] Sathish R, Natarajan K, Nikhad M, Effect of Hygrophila Spinosa T.anders on ethylene glycol induced urolithiasis in rats, *Asian J. of Pharmaceu. and Clin. Res.* 3(4), (2010), 61-63.
- [19] Rathod NR, Biswas B, Ranta S, Chandra R, Muchandi S, Anti-urolithiatic effects of Punica Granatum in Male Rats, *J. of Ethanopharmacol.* 140, (2012), 234-238.
- [20] Kumar R, Kumar T, Kamboj V, Chander H, Pharmacological evaluation of ethanolic extract of Kigelia pinnata fruit against ethylene glycol induced urolithiasis in rats, *Asian J. of Plant Sci. and Res.* 2, (2012), 63-72.
- [21] Ajjij A, Wadud A, Bilal A, Hajera S, Efficacy of Adiantum capillus veneris Linn in chemically induced urolithiasis in rats, *J. of Ethanopharmacol.* 116, (2013), 411-416.
- [22] Kalyani D, Pawar A, S Chandrasekhar S, Dighe S, Goli D, Protective effect of the hydro-alcoholic extract of Rubia cordifolia roots against ethylene glycol induced urolithiasis in rats, *Food and Chemical Toxicology.* 48, (2010), 1013–1018.
- [23] Karadi RV, Gadge NB, Alagawadi KR, Savadi RV, Effect of Moringa oleifera Lam. root-wood on ethylene glycol induced urolithiasis in rats, *J. of Ethanopharmacol.* 105, (2006), 306–311.

Timir et al *Int J Ayu Pharm Chem Vol. 1, Issue 2, 2014*

✉ timirbpatel@gmail.com