

An autopsy case report on OEIS Complex

Hadiya Naureen^{1*}, Ashwini HN²

¹PG Student, ²Associate Professor, Dept. of Pathology, JJM Medical College, Davangere, Karnataka

***Corresponding Author:**

Email: hnoorin@gmail.com

Abstract

OEIS complex is a rare congenital anomaly characterised by omphalocele, exstrophy of bladder, imperforate anus and spinal defects. It is a defect that affects the midline of the lower inferior body. This condition is mostly fatal and almost incompatible with life. A diabetic multiparous woman with history of previous 2 spontaneous abortions presented with 3rd pregnancy, spontaneously delivered a dead fetus of 17 weeks gestational age. Here we present an autopsy case report of a 17 weeks fetus with features of OEIS complex which had the above mentioned features along with left club foot, absence of spleen, pancreas & both internal and external genitalia. Microscopic examination of the placenta showed villi with fibrin clot deposition and calcification suggesting that fetomaternal insufficiency of placenta was the cause of death.

Keyword: OEIS complex, Omphalocele, Exstrophy of bladder, Club foot, Myelomeningocele

Introduction

The OEIS complex was first described and published by Litre in 1709,⁽¹⁾ and later Carey et al coined the term in 1978,⁽²⁾ it is characterised by a complicated combination of omphalocele, exstrophy of the bladder, imperforate anus and spinal defects. This complex is very rare with an incidence of 1/200,000-400,000 pregnancies;⁽³⁾ which occurs because of the defect in the early development of mesodermal migration during the primitive streak period. This mesoderm later on contributes to the formation of infra umbilical mesenchyme, cloacal septum and vertebral body.⁽⁴⁾ Most of the time it is picked up by antenatal ultrasound and confirmed on antenatal MRI. It represents in a spectrum of birth defects, most severe form, epispadias-exstrophy sequence which is composed of spectrum of genitourinary malformations including phallic separation with epispadias, pubic diastasis, bladder exstrophy, cloacal exstrophy and OEIS complex.⁽⁴⁾

Case Report

A 23 year old female, on insulin for gestational diabetes, with history of previous 2 early gestation spontaneous abortions presented with third pregnancy of 17 weeks duration. The ultrasound findings showed single intra-uterine pregnancy of 17 weeks gestational age with multiple congenital anomalies composed of omphalocele, non-visualisation of bladder, imperforate anus, cystic cloacal membrane, absence of genitalia, spina bifida at lumbosacral junction, marked kyphoscoliosis, left club foot and separation of symphysis pubis. Upper limbs were normal. The umbilical cord showed one vein and 2 arteries. Data on various hormone levels and serum alpha fetoprotein was not available as the case was received after the termination of the pregnancy. Karyotyping was not

performed and therefore its association with other trisomies could not be determined.

The pregnancy was terminated by spontaneous vaginal delivery of a still born macerated fetus with placenta of 17 weeks gestational age (Fig. 1). At autopsy, the weight of the fetus was 190gm and placenta 100gm. The following anatomical findings were noted during autopsy (Fig. 2, 3): (1) Omphalocele with herniation of part of bowel loops and part of the liver, (2) bladder exstrophy with narrow ureters connected to normal kidneys, (3) imperforate anus, cystic cloacal membrane, (4) absence of genitalia; both internal and external, (5) absence of spleen & pancreas, (6) myelomeningocele at lumbosacral junction, (7) marked kyphoscoliosis, (8) left club foot and bony defects of pelvic bone. Upper limbs were normal. The face, head, diaphragm and heart were normal.

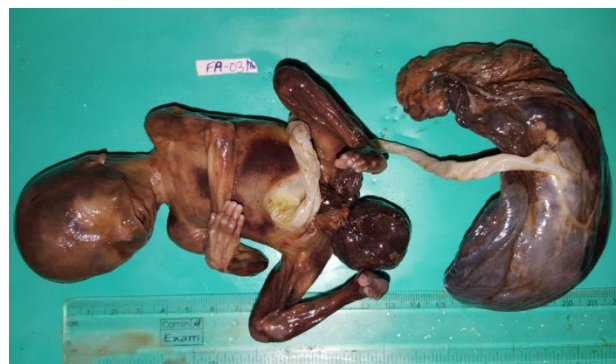

Fig. 1: Macerated still born fetus of 17 weeks of gestation with umbilical cord and placenta

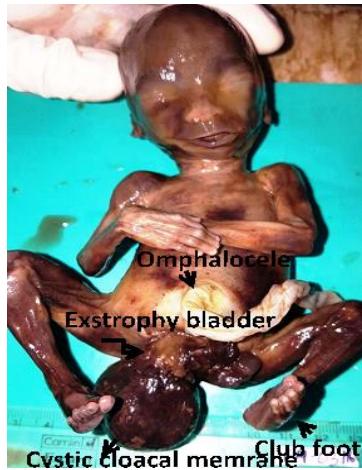

Fig. 2: Fetus showing omphalocele, exstrophy of bladder, cystic cloacal membrane and club foot

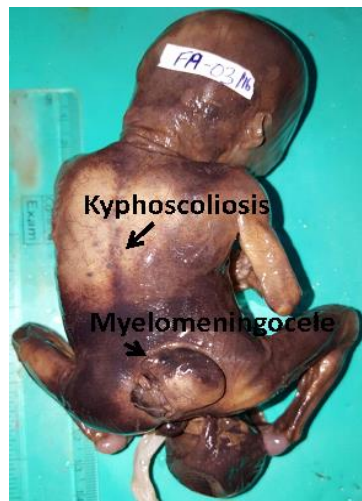


Fig. 3: Fetus showing spinal defects- kyphoscoliosis and myelomeningocele

Microscopic findings: The umbilical cord showed 3 vessels. The lungs were matured for the gestational age showing glandular stage of maturation which correlated with the gestational age of 12-16 weeks (Fig. 4). The exstrophied bladder showed urothelial lining. The cystic structure over the lumbosacral junction showed meninges and spinal cord structures. Placenta showed villi lined by syncytiotrophoblast and cytotrophoblast with most of the villi showing fibrin clot and calcification (Fig. 5) suggesting that fetomaternal insufficiency of placenta is the cause of death. Microscopic findings of other organs were normal.

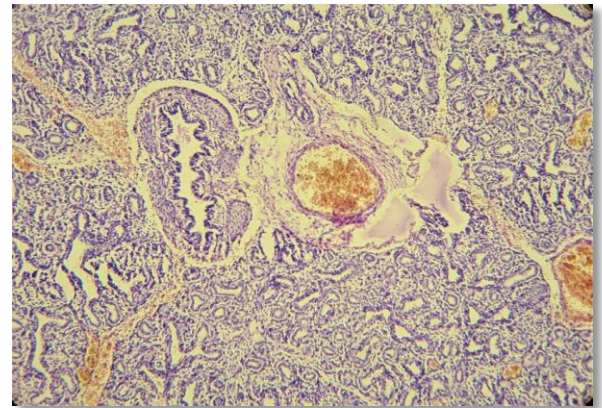


Fig. 4: Microscopy of lung showing glandular stage of maturation

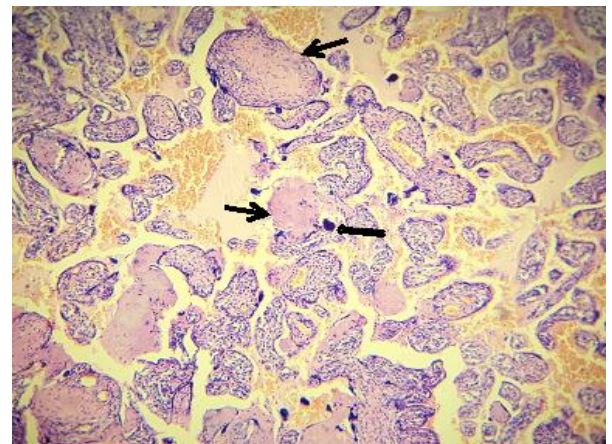


Fig. 5: Microscopy of placenta showing villi with fibrin clots (thin arrows) and calcification (thick arrow)

The patient was counselled regarding recurrences of this condition, and the option of prenatal genetic investigation was advised for subsequent pregnancies.

Discussion

The classical presentation of OEIS complex consists of 4 major components- omphalocele, exstrophy of bladder, imperforate anus and spine defects. A variety of other minor defects like club foot, renal anomalies, ascites, widened pubic arches, narrow thorax, kyphoscoliosis, cryptorchidism, anomalies of mullerian ducts in females, hydrocephalus and single umbilical artery have been reported along with the classical four. In the above presented case, a combination of all the major criteria and few minor has been reported.^(5,6,7)

Although the etiology of this complex is unknown but few associations have been studied such as teratogenic drugs like diazepam, diphenylhydantoin,⁽⁸⁾ valproic acid, methamphetamine, cigarette smoking, multiple pregnancies⁽⁶⁾, genetic association & sporadic familial occurrence. Association with other syndromes like trisomies 13, 18 & 21, triple x syndrome, Goltz syndrome⁽⁹⁾ and mutation in homeobox genes such as

HLXB9.⁽³⁾ Association with diabetes, maternal obesity, and multiple uterine fibroids has been reported in very few cases hence there is insufficient data to define specific associations. There is no data suggesting association of oral hypoglycemic drugs to OEIS complex.⁽¹⁰⁾ The maternal α -fetoprotein levels are increased in OEIS complex. But most cases of OEIS complex are diagnosed only at autopsy following interruption of pregnancy.

A single defect in early blastogenesis or a defect in caudal mesodermal migration during primitive streak period results in the OEIS complex. This defect in the caudal mesoderm leads to the failure of fusion of cranio-caudal and 2 lateral ecto-mesodermal folds of embryo during the 4th week of development which results in ventral abdominal wall defect i.e., omphalocele. This is associated with the failure of reduction of physiological hernia and non-fixation of gut between 8th and 12th week of development. Cloacal exstrophy prevents the development of proctodeum resulting in imperforate anus. Caudal dysgenesis interferes with somite formation resulting in defective vertebrae.^(11,12)

Initially in 1978, Carey et al reported that this complex is not an inherited entity.⁽¹⁾ Schinzel et al. in 1979 estimated that twinning and early malformations such as cloacal exstrophy, may be causally related.⁽¹³⁾ Smith et al in 1992 reported recurrence in sibs proving inheritance of the defect.⁽¹⁾ Later Lee et al in 1999 reported a higher incidence of OEIS in monozygotic twins than in dizygotic twins suggesting a possible genetic contribution to the occurrence of these defects.⁽¹⁴⁾

Conclusion

OEIS complex involves almost all the systems in the body and may differ in clinical presentations. This condition is mostly fatal and almost incompatible with life. Hence it is important to diagnose these cases in early pregnancy and counsel the parents regarding the option of terminating the pregnancy or management of the same if they chose to continue. The major findings for the diagnosis on sonography are omphalocele, non-visualisation of the bladder, imperforate anus and spine defects. Its management is based on multidisciplinary surgical reconstruction to support a better outcome of life.

References

1. Smith NM, Chambers HM, Furness ME, Haan E. A. The OEIS complex: recurrence in sibs. *J med Genet.* 1992;29:730-2.
2. Carey JC, Greenbaum B, Hall BD. The OEIS complex (omphalocele, exstrophy, imperforate anus, spinal defects). *Birth Defects* 1978;14:253-63.
3. Källén K1, Castilla EE, Robert E, Mastroiacovo P, Källén B. OEIS complex-a population study. *Am J Med Genet.* 2000;92(1):62-8.
4. Ebert AK, Heiko Reutter, Michael Ludwig and Wolfgang H Rösch. The Exstrophy-epispadias complex. *Orphanet Journal of Rare Diseases* 2009;4:23. doi:10.1186/1750-1172-4-23.
5. Meizner I, Bar-Ziv J. In utero prenatal ultrasonic diagnosis of a rare case of cloacal exstrophy. *J Clin Ultrasound* 1985;13:500-2.
6. Noack F, Sayk F, Gembruch U. Omphalocele-exstrophy imperforate anus-spinal defects complex in dizygotic twins. *Fetal Diagn Ther* 2005;20:346-8.
7. Girz BA, Sherer DM, Atkin J, Venanzi M, Ahlborn L, Cestone L. First-trimester prenatal sonographic findings associated with oeis (omphalocele-exstrophy-imperforate anus- spinal defects) complex: A case and review of the literature. *Am J Perinatol* 1998;15:15-7.
8. Shanske AL, Pande S, Aref K, Vega-Ric C, Brion L, Reznik S, Timor-Tritsch I.E.- Omphaloceleexstrophy-imperforate anus-spinal defects (OEIS) in triplet pregnancy after IVF and CVS. *Birth defects research (part A).* 2003;67:467-71.
9. Chih-Ping C. Syndromes and disorders associated with omphalocele(II): OEIS complex and pentalogy of Cantrell. *Taiwan j obstet gynecol.* 2007;46:103-8.
10. Keppler-Noreuil K, Gorton S, Foo F, Yankowitz J, Keegan C. Prenatal ascertainment of OEIS complex/cloacal exstrophy—15 new cases and literature review. *Am J Med Genet Part A.* 2007;143A:2122-8.
11. Martinez-Frias ML, Bermejo E, Rodriguez- Pinilla E, Frias JL. Exstrophy of the cloaca and exstrophy of the bladder: Two different expressions of a primary developmental field defect. *Am J Med Genet* 2001;99:261-9.
12. Maizels M. 1998. Normal and anomalous development of the urinary tract. In: Walsh PC, Retnik AB, Vaughan Ed, Wein AJ, editors. *Campbell's urology*, 7th edition. Philadelphia: W.B. Saunders Co. p 1545-600.
13. Schinzel, A. A. G. L., Smith, D. W., Miller, J. R. Monozygotic twinning and structural defects. *J. Pediat.* 1979;95: 921-30.
14. Lee, D. H., Cottrell, J. R., Sanders, R. C., Meyers C. M., Wulfsberg, E. A., Sun, C.-C. J.OEIS complex (omphalocele-exstrophy imperforate anus-spinal defects) in monozygotic twins. *Am. J. Med. Genet.* 1999;84:29-33.