

## Mixed haemangioma ovary: A rare case report

Ranjan Agrawal<sup>1,\*</sup>, Shweta Agrawal<sup>2</sup>, Parbodh Kumar<sup>3</sup>

<sup>1</sup>Professor, <sup>2</sup>Assistant Professor, <sup>3</sup>Professor & HOD, Dept. of Pathology, Rohilkhand Medical College & Hospital, Bareilly, Uttar Pradesh

**\*Corresponding Author:**

Email: drranjan68@gmail.com

### Abstract

Vascular tumours of the female genital tract are very rare. Ovarian haemangiomas are extremely rare benign tumour despite their rich vascular supply, with approximately 60 documented cases in the English literature. They are “non-functional” neoplasms. The histogenesis is still debatable. Most of the haemangiomas in the ovary are asymptomatic and of the mixed type.

**Keywords:** Haemangioma, Mixed type, Ovary

### Introduction

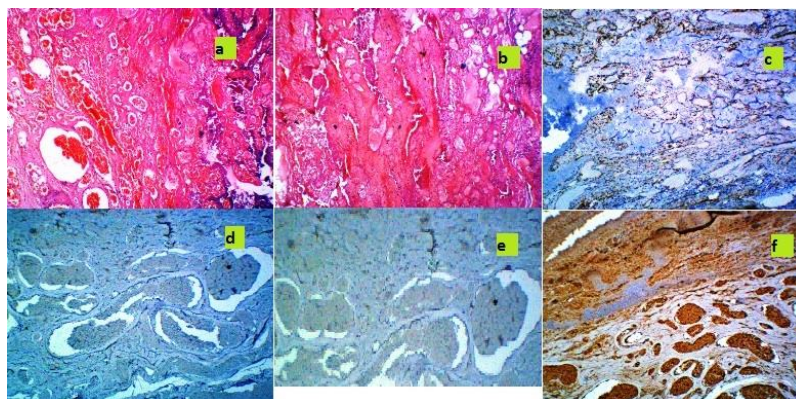
Haemangiomas are rarely located in the genital tract. Ovary itself is a highly vascularized organ but vascular tumours of the female genital tract especially in the ovary are very rare. Less than 60 cases have been reported in the literature so far. A case of mixed type ovarian haemangioma in a young female is being reported following its rarity.

### Case Report

An 18 years old unmarried hindu female presented with complaints of pain in abdomen for 1 year. The pain was not continuous but occurred off and on. She also had decreased frequency of micturition for 5-6 days. There was no history of burning micturition or discharge per-vaginum. Per abdominal examination showed a mass of 22 weeks gestation which was mobile, non-tender, smooth, and tensely cystic with well-defined margins. The mass was more prominent palpate on the right side. It was possible to below the mass. Ultrasound abdomen revealed 2 right sided ovarian cysts measuring 12x10 cm which was uniloculated & another 4x4 cm which was

multiloculated. On investigations her haemoglobin was 7.3 g/dl. Other haematological and biochemical parameters were within normal limits. Based on these findings a provisional clinical diagnosis of simple serous cystadenoma or dermoid cyst of ovary was made.

The patient was subjected to exploratory laparotomy. Right sided ovarian cystectomy was performed. Gross examination of the resected specimen showed two cystic tissues. First was a globular greyish-white soft tissue measuring 4.5 x 4 cm in size. On cutting haemorrhagic fluid came out. The second greyish-brown cystic tissue measured 8.5 x 7 cm in dimension. On cutting it was multiloculated and brownish fluid was extruded. Microscopy showed extensive haemorrhage, corpus luteal cysts alongwith numerous proliferating and congested blood vessels of different caliber (Fig. 1a, 1b). Immunohistochemical markers CD34 and VEGF were strongly positive (Fig. 1c, 1f). Ki 67 index was low. Both ER and PR markers were negative (Fig. 1d, 1e). A diagnosis of mixed type of ovarian haemangioma was rendered. Post-operative period of the patient was uneventful.



**Fig. 1: Microphotograph showing (a) Proliferation of blood vessels of different caliber (H&E x 100) (b) Large sized blood vessels filled with red blood cells (H&E x 100) (c) CD 34 Positivity (CD 34 X 100) (d) ER Negativity (ER X 100) (e) PR Negativity (PR X 100) (f) Strong VEGF Positivity (VEGF X 100)**

## Discussion

Haemangioma of the ovary was first described by Payne in 1869.<sup>(1)</sup> Ovary has a rich blood supply but vascular tumours of the female genital tract, especially those arising in the ovary, are very rare.<sup>(2-6)</sup> Ovarian haemangiomas have been reported both in adults and children with an age range from infancy to 81 years.<sup>(5-8)</sup> Histologically, haemangiomas are known to develop as a result of failure of canalisation of the blood vessels due to malformation. The aetiology of ovarian haemangiomas is still unknown. Some believe it to be a differentiation of true tumour or hamartoma, or blood vessels. One hypothesis is that hyperestrogenism as a result of stromal hyperplasia or stromal hyperthecosis may cause endometrial stimulation.<sup>(9)</sup> This hypothesis is based on the fact that estrogens have known growth stimulatory effects on the vasculature. Some cases may be associated with endometrial hyperplasia and malignancies including endometrial cancer and germ cell tumour.<sup>(1,4,10)</sup> Cyclic changes in the female genital organs, asymptomatic nature and small size of the neoplasm makes the tumour rare.<sup>(11)</sup> These luteinized stromal cells produce steroid hormones, mainly androgens that later are converted to oestrogens in the adipocytes leading to endometrial hyperstimulation.<sup>(4,12)</sup>

Ovarian haemangiomas are usually asymptomatic and are detected incidentally during laparotomy or autopsy.<sup>(5)</sup> Large lesions present with lower abdominal pain, nausea and vomiting, due to torsion or abdominal distension because of the mass itself.<sup>(2)</sup> Rarely, it may present as one of the manifestation of Kasabach-Merritt Syndrome (systemic haemangiomata).<sup>(13)</sup> Few cases are associated with thrombocytopenia, ovarian stromal luteinisation, postmenopausal bleeding, endometrial hyperplasia, or endometrial carcinoma.<sup>(14)</sup> Occasional cases have been reported to be associated with ascites or high serum CA-125 levels thus mimicking advanced ovarian carcinoma.<sup>(6,15)</sup> In children, the tumour is mostly symptomatic.

Ovarian haemangiomas range from few millimeters to 20 cm in size and generally have a smooth glistening outer surface.<sup>(3,5)</sup> They are usually unilateral with few bilateral occurrence been reported.<sup>(5,14)</sup> Microscopically, they are composed of dilated, blood-filled thin-walled vessels of varying caliber and lined by a single layer of flattened endothelial cells. They may histologically be of cavernous, capillary or mixed types with mixed type being the commonest.<sup>(6)</sup> Different parts of the ovaries may be affected but medulla and hilum are more commonly involved probably since larger vascular channels are present in these regions. The vessels may be haphazardly located in a lobular pattern with a variable amount of connective tissue stroma in which inflammation, haemorrhage or haemosiderin deposition may be present. The vessels may be thrombosed and the intervening stroma may show hyalinisation, calcification, and occasional luteinisation. Most tumours are sharply separated from adjacent tissue, a

feature distinguishing them from normal ovarian blood vessels.<sup>(5)</sup> The endothelial cells show strong immunoreactivity for CD34 marker.

The clinical differential diagnoses of ovarian haemangiomas include tubo-ovarian mass, twisted ovarian cyst, and chocolate cyst.<sup>(6)</sup> The pathological differential diagnoses include vascular proliferations, lymphangioma, mature teratoma with a large haemangiomatous component and, angiosarcoma. Ovarian haemangiomas must be differentiated from proliferations of dilated blood vessels in the hilum.<sup>(6)</sup> Haemangioma usually forms a reasonably circumscribed nodule or a small mass composed of vascular channels, ranging from small to large sizes with a variable amount of stroma when compared with vascular proliferations, which tend to be smaller and diffuse. Presence of numerous blood cells within the vascular channels and the absence of pale eosinophilic homogeneous material usually distinguish haemangioma from lymphangioma. Vascular elements are usually not a component of teratomas, however, bilateral ovarian teratomas with a large haemangiomatous component have been reported in which the lesions have been distinguished from a pure haemangioma by the presence of a focus of respiratory epithelium.<sup>(16)</sup> For ruling out teratoma, a thorough sampling is required so as to exclude the presence of other teratomatous components.<sup>(5,15)</sup> Angiosarcomas are usually unilateral, cystic, soft, friable and spongy showing haemorrhage and necrosis. Microscopically they show marked pleomorphism, cytological atypia, papillary tufting of the endothelium, necrosis, haemorrhage, and high mitotic counts.<sup>(15)</sup>

The surgical approach differs once the diagnosis of haemangioma is established. Thus to avoid unnecessary radical surgery for a benign neoplasm, haemangioma should be kept in mind as a differential diagnosis of an ovarian mass before surgical exploration is attempted.

## Conclusion

Haemangiomas of ovary are very rare neoplasms with a wide age range and incidental discovery during operation or autopsy. These neoplasms should be considered in the differential diagnosis of a hemorrhagic ovarian lesion. Surgical extirpation of the involved areas is the treatment of choice.

## References

1. Talerma A. Gonadal mixed germ cell tumour combined with a large haemangiomatous lesion. *Arch Pathol Lab Med* 1995; 119:992-3.
2. Mirilas P, Georgiou G, Zevgolis G. Ovarian cavernous haemangioma in an 8-year-old girl. *Eur J Pediatr Surg* 1999;9:116-8.
3. Kaneta Y, Nishino R, Asaoka K, Toyoshima K, Ito K, Kitai H. Ovarian haemangioma presenting as pseudo-Meigs' syndrome with elevated CA125. *J Obstet Gynaecol Res* 2003;29(June):132-5.
4. Gücer F, Ozyilmaz F, Balkanlı-Kaplan P, Mülayim N, Aydın O. Ovarian haemangioma presenting with

- hyperandrogenism and endometrial cancer: A case report. *Gynecol Oncol* 2004;94:821-4.
5. Uppal S, Heller DS, Majmudar B. Ovarian haemangioma – report of three cases and review of the literature. *Arch Gynecol Obstet* 2004;270:1-5.
  6. Gupta R, Singh S, Nigam S, Khurana N: Benign vascular tumours of female genital tract. *Int Gynecol Cancer* 2006, 16:1195-1200
  7. Rodriguez M.A. Haemangioma of ovary in an 81 year old woman. *South Med. J.*1979;72:77-78.
  8. Liapis A, Bakalianou K, Salakos N, Iavazzo C, Dalainas I, Kondi-Pafiti A. Vascular tumours: rare neoplasms of the female genital tract. *Eur J Gynaecol Oncol* 2009;30:220-2.
  9. Miliaras D, Papaemmanouil S, Blatzas G. Ovarian capillary haemangioma and stromal luteinization: a case study with hormonal receptor evaluation. *Eur J Gynaecol Oncol* 2001;22:369-71.
  10. Alvarez M, Cerezo L. Ovarian cavernous haemangioma. *Arch Pathol Lab Med* 1986;110:77-78.
  11. Pethe VV, Chitale SV, Godbole RN, Bidaye SV. Haemangioma of the ovary – a case report and review of the literature. *Indian J Pathol Microbiol* 1991;34:290-92.
  12. Rivasi F, Philippe E, Walter P, de Marco L, Ludwig L. [Ovarian angioma. Report of 3 asymptomatic cases]. *Ann Pathol* 1996;16:439-41.
  13. Miyauchi J, Mukai M, Yamazaki K, Kiso I, Higashi S, Hori S. Bilateral ovarian haemangiomas associated with diffuse hemangioendotheliomatosis: a case report. *Acta Pathol Jpn* 1987;37:1347-55.
  14. Lawhead RA, Copeland LJ, Edwards CL. Bilateral ovarian haemangiomas associated with diffuse abdominopelvic haemangiomatosis. *Obstet Gynecol*, 1985;65:597-9.
  15. Akbulut M, Bir F, Colakoglu N, Soysal ME, Duzcan SE. Ovarian haemangioma occurring synchronously with serous papillary carcinoma of the ovary and benign endometrial polyp. *Ann Saudi Med* 2008; 28:128-31.
  16. Feuerstein IM, Aronson BL, McCarthy EF. Bilateral ovarian cystic teratomata mimicking bilateral pure ovarian haemangiomas: case report. *Int J Gynecol Pathol* 1984;3:393-7.