

Thoracic epidural anaesthesia – A promising alternative for a patient with difficult airway

Charuta Gadkari¹, Priyanka Pravin Deshmukh^{2,*}, Megha Tajne³, Ankush Wasnik⁴

¹Associate Professor, ²Junior Resident, ³Associate Professor, ⁴Junior Resident, Dept. of Anaesthesia, NKP Salve Institute of Medical Sciences, Nagpur, Maharashtra, India

***Corresponding Author:**

Email: priyankadeshmukh@gmail.com

Received: 01st June, 2017

Accepted: 15th September, 2017

Abstract

A patient with post burn contracture of neck and Marjolin's ulcer on anterior chest wall was posted for wide local excision and skin grafting. Skin graft was taken from lower limb under unilateral subarachnoid block and wide local excision of ulcer was performed under thoracic epidural anaesthesia. In the background of pre-formulated strategy in view of anticipated difficult airway, regional anaesthesia is a well established and safe alternative in expert hands.

Keywords: Anterior chest wall surgery, difficult airway, Thoracic epidural, Post burn contracture (PBC).

Introduction

With reference to increased survival of burn patients, those with PBC may present for anaesthetic care.¹ This case is our attempt to use thoracic epidural anaesthesia as a safe alternative to general anaesthesia in a patient for anterior chest wall surgery with difficult airway due to post burn contracture of neck.

Case Report

A 50 year female patient weighing 45 kg came with chief complaints of PBC on neck and chest and recurrence of the Marjolin's ulcer on the anterior chest wall. She had history of burns 40 yrs back and excision of the same ulcer one month back under local anaesthesia. Her feeding and breathing were not affected. Personal history and family history were not contributory. Her exercise tolerance was more than 3 flights of stairs.

On examination, patient was conscious, cooperative and well oriented. General examination and systemic examination were normal. Spine examination revealed no abnormality. On airway examination, there was restricted neck extension; however mouth opening was two and half fingers and grade II under Mallampati Classification.

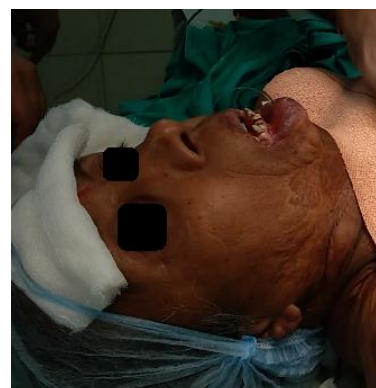

Fig. 1: Preanaesthetic airway evaluation

On local examination, ulcer was 4 x 4 x 4 cm on the anterior chest wall at the level of sternum, with well defined margins, with rolled edges, was non discharging, non-indurated with surrounding contracture scar.

Laboratory workup was normal. The electrocardiogram was normal.

The patient was thus scheduled for wide local excision of the ulcer and skin grafting. Patient was graded as ASA I and labeled as "Anticipated Difficult Airway".

We planned a thoracic epidural anaesthesia at level of T5-T6 for excision of ulcer and unilateral subarachnoid block for harvest of skin graft. Patient was counseled regarding the technique of thoracic epidural anaesthesia as well as airway management plans and the possible complications in detail and consent was obtained. With difficult airway in background, difficult airway cart preparation with fiberoptic bronchoscope, necessary masks, airways, endotracheal tubes, laryngeal mask airways, stylet, bougie, video laryngoscope and various laryngoscope blades was done.²

With all standard monitors attached including the electrocardiogram, pulse oximeter and non invasive blood pressure, intravenous line was secured with 18 gauge cannula and Ringer lactate infusion was started. Patient was pre-medicated with injection Ranitidine 50 mg iv and injection Ondansetron 4mg iv.

Under all aseptic precautions with the use of 18 gauge Touhy needle, epidural space was achieved in T5-T6 interspace with loss of resistance to air technique and epidural catheter was inserted. Catheter placement was confirmed by negative aspiration of blood and CSF

and menisci sign. After a negative result on test dose with 3 ml 2% Lignocaine and Adrenaline, isobaric injection Bupivacaine 0.25% was given epidurally in incremental doses upto 10 ml to achieve T1 to T8 dermatome block.

For the graft harvest, unilateral subarachnoid block was instituted with the patient in right lateral position with a 25 gauge spinal needle in L3-L4 space with hyperbaric inj Bupivacaine 0.5% 2 cc(10mg) and dermatomal block till T12 was achieved.

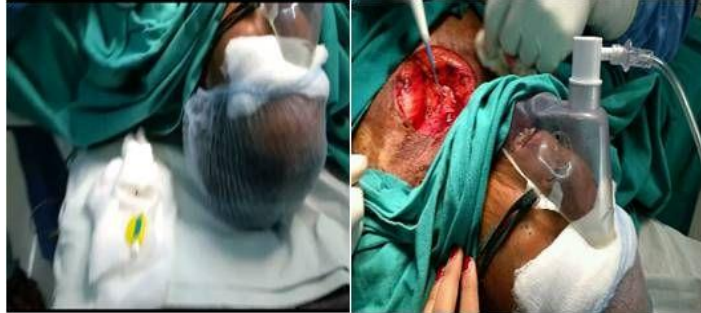

Fig. 2: Intraoperative Period

Oxygen was supplemented through Hudson's face mask @ 4 lit/min. Surgery lasted for around an hour so no epidural top-ups were required intra-operatively. Hydration was maintained with 2 pints of Ringer lactate solution. Vitals were stable and patient was fully conscious.

Post-operatively in the recovery room, monitoring was continued and multimodal analgesia was maintained with epidural doses 0.125% 6cc with 30 mcg injection Norphine 6 hourly and Paracetamol infusion. Epidural catheter was removed after 72 hours.

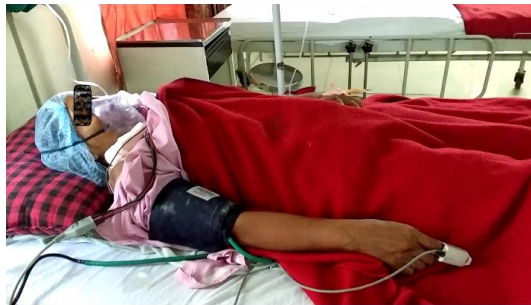

Fig. 3: Postoperative Period

Discussion

Our surgery involved two procedures – Excision of the Marjolin's ulcer from the anterior chest wall and harvest of skin graft from thigh.

Anaesthetic management in a patient with mento-sternal post burn contracture poses a great challenge to anaesthesiologists since it limits atlanto-occipital joint extension and hence inevitably leads to difficult airway making tracheal intubation and sometimes mask ventilation difficult. Hence anesthesia protocol needs to be prepared for the case well in advance.

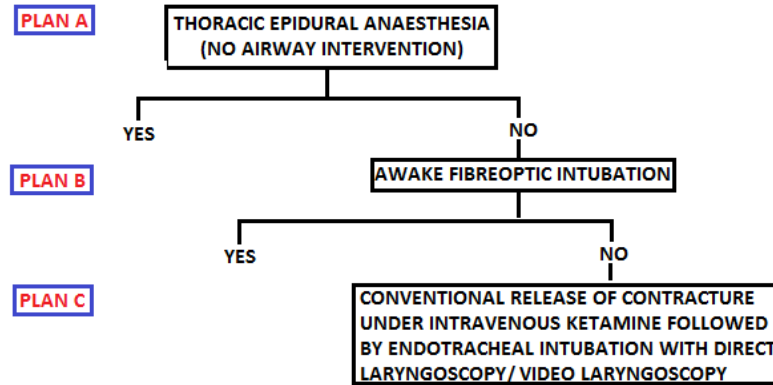


Fig. 4: Anaesthesia case protocol prepared

Thoracic epidural anaesthesia was our logical first choice as no airway intervention would be required.

With difficult airway in background, difficult airway cart was ready with fibreoptic bronchoscope. Awake fibreoptic intubation was our second alternative for airway management.

We kept conventional surgical contracture release before intubation under IV Ketamine anaesthesia as our last resort.^{3,4} Surgeon was ready for emergency tracheostomy, if necessary.

Thoracic epidural anaesthesia is a technically demanding procedure. In experienced hands ensuring proper placement of catheter and dose titration, it is safe and its advantages surpass those of general anaesthesia.

A comparative study between thoracic epidural block and general anaesthesia for oncologic mastectomy concluded about the advantages of thoracic epidural anaesthesia which is associated with better quality of postoperative analgesia, lower incidence of post operative pain, shorter recovery time and hence early hospital discharge.⁵

Another study reflects that the disadvantages of general anaesthesia include inadequate pain control due to lack of residual analgesia, and a high incidence of nausea and vomiting.⁶ Regional block confers lower incidence of nausea and vomiting as demonstrated in various studies presented in a review.⁷

Intra-operatively our patient was comfortable and could be managed without any sedation. Sedation in such patients can lead to airway obstruction and securing airway can be a nightmare for anaesthesiologist.⁸

For harvest of skin graft, we chose unilateral subarachnoid block, as it would result in minimal hemodynamic perturbations⁹ providing intense intra-operative analgesia of fast onset.¹⁰

Post operative analgesia was maintained by multimodal therapy which included epidural analgesia for thoracic incisional pain and inj. Paracetamol infusion that covered the graft harvest pain.¹¹

Conclusion

In the background of pre-formulated strategy in view of anticipated difficult airway, regional anaesthesia is a safe alternative to general anaesthesia in expert hands.

References

1. Jasper AO Anaesthetic management of post burn contractures, a recurrent challenge from oil pipeline vandalization in nigeris: A case report. *Cases J* 2009;2:9141 .
2. Guidelines for difficult airway <http://www.ijaweb.org/article.asp?issn=0019-5049;year=2016;volume=60;issue=12;spage=885;epage=898;aulast=Myatra>
3. A Practice of anaesthesia – Wylie and Churchill – Davidson 7th edition, page 1129
4. Pawan A. Safe method for release of severe post burn neck contracture under tumescent local anaesthesia and ketamine. *Indian J Plast Surg* 2004;37:51-4.
5. Comparative study between thoracic epidural block and general anaesthesia for oncologic mastectomy. <https://www.ncbi.nlm.nih.gov/pubmed/19082403>
6. Oddby-Muhrbeck E, Jakobsson J, Andersson L et al. - Postoperative nausea and vomiting. A comparison between intravenous and inhalation anaesthesia in breast surgery. *Acta Anaesthesiol Scand*, 1994;38:52-56.
7. Borgeat A, Ekatodramis G, Schenker C. – Postoperative nausea and vomiting in regional anaesthesia: a review. *Anesthesiology*, 2003;98:530-547.
8. Airway Characteristics and Safe Management of Spontaneously Breathing Patients: Risks of Sedation and Analgesia and Changes in Wakefulness, http://file.scirp.org/pdf/IJCM_2016110116333525.pdf
9. Comparison of the effects and complications of unilateral spinal anaesthesia versus standard spinal anaesthesia in lower-limb orthopedic surgery , *Brazilian journal of anesthesiology* : volume 64, issue 3, May-June 2013, Page 173-176;<http://www.sciencedirect.com/science/article/pii/S010400141300153X>
10. Miller's Anaesthesia ; Chapter 56;Page –1684
11. Multimodal analgesia for controlling acute postoperative pain. <https://www.ncbi.nlm.nih.gov/pubmed/19606021>