

Variant Anatomy of the Cystic Artery: Case Reports

SM Nayeemuddin¹, Yogesh Yadav^{2*}, Preeti Goswami³

Department of Anatomy, Rama Medical College, Hapur, UP

¹*smnayeemuddin1@gmail.com*

²*dryogeshyadav@gmail.com*

³*drpreetigoswami@gmail.com*

Abstract : Calot's triangle (hepato- biliary triangle) as an orientation structure, determines the most common location of the cystic artery. The cystic artery varies in origin, course and number and it is important to recognize it during operative procedure Cystic artery is usually a branch of right hepatic artery given in the Calot's triangle. Variations in the origin of cystic artery have been reported but there is paucity of literature regarding these in Indian subjects. The development of biliary vasculature is quite complex and it accounts for many variations. Knowledge of cystic artery variability facilitates intraoperative identification of vessels in both classical and laparoscopic surgery of the bile ducts. This emphasizes the importance of a thorough knowledge of the cystic arterial variations that often occur and may be encountered during both laparoscopic and open cholecystectomy. Uncontrolled bleeding from the cystic artery and its branches is a serious problem that may increase the risk of intraoperative lesions to vital vascular and biliary structures during hepatobiliary surgery.

Keywords: Cystic artery, Hepatic artery proper, Calot's triangle, Anatomical variation

1. Introduction

Calot's triangle is defined as a triangle comprising of cystic duct, right hepatic duct and lower edge of liver. Cystic artery normally arises from right hepatic artery within Calot's triangle and passes posterior to the common hepatic duct. Anatomical variations of the cystic artery are very commonly encountered during cholecystectomy. Very often surgeons face problems in laparoscopic cholecystectomy when cystic artery arises outside the Calot's triangle (to the left) and crosses anterior to common hepatic duct [1, 2]. The other origins include the left hepatic artery, the proper hepatic artery, the common hepatic artery, the gastro duodenal artery, the superior pancreaticoduodenal artery and the superior mesenteric artery [3, 4]. In addition to the variability in origin of the cystic artery, its course can also follow diverse paths, often in close proximity to the common bile duct [4]. Uncontrolled arterial bleeding during laparoscopic cholecystectomy is a serious problem and may eventually result in open cholecystectomy [5,6], hence, the origin and the course of the cystic artery is important. Haemorrhage and bile leakage usually occur due to variants of structures of Calot's triangle commonly caused by poor identification of the anatomical structures in the operation field. The reported incidence of conversion to open surgery because of blood vessel injuries is approximately 0%-1.9% during laparoscopic cholecystectomy [7], and its mortality is about 0.02% [8]. That is why every surgeon should be familiar with the anatomical conditions in the Calot's triangle.

2. Case Report

2.1 CASE-1(FIGURE-1)

During routine cadaveric dissection for medical undergraduates, a variation in the origin of cystic artery was observed in a 50 year old female cadaver. The cystic artery originated from the left hepatic artery which was carefully dissected and delineated from the surrounding viscera and photographed.

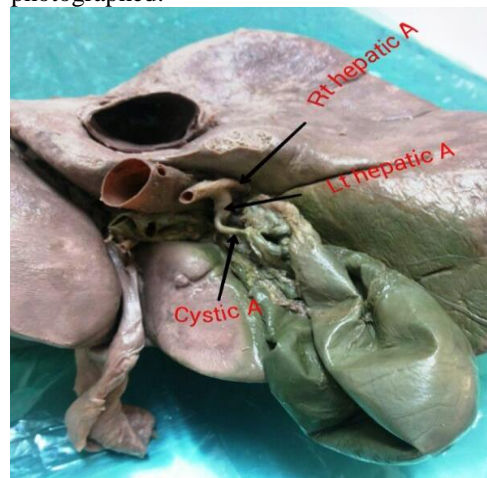


Figure-1: Cystic artery arising from left hepatic artery

2.2 CASE -2: (FIGURE-2)

During routine dissection for medical undergraduate teaching, a variation in the origin of cystic artery was observed in a 55 year old male cadaver. Common hepatic artery took origin from celiac trunk and divided into right and left hepatic arteries.

Right hepatic artery after giving branch to right lobe of the liver continues as right cystic artery which supplying anterior surface of gall bladder. Left hepatic artery after giving branches to left lobe continue as left cystic artery which supplying posterior surface of gall bladder.

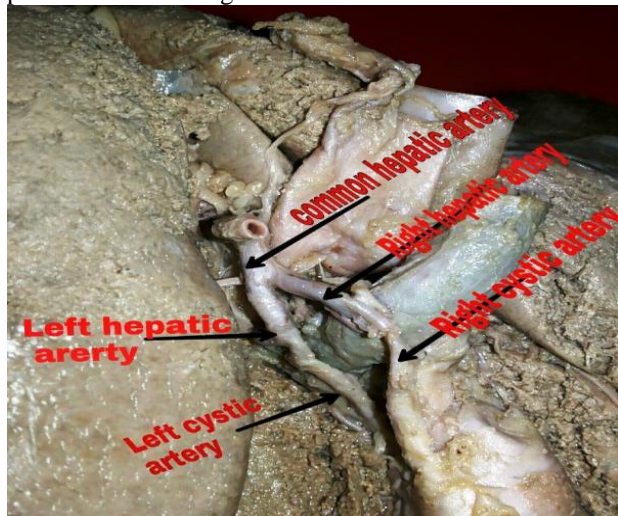


Figure-2: Right and Left cystic artery arising from Right and Left hepatic artery respectively.

3. Discussion

The cystic artery originates from the following sources: right hepatic (63.9%), hepatic trunk (26.9%), left hepatic (5.5%), gastroduodenal (2.6%), superior pancreaticoduodenal (0.3%), right gastric (0.1%), celiac trunk (0.3%) and superior mesenteric artery (0.8%) [9]. Harris & Pellegrini (1994) noted a little difference in origin, where the right hepatic artery was the main source (75%) [3]. The other sources were the left hepatic artery (6.2%), hepatic artery proper (2.2%), common hepatic artery (0.6%), superior pancreaticoduodenal artery (0.2%) and the superior mesenteric artery. Double cystic artery in Calot's triangle existed in 5.55%, this type of variation has been reported in 15-25% of many published series [10, 11].

Cystic artery originating from gastroduodenal artery is also called low-lying cystic artery, which does not pass through Calot's triangle but approaches the gallbladder beyond it. In conventional open cholecystectomy it is seen as inferior to the cystic duct, while it usually localizes superficially and anterior to the cystic duct from a laparoscopic viewpoint. Its terminal segment as it approaches the gallbladder is important for laparoscopic surgeons. Because it not only must be manipulated at first, but it is also susceptible to injury and hemorrhage during dissection of the peritoneal folds that connect the hepatoduodenal ligament to Hartman's pouch of the gallbladder or to the cystic duct [12]

The explanation for the variations in the cystic artery is found in the developmental pattern of the biliary system. Embryologically, the simple branching pattern of the gastroduodenal and hepatobiliary vasculature is profoundly altered by the growth of the liver and pancreas and by the assumption of a curved form in the stomach and duodenum.

These factors operate to complicate the branching of the celiac axis and proximal segment of the superior mesenteric artery. Considering that the liver is derived from a portion of the primitive duct supplied primordially by the celiac and mesenteric arteries, it may receive rami from both of these sources. The same is true from the gallbladder. The liver and gallbladder develop from a foregut endodermal hepatic diverticulum, which usually carries a rich supply of vessels from the abdominal aorta and its initial branches. Most of the vessels picked up from the abdominal aorta during development degenerate leaving in place the mature vascular system. Because the pattern of degeneration is highly variable, the origin and branching pattern of the vessels to these organs also vary considerably (Hiatt et al., 1994)[13]. Considering the complexity of this developmental scheme it is easy to understand the large degree of arterial variation within this vascular system as described by Daseler et al.[14]. Knowledge of the different anatomical variations of the arterial supply of the gallbladder, liver and stomach is of great importance in hepatobiliary and gastric surgical procedures.[15,16].

Laparoscopic cholecystectomy has been accepted as the preferred method of treatment of gall bladder stones. During laparoscopic cholecystectomy dissection of a limited field is magnified on the video monitor which indicates that a detailed anatomical knowledge of the possible variations in the anatomy of the cystic artery and its branches is very important to the surgeon [17]. The importance of a thorough knowledge of arterial supply of extrahepatic biliary ductal system and its variations lies in the fact that it may help in reducing the uncontrolled bleeding that may increase the risk of intraoperative lesion to vital vascular and biliary structures. Hemorrhage and bile leakage usually occurs due to variants of structures of Calot's triangle and they constitute the most common cause of conversion of laparoscopic cholecystectomy to open cholecystectomy. Accidents involving vessels or the common bile duct during laparoscopic cholecystectomy, with or without choledochotomy, can be avoided by careful dissection of Calot's triangle and the hepatoduodenal ligament. Our findings should help the surgeons to reduce the incidence of accidents during laparoscopic cholecystectomy.

4. References

1. Bakheit MA. Prevalence of variations of the cystic artery in the Sudanese. *East Mediterr Health J* 2009;15:1308-12
2. Torres K, Chrosicki A, Golonka A, Torres A, Staskiewicz G, Palczak R, et al. The course of the cystic artery during laparoscopic cholecystectomy. *Folia Morphol (Warsz)* 2009;68:140-3
3. Harris HW, Pellegrini CA. In "Surgical disease of the biliary track and pancreas - multidisciplinary management yearbook. Mosby, St. Louis, 1994;pp 130-132
4. Price P & Holden C. Anatomic variance in the cholecystic blood supply: A case report. *Am surg*, 1993; 59(5):278-80
5. Eobbs MS, Mai Q, Knuiman MW, Fletcher DR, Ridout SC. Surgeon experience and trends in intraoperative complications in laparoscopic cholecystectomy. *Br J Surg*, 2006; 93: 844-853.

6. Suzuki M, Akaishi S, Rikiyama T, Naitoh T, Rahman MM, Matsuno S. Laparoscopic cholecystectomy, Calot's triangle, and variations in cystic arterial supply. *Surg Endosc*, 2000; 14: 141-144.
7. Thompson JE Jr, Bock R, Lowe DK, Moody WE 3rd. Vena cava injuries during laparoscopic cholecystectomy. *Surg Laparosc Endosc* 1996; 6: 221- 223.
8. Deziel DJ, Millikan KW, Economou SG, Doolas A, Ko ST, Airan MC. Complications of laparoscopic cholecystectomy: a national survey of 4,292 hospitals and an analysis of 77,604 cases. *Am J Surg* 1993; 165: 9-14.
9. Anson BH (1963). The aortic arch and its branches. In *Cardiology vol. I* (ed. Luisada A), New York: McGraw-Hill pp. 119.
10. Balijs M, Huis M, Stulhofer M, Nikolic V. Contribution to the nomenclature of variations of the cystic artery. *Chirurg* 2001; 72: 154-158
11. Hugh TB, Kelly MD, Libby B. Laparoscopic anatomy of the cystic artery. *Am J Surg* 1992; 163: 593-595
12. Ding YM, Wang B, Wang WX, Wang P, Yan JS. New classification of the anatomic variations of cystic artery during laparoscopic cholecystectomy. *World J Gastroenterol* 2007;13:5629-34
13. Hiatt JR, Gabbay J, Busuttil RW. Surgical anatomy of the hepatic arteries in 1000 cases. *Ann Surg* 1994; 220:50-2
14. Daseler EH et al. The cystic artery and constituents of the hepatic pedicle. A study of 580 specimens. *Surgery, Gynecology & obstetrics*, 1947, 85:47-63.
15. Loukas M, Ferguson A, Louis RG Jr, Colborn GL. Multiple variations of the hepatobiliary vasculature including double cystic arteries, accessory left hepatic artery and hepatosplenic trunk: a case report. *Surg Radiol Anat* 2006; 28:525-8.
16. Saidi H, Karanja TM, Ogengo JA. Variant anatomy of the cystic artery in adult Kenyans. *Clin Anat* 2007;20:943-5
17. Vishnumaya G, Potu BK, Gorantla VR, Thejodhar P. Anomalous Origin of Cystic Artery from Gastroduodenal artery- A Case Report. *Int J Morphol* 2008;26:75-6

Author's profile



Dr. Yogesh Yadav*-received MBBS, MD (Anatomy) degree from MAMC Delhi and LHMC Delhi respectively. Now working as Associate Professor in Rama Medical College, Hospital & Research Center, NH-24 Hapur, UP.