



Contents lists available at [ScienceDirect](http://www.sciencedirect.com)

## Asian Pacific Journal of Tropical Biomedicine

journal homepage: [www.elsevier.com/locate/apjtb](http://www.elsevier.com/locate/apjtb)



Document heading doi: 10.1016/S2221-1691(15)30171-4 ©2015 by the Asian Pacific Journal of Tropical Biomedicine. All rights reserved.

### Endogenous endophthalmitis and liver abscess syndrome secondary due to *Klebsiella pneumoniae*: report of three cases from Qatar

Ahmed AR Mohamad Al Ani<sup>1\*</sup>, Abdel-Naser Elzouki<sup>1</sup>, Ali Rahil<sup>1</sup>, Fouad Al-Ani<sup>2</sup>

<sup>1</sup>Departments of Medicine, Hamad General Hospital, Hamad Medical Corporation, Weil Cornell Medical College, Doha, Qatar

<sup>2</sup>Accident and Emergency, Hamad General Hospital, Hamad Medical Corporation, Weil Cornell Medical College, Doha, Qatar

#### PEER REVIEW

##### Peer reviewer

Dr. Hirokazu Kimura, Professor/Head, Infectious Disease Surveillance Center, National Institute of Infectious Diseases; School of Medicine, Yokohama City University,  
Tel: +81-42-848-7133  
Fax: +81-42-565-3315  
E-mail: kimhiro@nih.go.jp

##### Comments

Some clinical findings of the study may contribute to diagnosis of endogenous endophthalmitis and liver abscess syndrome due to *K. pneumoniae*.  
Details on Page 58

#### ABSTRACT

Endogenous endophthalmitis is a rare but devastating disease that may frequently result in visual loss despite appropriate and early antibiotic treatment. Recent reports have suggested an increased incidence of endogenous endophthalmitis in East Asia, particularly in Taiwan, where the major source of infection has been liver abscess secondary to *Klebsiella pneumoniae*. Here we report three cases who presented in Qatar with severe endogenous endophthalmitis associated with *Klebsiella pneumoniae* septicemia secondary to pyogenic liver abscess in a diabetes mellitus underlying.

#### KEYWORDS

Endogenous endophthalmitis, *Klebsiella pneumoniae*, Liver abscess

## 1. Introduction

*Klebsiella pneumoniae* (*K. pneumoniae*) is an important cause of community and nosocomial-acquired infection worldwide[1]. It most frequently causes infection in hospitalized patients and occurs primarily in those with impaired host defenses, including patients with diabetes mellitus, alcoholism, malignant neoplasm, and immunosuppressive therapy[2]. It is, however, an uncommon cause for community-acquired infections in individuals without any underlying predisposing medical conditions[3].

Endophthalmitis is a severe inflammation of the internal coats of the eye. It can be caused exogenously by introduction of contaminating microorganisms via penetrating trauma or surgery, or endogenously via hematogenous spread from infected distant

sites. Patients with impaired host defense mechanisms, including those with diabetes mellitus, are more prone to this complication[4]. Different etiologic microorganisms including bacteria and fungi have been found to cause endophthalmitis. In patients with diabetes mellitus, *K. pneumoniae* is the most prevalent microorganism[5]. Endogenous endophthalmitis is a rare but devastating disease that may frequently result in visual loss despite appropriate and early antibiotic treatment.

Recent reports suggest that the incidence is increasing in East Asia, particularly in Taiwan, where the major source of infection has been liver abscess secondary to *K. pneumoniae*[5-7]. In recent years, cases have been reported from Europe and USA indicating global dissemination of these strains affecting both Asian and non-Asian patients[5,8-11].

\*Corresponding author: Ahmed AR Mohamad Al Ani, MBChB, FRCP (Glasg), Sr. Consultant of medicine, Department of Medicine, Hamad Medical Corporation, P. O. Box 3050, Doha, Qatar.  
Tel: +974 44392489  
E-mail: ahmda@yahoo.com  
amohamadi@hmc.org.qa

Article history:  
Received 25 Apr 2014  
Received in revised form 10 Jul, 2nd revised form 14 Jul 2014  
Accepted 8 Sep 2014  
Available online 31 Oct 2014

Here we report three cases who presented in Qatar with severe endogenous endophthalmitis due to *K. pneumoniae* septicemia secondary to pyogenic liver abscess in a diabetes mellitus underlying.

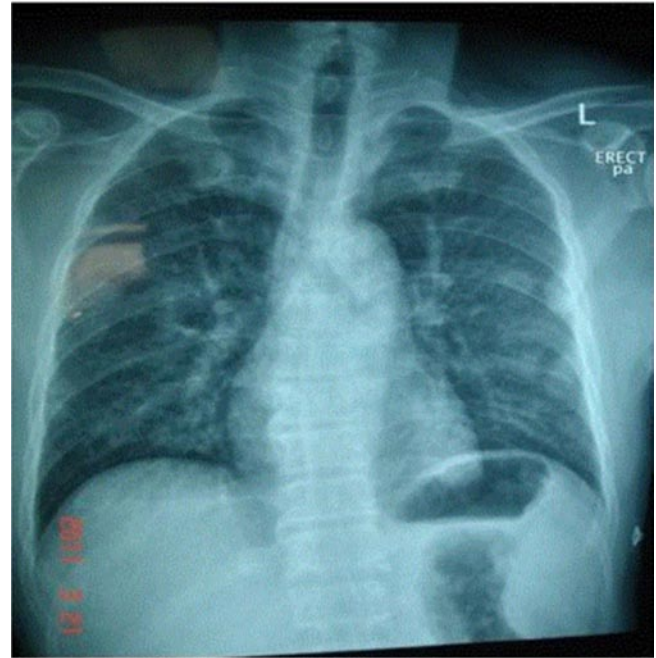
## 2. Case reports

### 2.1. Case 1

A 47-year old Philipino male who was previously presented with one month history of productive cough with yellowish and occasionally blood stained sputum associated with fever, headache, left sided pleuritic chest pain, and right eye pain and redness with decrease vision over the last two weeks. He also admitted having lower abdominal pain with dysuria, nausea and vomiting. He had no history of recent travel abroad. There was no relevant family or occupational history. On examination, he was febrile (39.3 °C), blood pressure was 107/65 mmHg, and pulse was in sinus rhythm with a rate of 110 beats per minute. His oxygen saturation was 95% on room air. General examination was unremarkable apart from right eye congestion with pus in the anterior chamber and loss of vision; findings were consistent with symptom of endophthalmitis. However, the left eye was normal. Chest examination revealed left basal coarse crackles. Abdominal examination revealed tender palpable liver 16 cm below costal margin.

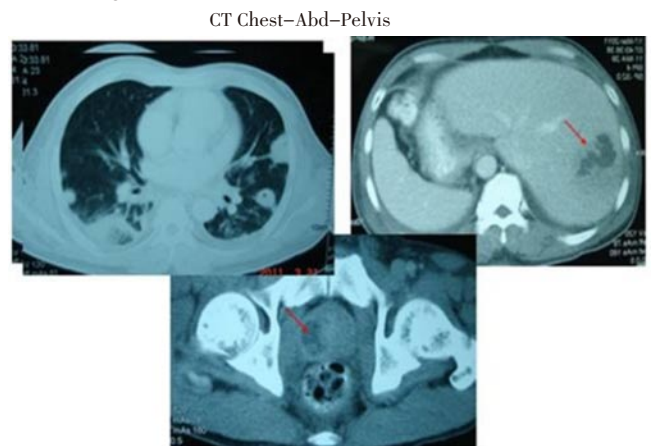
Laboratory investigations revealed white cell count  $22.3 \times 10^3$  cells/mm<sup>3</sup> (normal range:  $4-10 \times 10^3$  cells/mm<sup>3</sup>), hemoglobin 14.3 g/dL (normal range: 13-17 g/dL), platelets  $79 \times 10^3$  per cubic millimeter (normal range:  $150-400 \times 10^3$  per cubic millimeter), erythrocyte sedimentation rate 90 mm/h, random blood glucose concentration 23.4 mmol/L (normal range: 3.3-5.5 mmol/L), glycosylated hemoglobin (HbA<sub>1c</sub>) 11.5%, negative ketone bodies in the blood, serum sodium (Na) 125 mmol/L (normal range: 135-145 mmol/L), serum chlorine (Cl) 94 mmol/L (normal range: 96-110 mmol/L), serum potassium (K) 3.9 mmol/L (normal range: 3.6-5.1 mmol/L), corrected serum calcium (Ca) 3.06 mmol/L (normal range: 2.1-2.6 mmol/L), blood urea 8.7 mmol/L (normal range: 1.7-8.3 mmol/L), creatinine 87 μmol/L (normal range: 62-124 μmol/L), total serum protein 55 g/L, albumin 29 g/L (normal range: 35-50 g/L), total bilirubin 51 μmol/L (normal range: 3.5-24 μmol/L), alkaline phosphatase (ALP) 226 IU/L (normal range: 40-129 IU/L), alanine aminotransferase (ALT) 34 IU/L (normal range: <40 IU/L), aspartate transaminase (AST) 18 IU/L (normal range: <40 IU/L), C-reactive protein 328 mg/L (normal range: <5 mg/L), parathyroid hormone 89 pg/mL (normal range: 15-65 pg/mL), and normal serum cortisol level (614 nmol/L) as well as lipid and coagulation profiles. Blood film revealed marked neutrophilic leukocytosis with toxic neutrophils and few reactive lymphocytes. Chest X-ray showed multiple bilateral cavitory lesions in the right upper and middle lung zones and left middle and lower lung zones (Figure 1). Blood cultures showed Gram-negative bacilli (*K. pneumoniae*). Sputum examinations for acid-fast bacillus were negative. Urine microscopy was remarkable only for white blood count 370 leukocytes/μL and the urine culture reported on growth in

48 h. Serology for HIV and viral hepatitis B and C were negative.



**Figure 1.** Chest X-ray showed multiple bilateral nodular lesions in the right upper and middle lung zones and left middle and lower lung zones.

Abdominal ultrasound showed an ill-defined echogenic mass sized 5 cm×4.6 cm in the right liver lobe and another one of 2.7 cm ×2.5 cm caudal to the first lesion. CT scan for chest and abdomen showed bilateral pleural effusion with multiple opacities in lungs and findings consistent with symptom of liver abscess and small prostate abscess (Figure 2).



**Figure 2.** CT scan for chest and abdomen showed bilateral pleural effusion with multiple opacities in lungs, enlarged mediastinal lymph node as well as findings consistent with liver abscess and small prostate abscess.

The patient was stabilized with ertapenem intravenously for 16 d, the right eye vision was lost. Hypercalcemia was resolved and serum calcium returned back to normal level. Nuclear scan of the neck revealed small ectopic area of abnormal uptake in the right upper mediastinum, and the patient was reluctant to accept surgical intervention.

### 2.2. Case 2

A 48-year old Philipino male with a history of diabetes mellitus

and used metformin since 1996 presented to the emergency department with localized left eye pain and progressive loss of vision, and there was no discharge. This was preceded by a one week history of nausea, vomiting and high grade fever, which came on and off and associated with night chills. Patient then noticed that his urine became dark in color with bilateral painful leg swelling. Vital signs examination revealed temperature 39.4 °C, blood pressure 140/60 mmHg, pulse was in sinus rhythm with a rate of 120 beats per minute and oxygen saturation 100% on room air. Eyes examination showed normal right eye but congested left eye with tender sclera, surrounded by erythema and associated with marked reduction of the vision. Apart from bilateral tender leg swelling and bilateral decreased air entry in both lungs by auscultation, the rest of general and systemic examinations were unremarkable. The patient was referred urgently to the ophthalmologist.

B-scan ocular ultrasound (B-scan ultrasonography, or Brightness scan, offers two-dimensional cross-sectional view of the eye) of the left eye showed superior choroidal swelling, hyperechoic responses in the vitreous humour, and a flat retina; the right eye was grossly normal with moderate non-proliferative diabetic retinopathy and he was diagnosed as left eye endophthalmitis. Initial blood tests showed a white blood count  $17.2 \times 10^3$  cells/mm<sup>3</sup> (normal range:  $4-10 \times 10^3$  cells/mm<sup>3</sup>), hemoglobin 14.63 g/dL (normal range: 13-17 g/dL), platelets  $42.5 \times 10^3$  per cubic millimeter (normal range:  $150-400 \times 10^3$  per cubic millimeter), D-dimer 424 mg/L (normal up to 0.55 mg/L), a random blood glucose concentration of 17.2 mmol/L (normal range: 3.3-5.5 mmol/L), positive serum ketone bodies, serum Na 128 mmol/L (normal range: 135-145 mmol/L), serum Cl 87 mmol/L (normal range: 96-110 mmol/L), serum K 4.3 mmol/L (normal range: 3.6-5.1 mmol/L), serum bicarbonate 18 mmol/L (normal range: 21-28 mmol/L), creatinine 87 µmol/L (normal range: 62-124 µmol/L), total serum protein 48 g/L, albumin 21 g/L (normal range: 35-50 g/L), total bilirubin 101 µmol/L (normal range: 3.5-24 µmol/L), serum ALP 176 IU/L (normal range: 40-129 IU/L), serum ALT 121 IU/L (normal range: 0-40 IU/L), serum AST 50 IU/L (normal range: 0-40 IU/L), HbA<sub>1c</sub> 10.7%, serum amylase 105 IU/L (normal range: 13-53 IU/L). Blood cultures, from both aerobic and anaerobic bottles, showed Gram-negative bacilli (*K. pneumoniae*). Liver aspirate culture was also positive for *K. pneumoniae*. Serology for HIV and viral hepatitis B and C were negative.

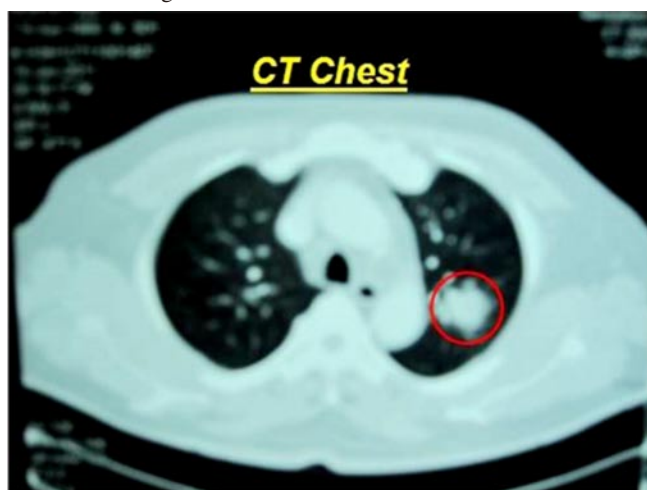


Figure 3. CT scan of chest showed small patchy opacity of left zone.

Chest CT revealed bilateral prominent interstitial markings with small patchy opacity of left zone (Figure 3).

Abdominal ultrasound examination showed a well defined loculated right lobe liver abscess with the size of 4.3 cm×3.5 cm, which was drained. Echo-cardiography and ultrasound Doppler of both lower limbs were normal. CT scan of abdomen showed liver abscess (Figure 4). MRI examination of both legs showed diffuse cellulites of left leg with no collection (Figure 5). Bone scan didn't show osteomyelitis.

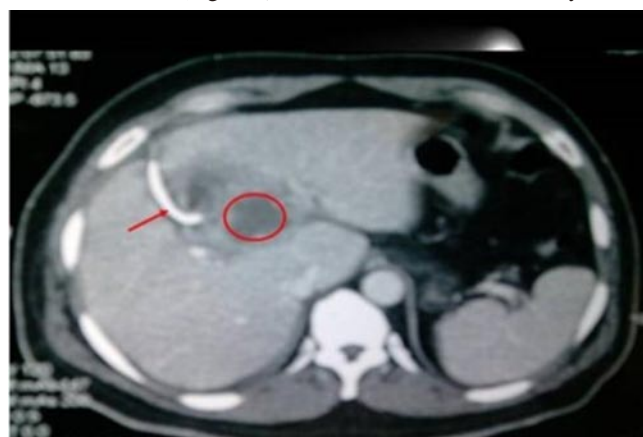

Figure 4. CT scan of abdomen showed liver abscess with drainage tube inside the abscess.

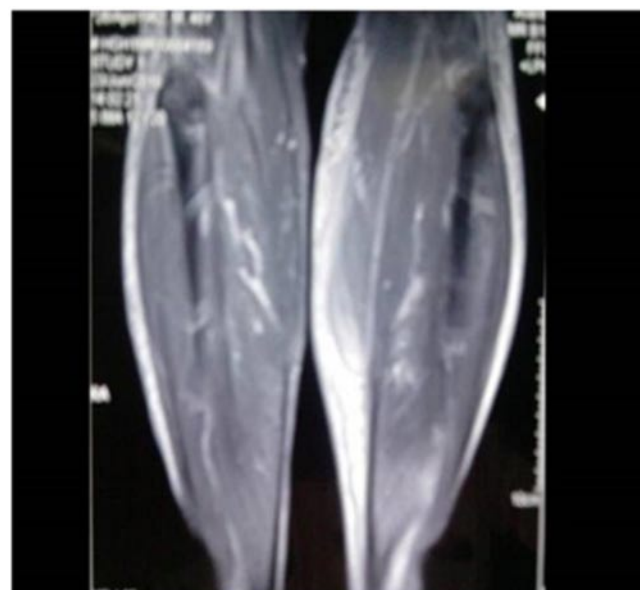

Figure 5. MRI examination of both legs showed diffuse cellulitis of the left leg with inflammatory changes, no intramuscular abscess or collection.

The patient was stabilized and started treatment with ceftriaxon 2 g by intravenous injection once a day. The ophthalmologist prescribed atropine eye drops, injection of vancomycin 1000 mg and ceftazidime 500 mg in left eye and continued vancomycin and ceftazidime eye drops. The patient was scheduled for vitrectomy but he refused. The treatment was continued for two weeks, and the liver abscess was drained, repeated blood cultures were negative and patient became afebrile and he was discharged.

### 2.3. Case 3

A 51-year old Philipino male patient presented to the emergency department with high grade fever and yellow discoloration of the

sclera for two weeks, and this was proceeded by dry cough. The patient is ex-smoker, but not alcohol consumer. On examination, temperature was 38.6 °C, blood pressure was 130/78 mmHg, and pulse was in sinus rhythm with a rate of 110 beats per minute. His oxygen saturation was 98% on room air. He had yellow sclera, and chest auscultation revealed left lower zone crepitations and abdominal examination revealed hepatomegaly (liver span 15 cm). The other systemic examinations were unremarkable.

Initial blood tests showed white cell count  $17.3 \times 10^3$  cells/mm<sup>3</sup> (normal range:  $4-10 \times 10^3$  cells/mm<sup>3</sup>), hemoglobin 11.1 g/dL (normal range: 13-17 g/dL), platelets  $150 \times 10^3$  per cubic millimeter (normal range:  $150-400 \times 10^3$  per cubic millimeter), normal blood urea and serum creatinine, and a random glucose concentration of 14 mmol/L (normal range: 3.3-5.5 mmol/L) with positive serum ketone bodies, serum Na 129 mmol/L (normal range: 135-145), serum Cl 90 mmol/L (normal range: 96-110 mmol/L), serum K 3.7 mmol/L (normal range: 3.6-5.1 mmol/L), bicarbonate 25 mmol/L, total serum protein 68 g/L, albumin 21 g/L (normal range: 35-50 g/L), total bilirubin 122 µmol/L (normal range: 3.5-24 µmol/L), ALP 204 IU/L (normal range: 40-129 IU/L), ALT 81 IU/L (normal range: 0-40 IU/L), AST 50 IU/L (normal range: 0-40 IU/L), HbA<sub>1c</sub> 9.8%. Serology for HIV and viral hepatitis B and C markers as well as anti-amoeba antibody were negative. Blood cultures, from both aerobic and anaerobic bottles, showed Gram-negative bacilli (*K. pneumoniae*).

Abdominal ultrasound examination showed multiple liver abscesses and ultrasound guided drain was inserted. Liver aspirate culture was positive for *K. pneumoniae*. Chest X-ray showed multiple areas of inflammatory process. Echo cardiography was normal.

The patient was empirically given ceftriaxon 2 g by intravenous injection once a day and intravenous injection of metronidazole three times a day (discontinued after blood culture results) for two weeks.

Two days after admission, patient complained of decreased vision in the right eye, and the ophthalmologist prescribed cyclopentolate eye drops and intravitreal antibiotic. Patient improved, became afebrile; his vision returned back to normal and blood sugar was controlled with insulin. He was discharged with treatments of oral antibiotics for total 6 weeks, oral antidiabetics and prednisolone eye drops. Blood culture before discharge was negative.

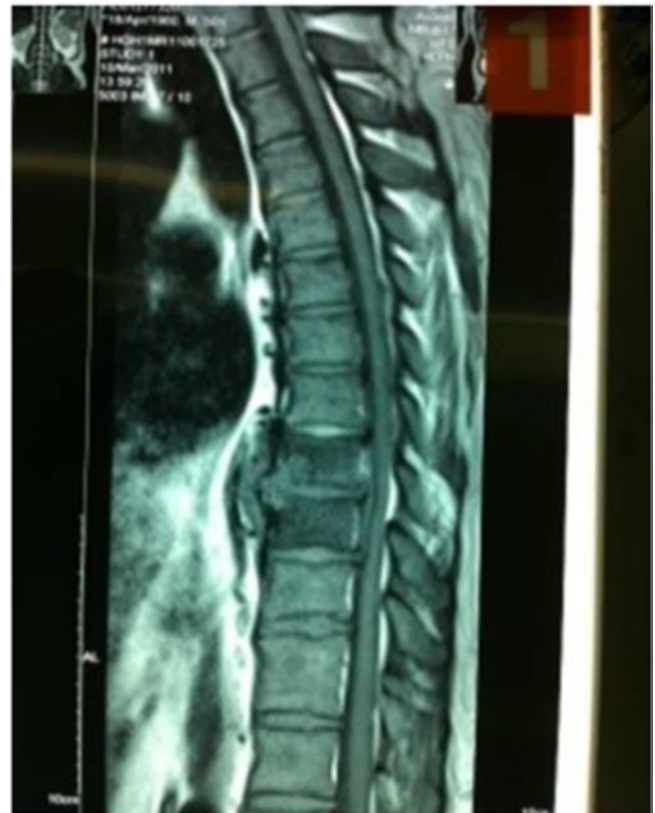In the first follow up two weeks after discharge, CT scan for abdomen was repeated and showed complete resolution of the liver abscess.

Six weeks after discharge, the patient presented with severe low back pain for one week followed by lower abdominal pain and urinary retention one day prior to his presentation. His back pain was not radiating to the lower limbs and not associated with numbness and relieved by lying down. Patient had 20 kg weight loss in the last three months. On examination, the temperature was 36.9 °C, blood pressure was 139/84 mmHg, and pulse was in sinus rhythm with a rate of 72 beats per minute. His oxygen saturation was 99% on room air. There was paraspinal tenderness in the mid thoracic region. Examination of the lower limbs, showed increase tone and decrease power (Grade 3/5) with brisk reflexes and non sustained clonus.

Other systemic examinations were unremarkable.

Blood tests were remarkable for white cell count  $11.5 \times 10^3$  cells/mm<sup>3</sup> (normal range: 4-10 cells/mm<sup>3</sup>), erythrocyte sedimentation rate 74 mm/h, a random blood glucose concentration of 23.4 mmol/L (normal range: 3.3-5.5 mmol/L), HbA<sub>1c</sub> 9.8%, total serum protein 55 g/L, albumin 29 g/L (normal range: 35-50 g/L), serum Na 125 mmol/L (normal range: 135-145 mmol/L), serum Cl 94 mmol/L (normal range: 96-110 mmol/L), serum K 3.9 mmol/L (normal range: 3.6-5.1 mmol/L), total bilirubin 51.4 µmol/L (normal range: 3.5-24 µmol/L), with normal serum transaminase and international normalized ratio.

Urine culture revealed no growth and sputum for acid-fast bacillus (three samples) were negative. Tuberculin test was positive (18 mm). Chest X-ray showed scoliotic deformity at the dorsal spine without obvious lung parenchymal lesions. There was also a paraspinal shadow at the level of D8-D10 but vertebrae looked normal. Abdominal ultrasound showed focal hypoechoic lesion sequelae of inflammatory changes. CT scan of chest revealed multiple cavities and nodular opacities with fibrotic band in the lungs, and an osteolytic lesion at D9 and D10 vertebral bodies with anterior longitudinal ligament calcification. MRI showed spines paraspinal and intraspinal epidural abscess (T9-T10) that cause cord compression (Figure 6).



**Figure 6.** MRI paraspinal and intraspinal shows epidural abscess causing cord compression.

Fine needle aspiration from the paraspinal abscess revealed acute inflammatory process with granulation tissue. Culture was negative for bacterial growth and acid fast bacilli. Polymerase chain reaction of aspirate was also negative for *Mycobacterium tuberculosis*.

Patient was assessed by neurosurgeon and underwent laminectomy. Post laminectomy (D9 and D10) histopathology revealed fragment of

soft tissue, bony fragment and fibro-cartilaginous tissue showing mild acute and chronic inflammation with no granuloma or malignant cells. Patient received intravenous injection of antibiotics (ceftriaxone 2 g once a day with metronidazole 500 mg three times a day for 3 weeks).

Patient was discharged with gradual improvement in the lower limbs weakness (by Foley catheter) and transferred to rehabilitation unit for physiotherapy. Patient was advised to continue intravenous injection of ceftriaxone for another 3 weeks as an outpatient, in addition to metformin (1 g twice daily), deep vein thrombosis prophylaxis (dalteparin 2500 IU subcutaneously), and he was discharged and referred to infectious disease clinic for follow up because his tuberculin test was positive.

### 3. Discussion

Although nosocomial *K. pneumoniae* infections occur worldwide, some types of community-acquired infections have been described in only few geographic areas. It includes pneumonia, urinary tract infection and, primarily in East Asia, particularly in Taiwan, a pyogenic liver abscess syndrome is typically associated with endogenous endophthalmitis[3,5-7].

Most cases of endogenous endophthalmitis are due to fungal infection and Gram positive bacteria in immune compromised patients. Endogenous endophthalmitis due to *K. pneumoniae*, a Gram negative bacterium, is a rare but often devastating septic metastatic infection. It accounts for 2%-8% of all endophthalmitis cases[3]. Diabetes mellitus has been identified as the major risk factor for the development of endogenous endophthalmitis due to *K. pneumoniae* in patients with liver abscesses, and this was present in up to 40% of the cases[5,12-13]. One of our three patients (Case 2) was a known case of diabetes mellitus for 15 years and the other two patients were diagnosed as having diabetes mellitus for the first time during the workup of their presentations. It was reported that in type 2 diabetes mellitus with poor glycemic control, there is impaired phagocytosis of capsular serotype K1 or K2 of *K. pneumoniae*[5,14], and there is high prevalence of phagocytic-resistant capsular serotype in liver abscess[13].

Blood cultures in the three cases were positive for *K. pneumoniae* and sensitive to all antibiotics except ampicillin and this phenomenon was similar to the previously reported cases from USA[15].

Five major virulence factors of *K. pneumoniae* are known to contribute to the pathogenesis of infection. These are the capsular serotype, hypermucoviscosity phenotype, lipopolysaccharide, siderophores, and pili[3,16]. Among all, the capsular serotype (in particular the strain K1) was found significantly associated with pyogenic liver abscess and endogenous endophthalmitis[3,17]. Typically, this strain is capable of producing a mucoviscous exopolysaccharide web when a loop is passed through a colony[17,18]. Hence the gene, encode a 43 kD outer membrane protein, was named mucoviscosity-associated gene (*MagA*) and

was located within an operon that is specific to the serotype K1 capsular polysaccharide gene cluster[19]. The *K. pneumoniae* strain which carries this gene is more resistant to human complement-mediated serum and phagocytosis killing suggesting an enhanced virulence and pathogenicity[20]. The serotype of the isolated *K. pneumoniae* in our patients was not indentified, but the virulent and devastating clinical course of the disease in the three cases may suggest the presence positivity of K1 strain and *MagA* gene. Rapid detection of high virulent strain that causes this syndrome allows earlier diagnosis and treatment.

Occasionally, the ocular infection is the presenting manifestation of sepsis in patients with disseminated *K. pneumoniae* infection[12]. And it was the presenting manifestation in the first and second case. The visual outcome in these two patients was poor in spite of intensive therapy by the ophthalmologist and this is similar to other case reports[20,21]. The outcome of vision in the third case was complete recovery of the affected eye and this is probably because of aggressive and immediate intervention by the ophthalmologist because there was no delay as the patient developed the eye symptoms while in the hospital.

In conclusion, we report three cases who presented in Qatar with severe endogenous endophthalmitis associated with *K. pneumoniae* secondary to pyogenic liver abscess in a diabetes mellitus setting. A high clinical suspicion allows immediate diagnosis and treatment. Early antibiotic therapy remains the cornerstone of treatment. It suggests that this syndrome is becoming a global health problem and is not confined in East Asia. This devastating disease should be suspected in diabetic patients presented with *Klebsiella* liver abscess and vigorous search for intra-ocular infection is needed, as early and appropriate antibiotic treatment could save the visual loss of such patients.

### Conflict of interest statement

We declare that we have no conflict of interest.

### Comments

#### Background

Although endogenous endophthalmitis is rare disease, the disease outcome is serious. Therefore, it is essential to diagnose and treat the disease early.

#### Research frontiers

The present case report makes a detailed description of endogenous endophthalmitis and liver abscess syndrome due to *K. pneumoniae* infection in Qatar.

#### Related reports

There is few reports regarding endogenous endophthalmitis and liver abscess syndrome due to *K. pneumoniae*, except some reports from Taiwan.

### Innovations and breakthroughs

Endogenous endophthalmitis and liver abscess syndrome due to *K. pneumoniae* infection may occur in the patients with other infectious diseases as well as diabetes as an underlying disease.

### Applications

The present report may contribute to diagnose and treatment of the disease.

### Peer review

Some clinical findings of the study may contribute to diagnosis of endogenous endophthalmitis and liver abscess syndrome due to *K. pneumoniae*.

### References

- [1] Lin YT, Liu CJ, Yeh YC, Chen TJ, Fung CP. Ampicillin and amoxicillin use and the risk of *Klebsiella pneumoniae* liver abscess in Taiwan. *J Infect Dis* 2013; **208**(2): 211-217.
- [2] Tsay RW, Siu LK, Fung CP, Chang FY. Characteristics of bacteremia between community-acquired and nosocomial *Klebsiella pneumoniae* infection: risk factor for mortality and the impact of capsular serotypes as a herald for community-acquired infection. *Arch Intern Med* 2002; **162**(9): 1021-1027.
- [3] Sawada A, Komori S, Udo K, Suemori S, Mochizuki K, Yasuda M, et al. Case of endogenous endophthalmitis caused by *Klebsiella pneumoniae* with *magA* and *rmpA* genes in an immunocompetent patient. *J Infect Chemother* 2013; **19**(2): 326-329.
- [4] Al-Amri MS. Endogenous endophthalmitis secondary to pyogenic liver abscess. *Int J Diabetes Mellit* 2010; **2**(1): 64-66.
- [5] Sheu SJ, Kung YH, Wu TT, Chang FP, Horng YH. Risk factors for endogenous endophthalmitis secondary to *Klebsiella pneumoniae* liver abscess: 20-year experience in Southern Taiwan. *Retina* 2011; **31**(10): 2026-2031.
- [6] Fung CP, Hu BS, Chang FY, Lee SC, Kuo BI, Ho M, et al. A 5-year study of the seroepidemiology of *Klebsiella pneumoniae*: high prevalence of capsular serotype K1 in Taiwan and implication for vaccine efficacy. *J Infect Dis* 2000; **181**(6): 2075-2079.
- [7] Yu WL, Ko WC, Cheng KC, Lee HC, Ke DS, Lee CC, et al. Association between *rmpA* and *magA* genes and clinical syndromes caused by *Klebsiella pneumoniae* in Taiwan. *Clin Infect Dis* 2006; **42**(10): 1351-1358.
- [8] Moore R, O'Shea D, Geoghegan T, Mallon PW, Sheehan G. Community-acquired *Klebsiella pneumoniae* liver abscess: an emerging infection in Ireland and Europe. *Infection* 2013; **41**(3): 681-686.
- [9] Sobirk SK, Struve C, Jacobsson SG. Primary *Klebsiella pneumoniae* liver abscess with metastatic spread to lung and eye, a North-European case report of an emerging syndrome. *Open Microbiol J* 2010; **4**: 5-7.
- [10] Sachdev DD, Yin MT, Horowitz JD, Mukkamala SK, Lee SE, Ratner AJ. *Klebsiella pneumoniae* K1 liver abscess and septic endophthalmitis in a U.S. resident. *J Clin Microbiol* 2013; **51**(3): 1049-1051.
- [11] Pope JV, Teich DL, Clardy P, McGillicuddy DC. *Klebsiella pneumoniae* liver abscess: an emerging problem in North America. *J Emerg Med* 2011; **41**(5): e103-e105.
- [12] Ang M, Jap A, Chee SP. Prognostic factors and outcomes in endogenous *Klebsiella pneumoniae* endophthalmitis. *Am J Ophthalmol* 2011; **151**(2): 338-344.
- [13] Al-Mahmood AM, Al-Binali GY, Alkatan H, Abboud EB, Abu El-Asrar AM. Endogenous endophthalmitis associated with liver abscess caused by *Klebsiella pneumoniae*. *Int Ophthalmol* 2011; **31**(2): 145-148.
- [14] McCabe R, Lambert L, Frazee B. Invasive *Klebsiella pneumoniae* infections, California, USA. *Emerg Infect Dis* 2010; **16**(9): 1490-1491.
- [15] Siu LK, Yeh KM, Lin JC, Fung CP, Chang FY. *Klebsiella pneumoniae* liver abscess: a new invasive syndrome. *Lancet Infect Dis* 2012; **12**(11): 881-887.
- [16] Yeh KM, Kurup A, Siu LK, Koh YL, Fung CP, Lin JC, et al. Capsular serotype Ki or K2, rather than *magA* and *rmpA*, is a major virulence determinant for *Klebsiella pneumoniae* liver abscess in Singapore and Taiwan. *J Clin Microbiol* 2007; **45**(2): 466-471.
- [17] Chuang YP, Fang CT, Lai SY, Chang SC, Wang JT. Genetic determinants of capsular serotype K1 of *Klebsiella pneumoniae* causing primary pyogenic liver abscess. *J Infect Dis* 2006; **193**(5): 645-654.
- [18] Yeh KM, Chang FY, Fung CP, Lin JC, Siu LK. *magA* is not a specific virulence gene for *Klebsiella pneumoniae* strains causing liver abscess but is part of the capsular polysaccharide gene cluster of *Klebsiella pneumoniae* serotype K1. *J Med Microbiol* 2006; **55**(Pt 6): 803-804.
- [19] Lee S, Um T, Joe SG, Hwang JU, Kim JG, Yoon YH, et al. Changes in the clinical features and prognostic factors of endogenous endophthalmitis: fifteen years of clinical experience in Korea. *Retina* 2012; **32**(5): 977-984.
- [20] Liu Y, Wang JY, Jing W. An increasing prominent disease of *Klebsiella pneumoniae* liver abscess: etiology, diagnosis, and treatment. *Gastroenterol Res Pract* 2013; doi: 10.1155/2013/258514.
- [21] Sng CC, Jap A, Chan YH, Chee SP. Risk factors for endogenous *Klebsiella* endophthalmitis in patients with *Klebsiella* bacteremia: a case-control study. *Br J Ophthalmol* 2008; **92**(5): 673-677.